

Immediate Implant Placement

Evidence Based Dentistry Rounds

Specialty: Periodontology

Group: 9

Date: 09/23/20

Rounds Team

- **Group Leader: Dr. Derderian**
- **Specialty Leader: Dr. Brunner**
- **Project Team Leader: Joel Ledvina**
- **Project Team Participants:**
 - **D₃: Carly Kirkpatrick**
 - **D₂: Hanna Anderson**
 - **D₁: Anna Langworthy**

Patient

- 29
- Male
- Asian
- “I want my crowns redone”
- Additional pertinent information

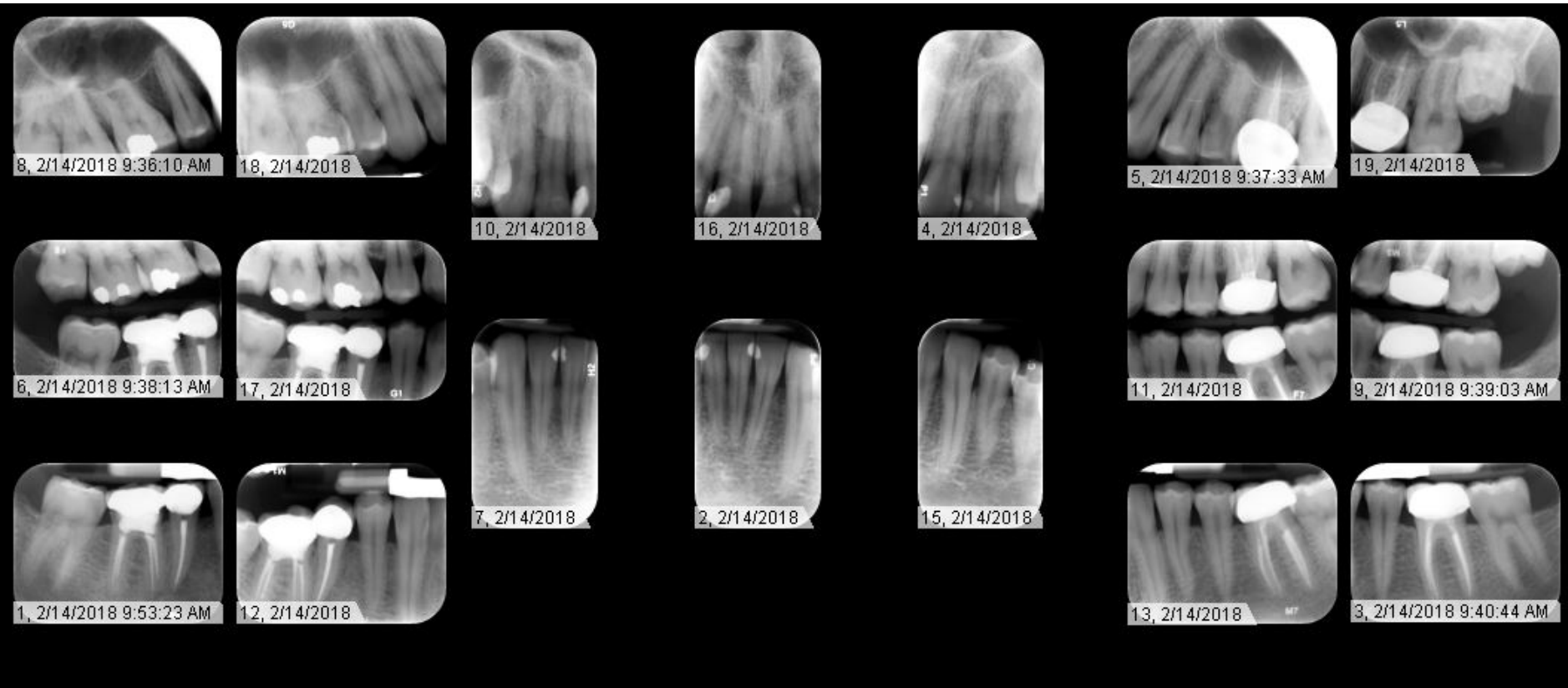
Medical History

- Current & past:
 - Non-contributory medical history for dental care
 - Conditions: None
 - Medications: None
 - Allergies: NKDA

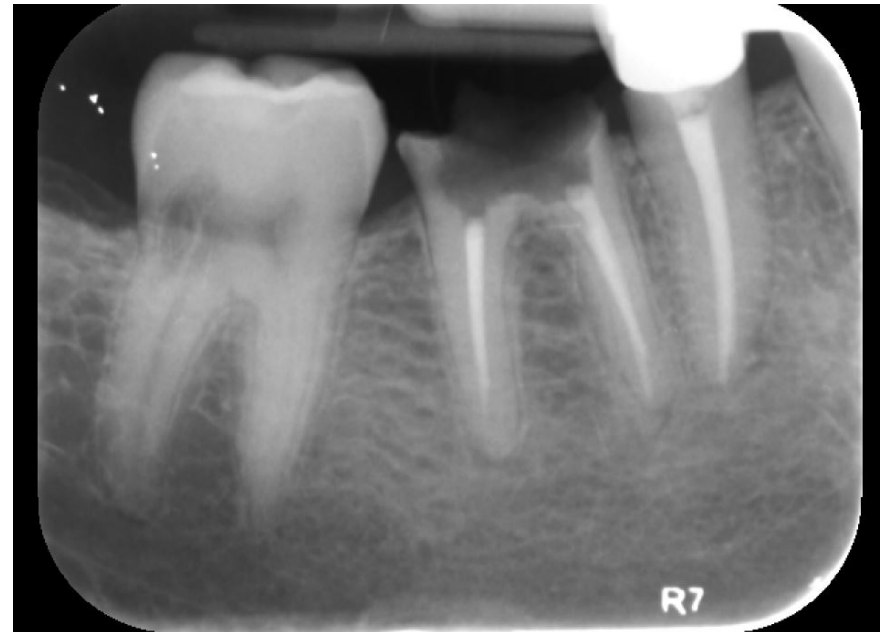
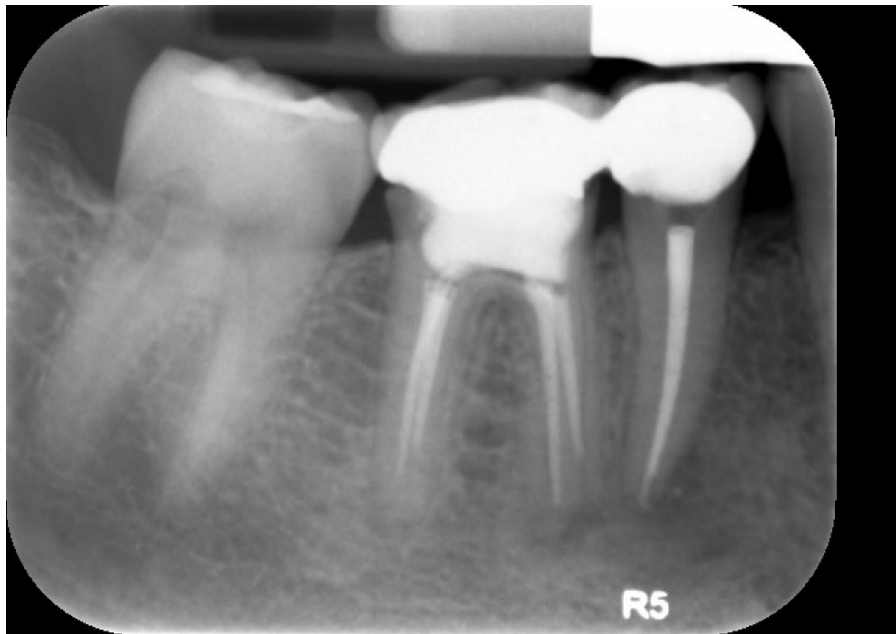
Dental History

- Pre-2017: #14/#19 single crowns restored outside of the country.
- 2017: #29/#30 RCT
- 2018: Anterior Restorative
- 2019:
 - #30 Deemed Hopeless
 - #19 Crown Restoration

Radiographs



Radiographs



Radiographic Findings

- **RCT:** #14, #19, #29, #30
- **Amalgams:** #2 (OL), #3 (O)
- **Resins:** #7 (DL), #8 (DLF), #9 (DL), #10 (MLF), 12 (O)
- **Crowns:** #14, #19, #29

Clinical Findings

- #14: Distal Overhang (Defective Restoration)
- #19: Distal Overhang (Defective Restoration)
- #30: Gross Decay

Specific Findings

- #30: Gross Decay, Hopeless
 - Bone level adequate for implant placement

Periodontal Charting

																	MOBILITY
P P P	P P P	P P P				P P	P P	P P				P P	P P	P P	P P P	P P P	FURCA
5 5 5	6 6 6	5 5 5	4 4 4			4 4 4	6 6 6	4 4 4	5 5 5	5 5 5	5 5 5	6 6 6	6 6 6	6 6 6	7 7 7		PLAQUE
2 1 1	2 2 2	2 2 3	2 2 2			2 1 2	2 1 2	2 2 2	2 1 2	2 1 2	2 1 2	3 2 4	4 2 3	3 1 3	3 2 3		BOP
4 2 3	2 2 2	2 2 3	2 2 2			2 1 2	2 1 2	2 2 2	2 1 2	2 1 2	2 1 2	3 2 4	4 2 3	3 1 3	3 2 3		MGJ
-2-1-2	0 0 0	0 0 0	0 0 0			0 0 0	0 0 0	0 0 0	0 0 0	0 0 0	0 0 0	0 0 0	0 0 0	0 0 0	0 0 0		CAL
1	2	3	4	5	6	7	8	9	10	11	12	13	14	15	16		P.D.
-2-1-2	0 0 0	0 0 0	0 0 0			0 0 0	0 0 0	0 0 0	0 0 0	0 0 0	0 0 0	0 0 0	0 0 0	0 0 0	0 0 0		FGM
4 2 3	3 2 3	3 2 3	4 2 3			3 2 2	2 2 2	2 2 3	3 2 2	2 1 2	2 1 2	2 2 3	3 2 3	3 2 3	3 2 3		P.D.
2 1 1	3 2 3	3 2 3	4 2 3			3 2 2	2 2 2	2 2 3	3 2 2	2 1 2	2 1 2	2 2 3	3 2 3	3 2 3	3 2 3		CAL
																	MGJ
																	BOP
P P P	P P P	P P P				P P		P	P			P P	P P	P P	P P		PLAQUE
																	FURCA
																	PROGNOSI

																	PROGNOSI
																	FURCA
		P P P	P P P	P P P	P P P	P P P	P P P	P P P	P P P	P P P	P P P	P P P	P P P	P P P	P P P	P P P	PLAQUE
		4 4 4	3 3 3	3 3 3	4 4 4	3 3 3	3 3 3	2 2 2	3 3 3	3 3 3	2 2 2	4 4 4	4 4 4	5 5 5	5 5 5		BOP
		3 2 3	2 1 2	3 2 3	2 1 2	2 2 2	3 3 2	3 3 3	3 3 2	1 2 2	1 1 1	2 2 2	2 2 3	3 2 2	3 2 3		MGJ
		3 2 3	2 1 2	3 2 3	2 1 2	2 1 2	2 1 1	2 1 2	2 1 1	1 1 2	1 1 1	2 2 2	2 2 3	3 2 2	3 2 3		CAL
		0 0 0	0 0 0	0 0 0	0 0 0	0 1 0	1 2 1	1 2 1	1 2 1	0 1 0	0 0 0	0 0 0	0 0 0	0 0 0	0 0 0		P.D.
32	31	30N	29	28	27	26	25	24	23	22	21	20	19	18	17		FGM
		0 0 0	0 0 0	0 0 0	0 0 0	0 1 0	0 1 0	1 2 1	0 1 0	0 1 0	0 0 0	0 0 0	0 0 0	0 0 0	0 0 0		P.D.
		3 2 3	2 2 2	3 2 3	3 2 2	1 2 1	1 1 1	1 1 1	1 2 1	3 2 3	3 2 2	2 2 2	3 2 3	3 2 3	3 2 3		CAL
		3 2 3	2 2 2	3 2 3	3 2 2	1 2 1	1 2 1	1 2 1	2 3 2	1 3 1	3 3 3	3 2 2	2 2 2	3 2 3	3 2 3		MGJ
		3 3 3	3 3 3	3 3 3	2 2 2	2 2 2	2 2 2	2 2 2	3 3 3	3 3 3	2 2 2	3 3 3	4 4 4	4 4 4	5 5 5		BOP
		P P P	P P P	P P P	P P P	P P P	P P P	P P P	P P P	P P P	P P P	P P P	P P P	P P P	P P P		PLAQUE
																	FURCA
																	MOBILITY

Diagnosis

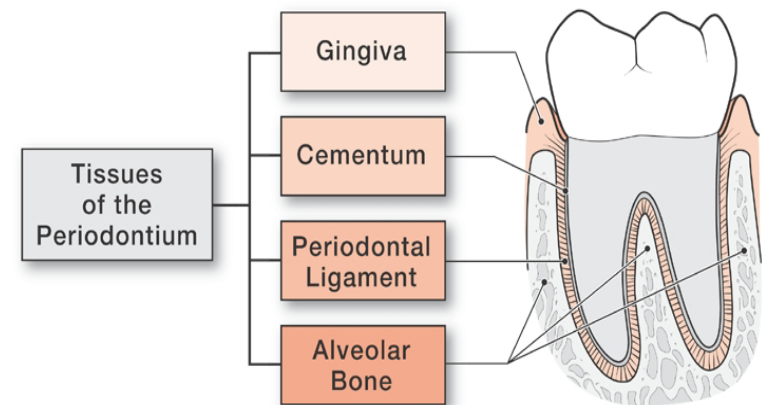
- Gingivitis – Dental Biofilm Induced

Problem List

- Defective Restorations
- Gross Decay
- Non-restorable Tooth

Anatomy of the Periodontium

- Periodontium: The supporting structures of the tooth.
 - Gingiva (dentogingival junction)
 - Gingival, sulcular, and junctional epithelium
 - Connective tissue
 - Alveolar bone
 - Cortical and cancellous bone, alveolus
 - Periodontal ligament
 - Sharpey fibers
 - Cementoblasts, fibroblasts, osteoblasts
 - Root Cementum

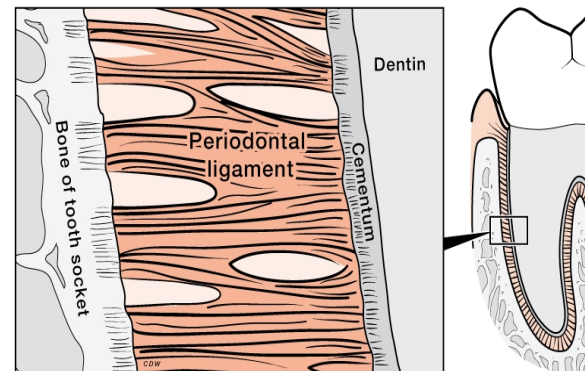
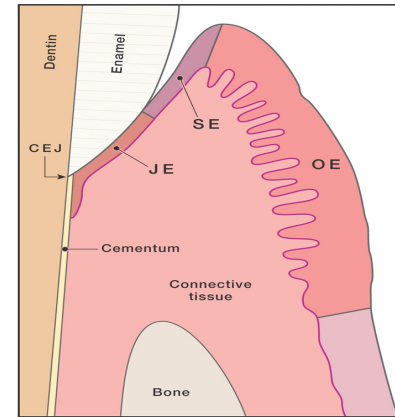


Copyright © 2008 Wolters Kluwer Health | Lippincott Williams & Wilkins

Nanci, Antonio, and Dieter D. Bosshardt. "Structure of Periodontal Tissues in Health and Disease*." *Periodontology 2000*, vol. 40, no. 1, 2006, pp. 11–28., doi:10.1111/j.1600-0757.2005.00141.x.

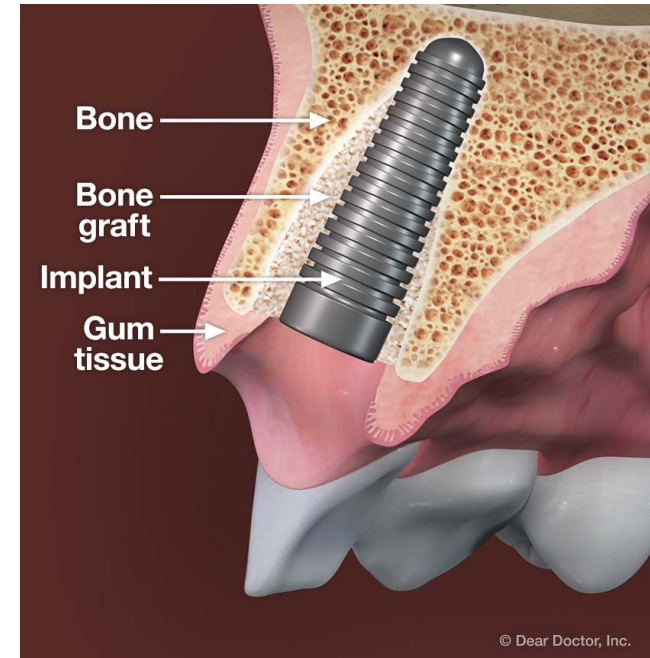
Functions of the Periodontium

- **Gingiva** provides a barrier between the oral environment and the deeper periodontal tissues, and it plays a role in host defense.
- **Alveolar bone** contains sockets to hold teeth and undergoes resorption and bone formation.
- **Periodontal ligament** suspends and maintains tooth in alveolar socket.
- **Cementum** serves as an attachment area for the periodontal ligament fibers. This anchors the tooth.



Pathology Associated with the Placement of Immediate Implants

- Overall, the survival is significantly worse than delayed implants
 - 98.38% vs 95.21%
- Placing the implant into an infected site is only minorly contraindicated
- Periodontal changes are the same between immediate and delayed implants
- Possible systemic contraindications: bisphosphonates, smoking habits, diabetes



Immediate Dental Implant. Retrieved September 16, 2020, from Dear Doctor website: <https://www.deardocor.com/articles/immediate-dental-implants/page2.php>

Gómez-de Diego, R., Mang-de la Rosa, M. del R., Romero-Pérez, M. J., Cutando-Soriano, A., & López-Valverde-Centeno, A. (2014). Indications and <https://doi.org/10.11607/jomi.4149> of dental implants in medically compromised patients: Update. *Medicina Oral, Patología Oral y Cirugía Bucal*, 19(5), e483–e489. <https://doi.org/10.4317/medoral.19565>

Zhao, D., Wu, Y., Xu, C., & Zhang, F. (2015). Immediate dental implant placement into infected vs. Non-infected sockets: A meta-analysis. *Clinical Oral Implants Research*, 27(10). <https://0-doi-org.libus.csd.mu.edu/10.1111/clr.12739>

Mello, C., Lemos, C. Verri, F., Dos Santos, D., Goiato, M., & Pellizzer, E. (2017). Immediate implant placement into fresh extraction sockets versus delayed implants into healed sockets: A systematic review and meta-analysis. *Int J Oral Maxillofac Surg*, 46(9), 1162–1177. <https://doi.org/10.1016/j.ijom.2017.03.016>

Turri, A., Rossetti, P., Canullo, L., Grusovin, M., & Dahlin, C. (2016). Prevalence of peri-implantitis in medically compromised patients and smokers: a systematic review. *The International Journal of Oral & Maxillofacial Implants*, 31(1). <https://doi.org/10.11607/jomi.4149>

D3 PICO

- **Clinical Question:**

- Is an immediately placed implant indicated for mandibular first molars?

PICO Format

P: Healthy adult patients with hopeless tooth requiring extraction and restoration

I: Immediate implant placement

C: Two Stage implant therapy

O: Long term survival of first molar sites with single tooth restoration

PICO Formatted Question

- What factors dictate treatment choice between immediate implant placement versus two stage implant therapy for mandibular first molars within healthy adult patients?

Clinical Bottom Line

- Immediate implant placement has clinically comparable outcomes to two stage implant therapy and can be safely used within the scope of experienced clinicians

Search Background

- **Date(s) of Search:** 9/15/2020, 9/16/2020
- **Database(s) Used:** PubMed
- **Search Strategy/Keywords:**
 - Dental implant
 - Immediate placement
 - Two stage therapy
 - Delayed placement
 - Mandibular molar

Search Background

- **MESH terms used:**
 - Dental implant
 - Immediate placement
 - Two stage therapy
 - Delayed placement
 - Mandibular
 - molar

Article 1 Citation, Introduction

- Ketabi, Mohammad, et al. "A Systematic Review of Outcomes Following Immediate Molar Implant Placement Based on Recently Published Studies." *Clinical Implant Dentistry and Related Research*, vol. 18, no. 6, 2016, pp. 1084–1094., doi:10.1111/cid.12390.
- Study Design: Systematic Review
- Study Need / Purpose: Aim was to provide a systematic review and meta-analysis of outcomes from recent clinical studies with immediate molar implants

Article 1 Synopsis

- Method

- Systematic search of literature published from November 2008-May 2015 using databases: Embase, Ovid Medline, Pubmed, Scopus, ISI, Cochrane
- PICO format allowed definition of the study objectives
- 15 studies included providing data on 768 immediate molar implants in 757 patients
- Meta-analysis performed to compare survival rate and mean bone loss

- Results

- Implant survival rate of 98%, no difference between maxilla and mandible
- 5 studies included delayed molar implants as controls, no significant differences noted
- Higher implant failure for ultra-wide vs. wide diameter implants
- Overall cumulative bone loss after 1 year = .57 mm

Article 1 Synopsis

- Conclusions
 - Data suggests high success rates with immediate implant placement of molars, and that there may be an optimal diameter for this procedure (wide 4-6 mm).
- Limitations
 - Quality of the 15 studies were regarded as “fair to average”
 - No published reports from double-blind, randomized controlled clinical trials

Article 1 Selection

- Reason for selection
 - Directly applied to PICO
- Applicability to your patient
 - Suggests high success rate with mandibular molar immediate implant placement
- Implications
 - Immediate implant placement may be recommended for this patient, should be sure to use optimal implant diameter size

Article 2 Citation, Introduction

- Ragucci, G.M., Elnayef, B., Criado-Cámara, E. *et al.* "Immediate implant placement in molar extraction sockets: a systematic review and meta-analysis." *Int J Implant Dent* **6**, 40 (2020).
<https://doi.org/10.1186/s40729-020-00235-5>
- Study design: Systematic Review and Meta-Analysis
- Study purpose: In patients over 18 years of age, does the placement of immediate implants in molar areas result in similar implant survival rate, success rate, and marginal bone loss as implants installed in healed sites, after 6 months of healing from tooth extraction?

Article 2 Synopsis

- Method
 - literature review of Pubmed, Cochrane and MEDLINE electronic databases
 - Two independent reviewers screened and selected
 - 20 articles included, 990 patients and 1,106 implants analyzed
 - Meta-analysis performed on selected articles using 95% confidence interval
- Results
 - Overall:
 - 97.8% survival rate
 - 93.1% success rate
 - Posterior Mandible:
 - 97.4% survival rate
 - 97.5% success rate
 - (less than maxilla but not significantly significant.)
 - Estimated MBL over 1 year 1.29 +/- .24 mm
 - Higher implant success in grafted vs. non grafted
 - Higher implant survival in < 5 mm diameter group vs >5 mm

Article 2 Synopsis

- Conclusions
 - Immediate implant placement in molar extraction socket might be considered a predictable technique as demonstrated by high survival and high success rates with minimal bone loss
- Limitations
 - Included articles of lower evidence in the review – case series, cohort, retrospective studies
 - Had to exclude an article from meta-analysis due to its small sample size of 12 implants
 - Not all articles had a 'comparison group'

Article 2 Selection

- **Reason for selection**
 - Directly applied to PICO question – immediate implant placement in molar sites
 - Recent data of high evidence emphasizing consistency in results from previous meta-analysis
- **Applicability to your patient**
 - Survival and success rate of IIP molar implants
- **Implications**
 - Immediate implant placement for this patient would be recommended and have high success and survival rate

Article 3 Citation, Introduction

- Amin, Viraj, et al. "A Clinical and Radiographical Comparison of Buccolingual Crestal Bone Changes after Immediate and Delayed Implant Placement." *Medicine and Pharmacy Reports*, 2019, doi:10.15386/mpr-1213.
- Study Design: Randomized controlled trial
- Study Need / Purpose: To clinically and radiographically compare the bucco-lingual crestal bone changes after immediate and delayed placement of implants

Article 3 Synopsis

- Method
 - 50 subjects needing extraction and replacement with dental prosthesis in anterior and premolar region
 - Group A: immediate implants, Group B: implant placement delayed 6-8 weeks post extraction
 - All implants submerged within alveoli confines, primary flap closure ensured
 - Bone grafts only placed if jumping distance more than 1.5 mm
 - No barrier membrane placed
 - BL width measured at time of implant placement and during abutment placement (6 mo)
- Results
 - 31 implants placed in mandible, 19 placed in maxilla
 - All implants successful , all achieved osseointegration with no mobility
 - No statistically significant comparisons between group A and B

Article 3 Synopsis

- Conclusions
 - Data in both groups suggest that the circumferential defect around implant will heal on itself without guided bone regeneration. Healing in both groups were equally good.
 - Immediate implant placement saves cost, time, and need for extra surgery
- Limitations
 - This focused on premolar region rather than molar region
 - Small sample size – 50 subjects
 - Short follow up period – would prefer longer

Article 3 Selection

- Reason for selection
 - Directly compares immediate to delayed implant placement
- Applicability to your patient
 - Can be used to weigh effects of choosing between immediate vs. delayed
- Implications
 - Healing and osseointegration for immediate implant placement is comparable to delayed, and could therefore be safely recommended to our patient

Levels of Evidence

- ☒ **1a** – Clinical Practice Guideline, Meta-Analysis, Systematic Review of Randomized Control Trials (RCTs)
- ☒ **1b** – Individual RCT
- ☐ **2a** – Systematic Review of Cohort Studies
- ☐ **2b** – Individual Cohort Study
- ☐ **3** – Cross-sectional Studies, Ecologic Studies, “Outcomes” Research
- ☐ **4a** – Systematic Review of Case Control Studies
- ☐ **4b** – Individual Case Control Study
- ☐ **5** – Case Series, Case Reports
- ☐ **6** – Expert Opinion without explicit critical appraisal, Narrative Review
- ☐ **7** – Animal Research
- ☐ **8** – In Vitro Research

Strength of Recommendation Taxonomy (SORT)

<input checked="" type="checkbox"/>	A – Consistent, good quality patient oriented evidence
<input type="checkbox"/>	B – Inconsistent or limited quality patient oriented evidence
<input type="checkbox"/>	C – Consensus, disease oriented evidence, usual practice, expert opinion, or case series for studies of diagnosis, treatment, prevention, or screening

Conclusions: D3

How does the evidence apply to this patient?

- Literature suggests that immediate implant placement is comparable to delayed/two-stage implant placement in terms of osseointegration, healing, success and survival.
- Discussion with Dr. Brunner about his clinical experience further provided evidence that immediate implant placement is a comparable treatment option
- Patient wants to limit number of appointments and is eager to get the implant placed. Not overly concerned with cost.

Based on the above considerations, how will you advise your D4?

- Recommend offering immediate implant placement as a safe, time efficient, and comparable alternative to delayed, two-stage.

Conclusions: D4

-Immediate implant recommended in order to expedite process at dental school, take advantage of adequate existing bone level and the ideal site conditions.

THANK YOU

[Insert relatable and witty
dental school meme]