

# PERI-IMPLANTITIS


## EVIDENCE BASED DENTISTRY ROUNDS - PERIODONTICS

Group 10 B2

D1 – Kelly Herzog. D2 – Schuchi Patel,

D3 – Jisoo Hong, D4 – Maggie Meyer

October 21, 2020



# ROUNDS TEAM



- Group Leader : Dr.Yray
- Specialty Leader : Dr. Guentsch
- D4 – Maggie Meyer
- D3 – Jisoo Hong
- D2 – Schuchi Patel
- D1 – Kelly Herzog





# PATIENT INFORMATION

- 73 year old African American Female
- Presents for Transfer Exam July 21 2020
- Implant #14 placed November 2018 and restored August 2019
- Chief Complaint – “I sometimes have bleeding around my upper back implant when I brush”



# MEDICAL HISTORY

- Medications
  - Lisinopril - High blood pressure
  - Zetia – Cholesterol
  - Crestor – Cholesterol
  - Baby Aspirin
  - Multi-Vitamin
- Allergy
  - Morphine – itching
- BP at transfer exam
  - 130/87



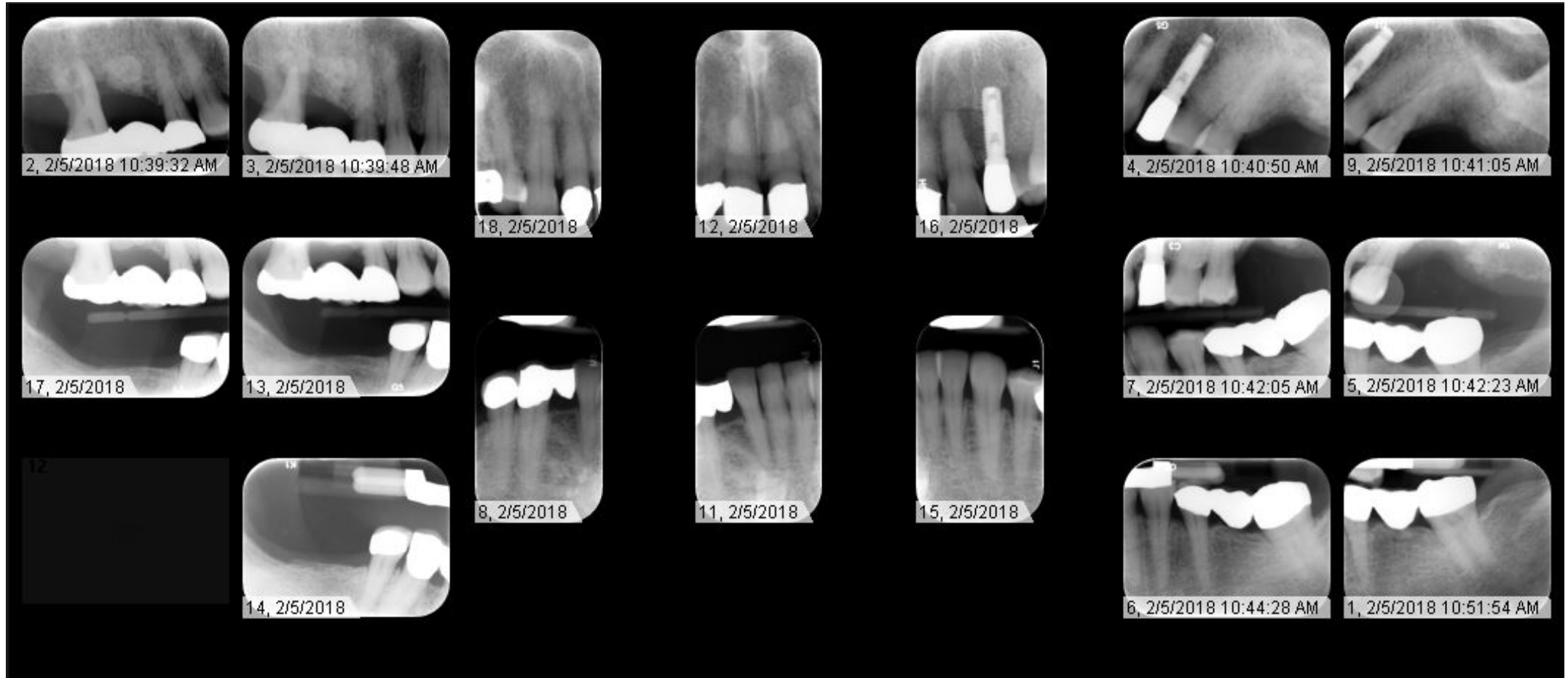
# DENTAL HISTORY

- Patient comes consistently for cleanings/exams
- Past extractions
- Implants in #11, 14, and 30
- Periodontal treatments
- CORAH – 5 – feels relaxed in the dental chair





# RADIOGRAPHS – FMX 2018

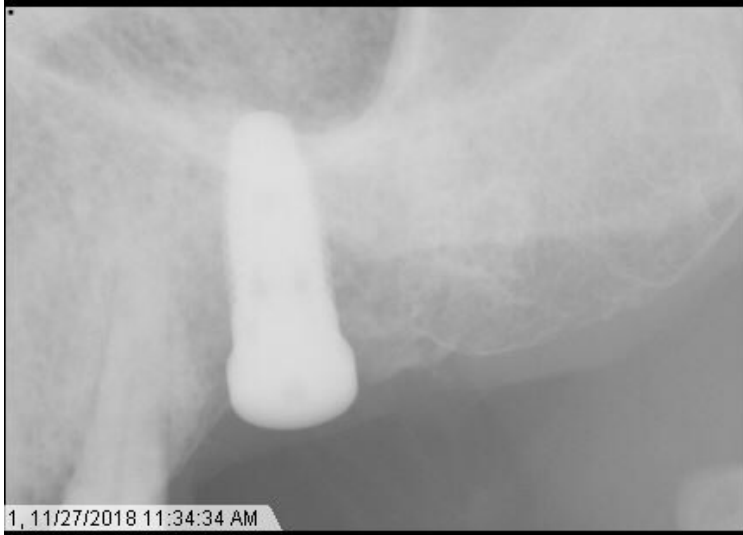

# RADIOGRAPHIC FINDINGS

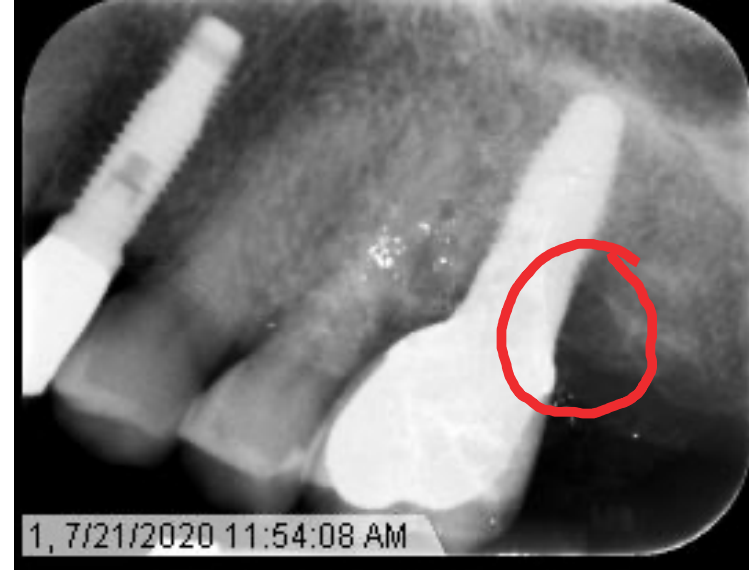- Bone resorption around implant #14 since placement of the crown on 8/27/2019



# RADIOGRAPHS

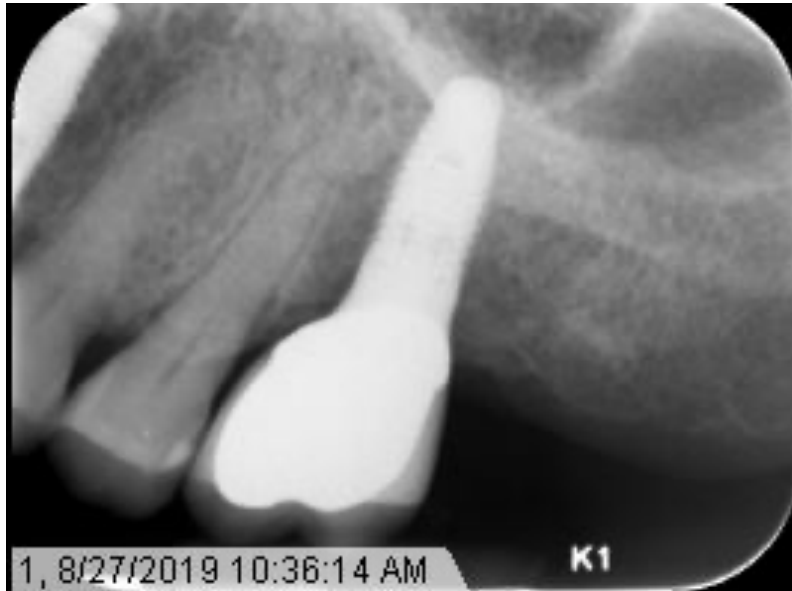

1. 11/18  
Implant  
Placement

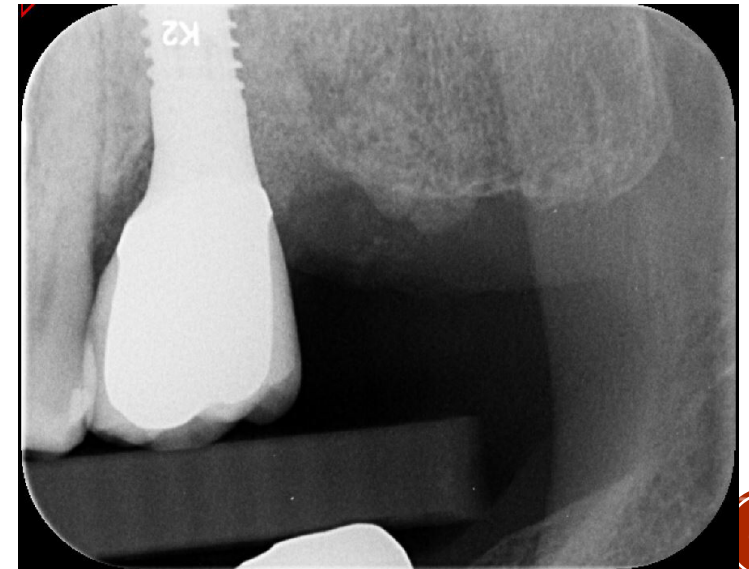


3. 7/20  
Transfer Exam  
– crater defect

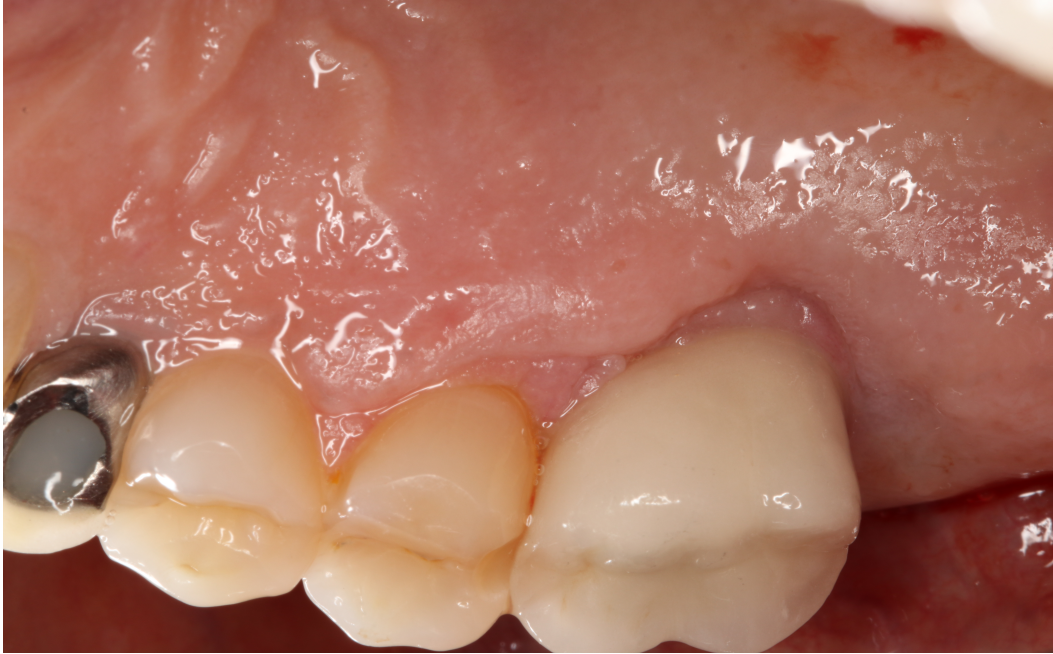2. 8/19  
Implant  
Restored



4. 8/20  
After Bone  
Graft







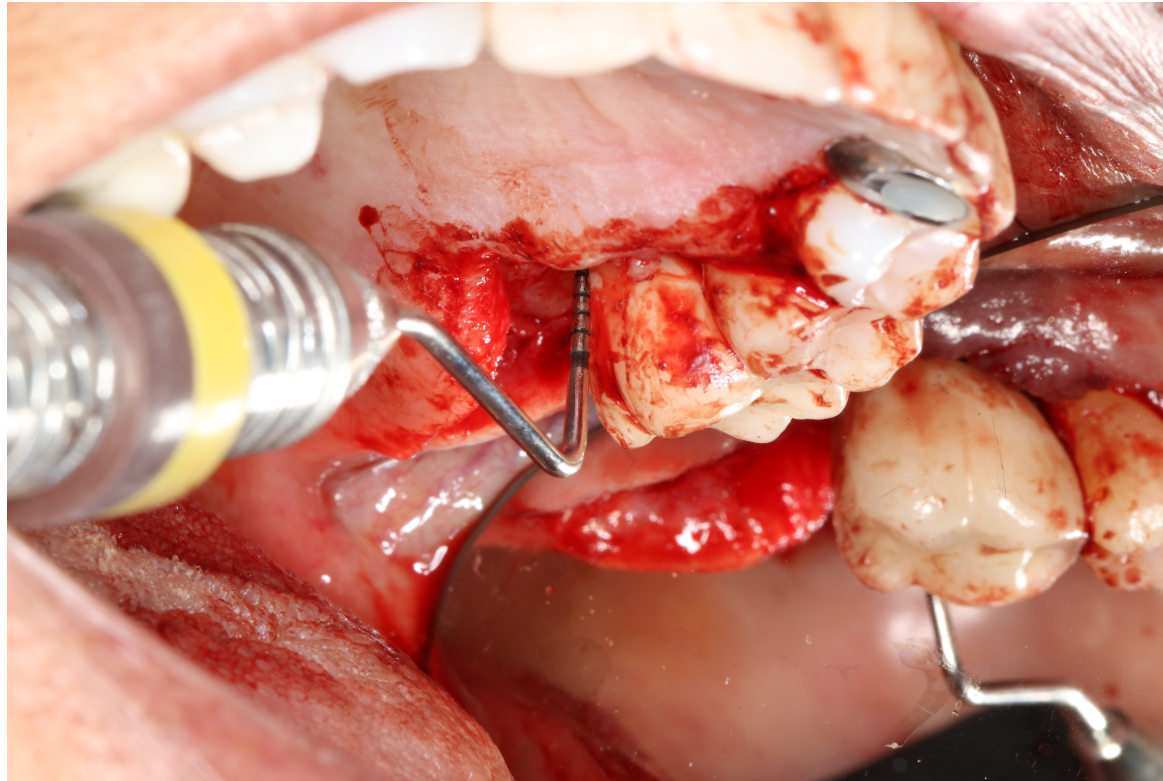
- Visible granulation tissue around implant.
- Red and edematous papillary tissue
- Recession on the palatal aspect of the implant fixture exposing threads

## CLINICAL FINDINGS



# PERIODONTAL FINDINGS

- 10mm pocket DL and 6mm ML
- Very sensitive to probing and BOP



# PERIODONTAL DIAGNOSIS

- Peri-implantitis with a crater bone defect





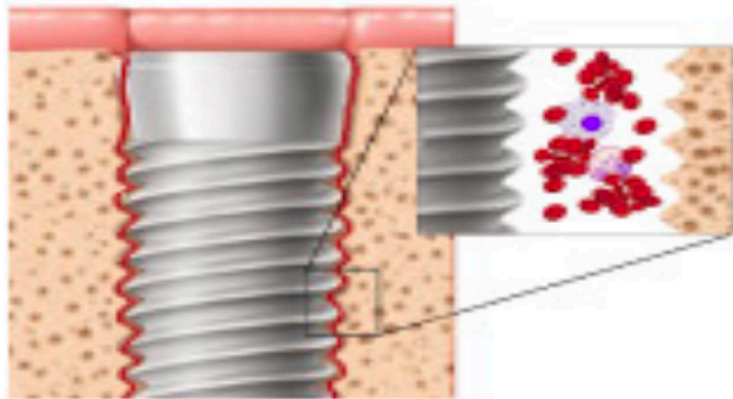
# PROBLEM LIST

- Peri-implantitis #14
- Filling over implant #11 fell out
- #30 implant need to be restored with crown



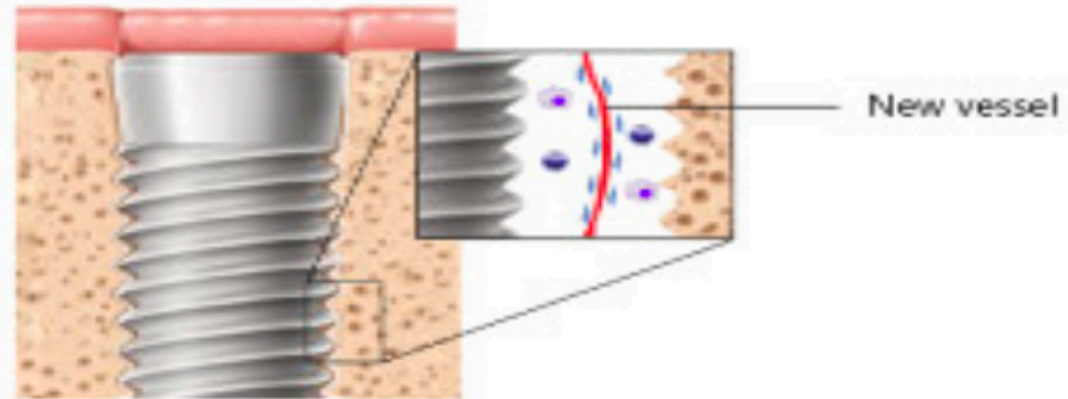
# D1 BASIC SCIENCE - What is osseointegration?

Primarily mechanical stability



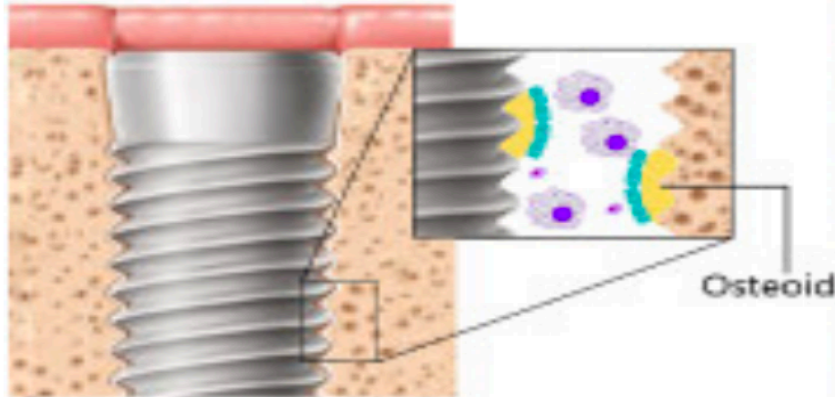
In 24 hours

New vessel formation



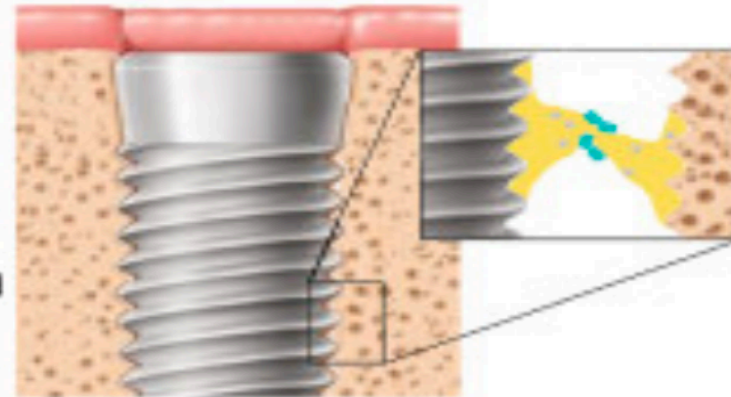
On the 4th day

Temporary loosening



On the 4th week

Secondary stability



After 6-8 weeks

- Neutrophil
- Macrophage
- Erythrocyte
- Monocyte
- Mesenchymal stem cell
- Osteoblast
- T cell
- Osteocyte

# D2 PATHOLOGY - WHAT IS PERI- IMPLANTITIS AND WHAT LEADS TO ITS ONSET?

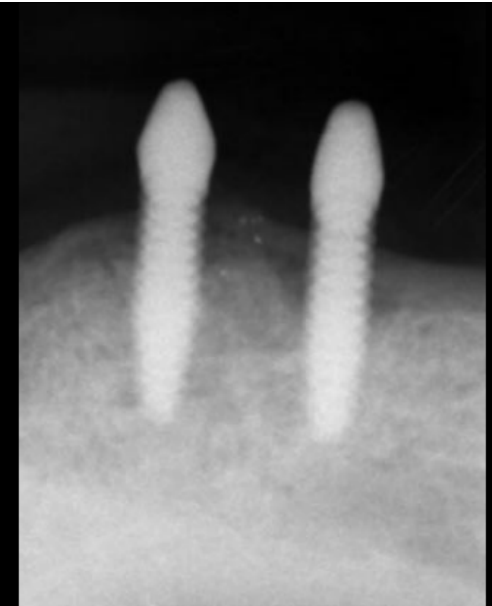
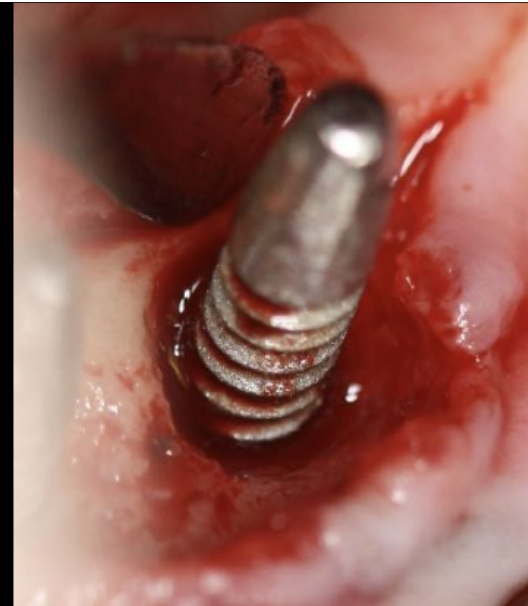
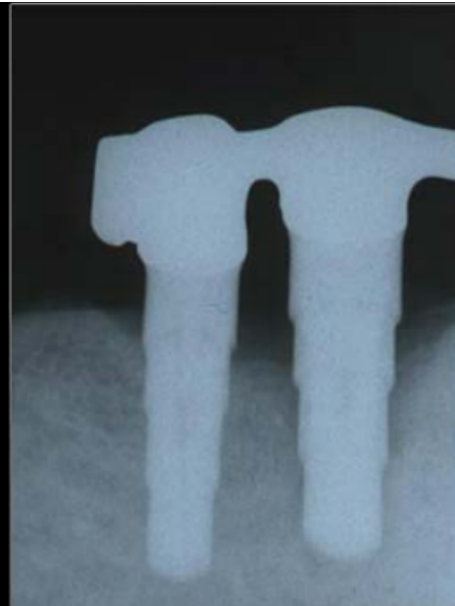
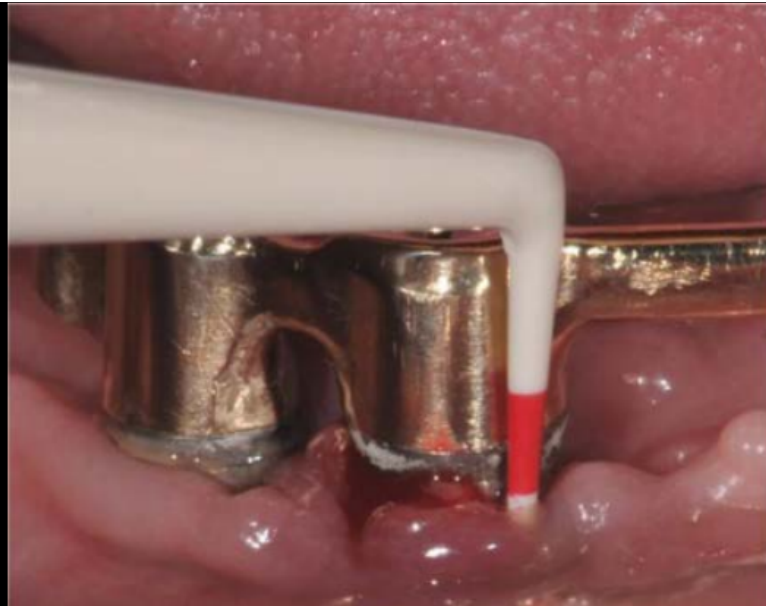- Inflammatory reaction from loss of supporting bone around implant<sup>1</sup>
  - Inflammation, BOP, increased pocket depths, progressive bone loss, 2-3 mm bone loss radiographically, >6mm probing depths<sup>1</sup>
- Smoking, diabetes mellitus, lack of prophylaxis, history of periodontitis<sup>2</sup>

1. Dreyer, H, Grischke, J, Tiede, C, et al. **Epidemiology and risk factors of peri-implantitis: A systematic review.** *J Periodont Res.* 2018; 53: 657- 681.

<https://0-doi-org.libus.csd.mu.edu/10.1111/jre.12562>

2. Lee, C., Huang, Y., Zhu, L., & Weltman, R. **Prevalences of peri-implantitis and peri-implant mucositis: systematic review and meta-analysis** (2017). *Journal of Dentistry*, 62, 1-12. doi:<https://0-doi-org.libus.csd.mu.edu/10.1016/j.jdent.2017.04.011>

Image: Guentsch, A. **Peri-Implant Diseases and Conditions.** *Marquette University School of Dentistry.* Class Presentation.





# D3 PICO



# CONCLUSIONS : D4

- Based off the D3's bottom line, I would advise my patient to....
- 



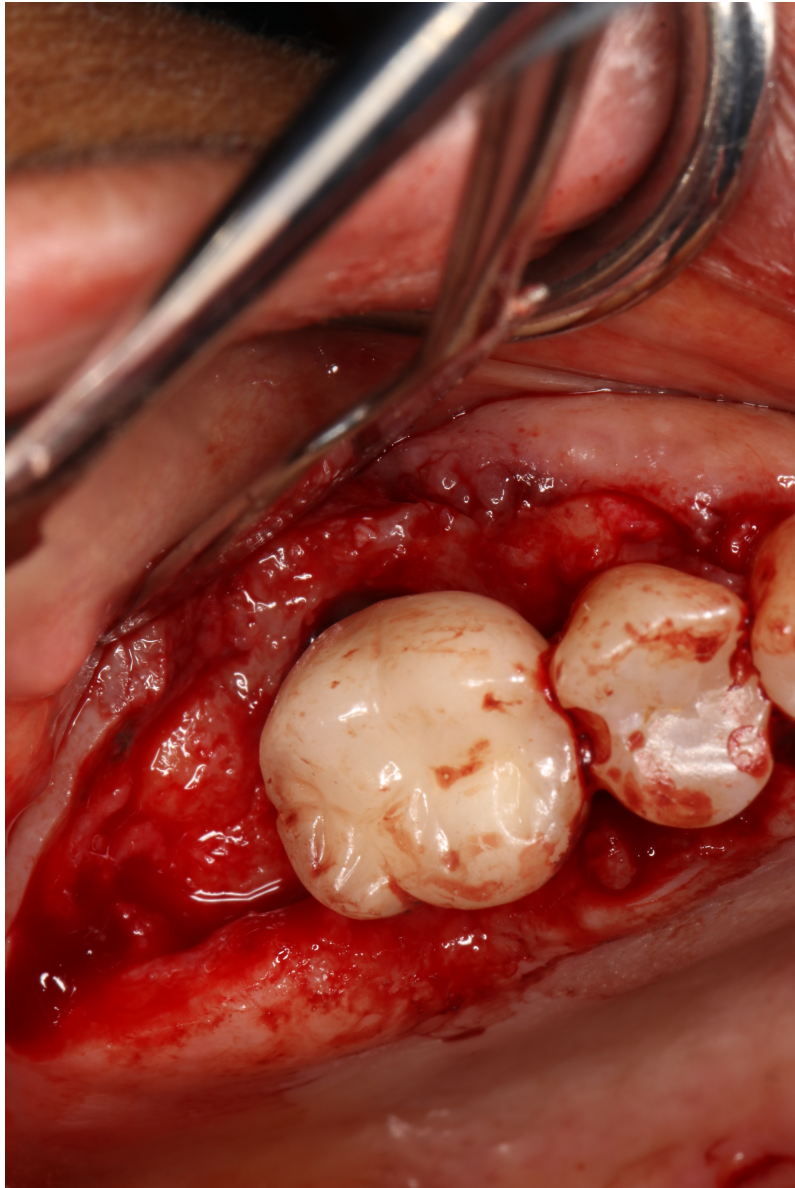

# WHAT HAPPENED?

- Perio resident treated with guided bone regeneration
  - Incision and degranulation
  - Cleaned implant surface with doxycycline and saline
  - Used bone graft to fill crater defect
  - Placed membrane over bone graft
  - Sutured

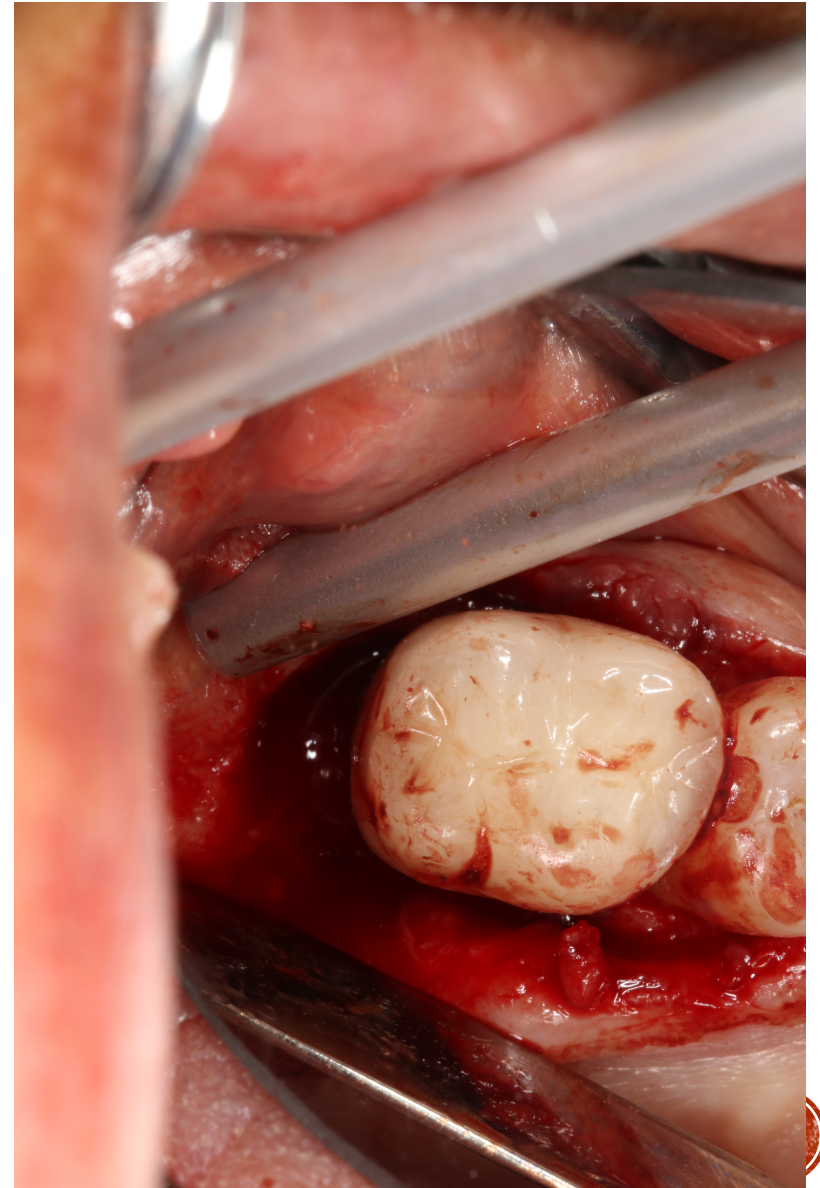


# SURGICAL PICTURES

After Incision

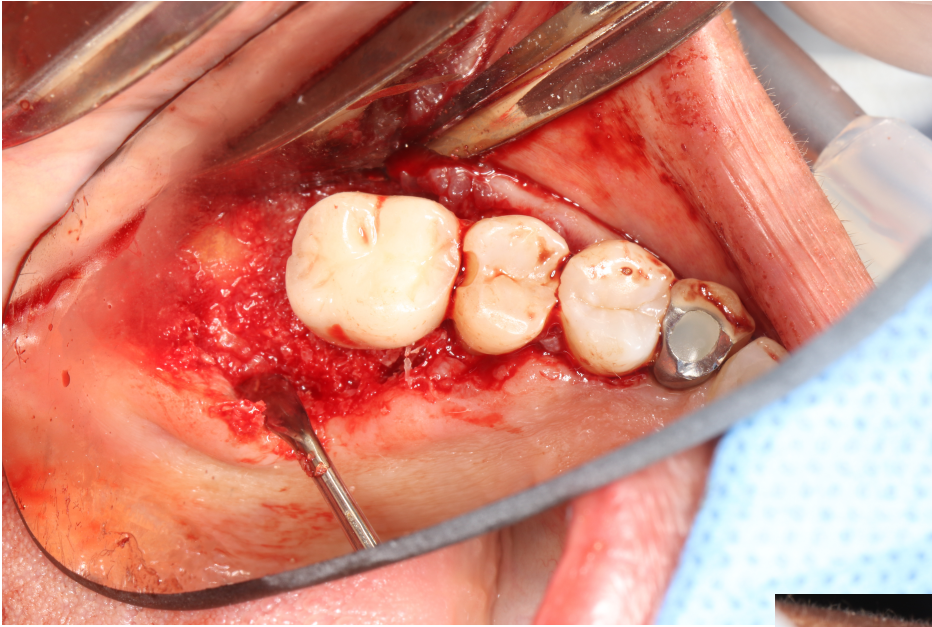


After  
Degranulation



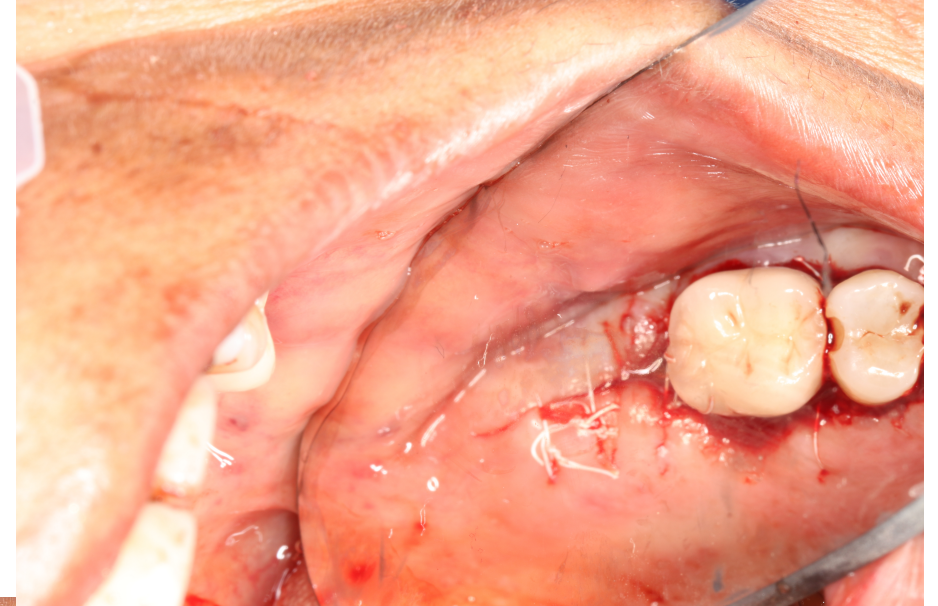


# SURGICAL PICTURES

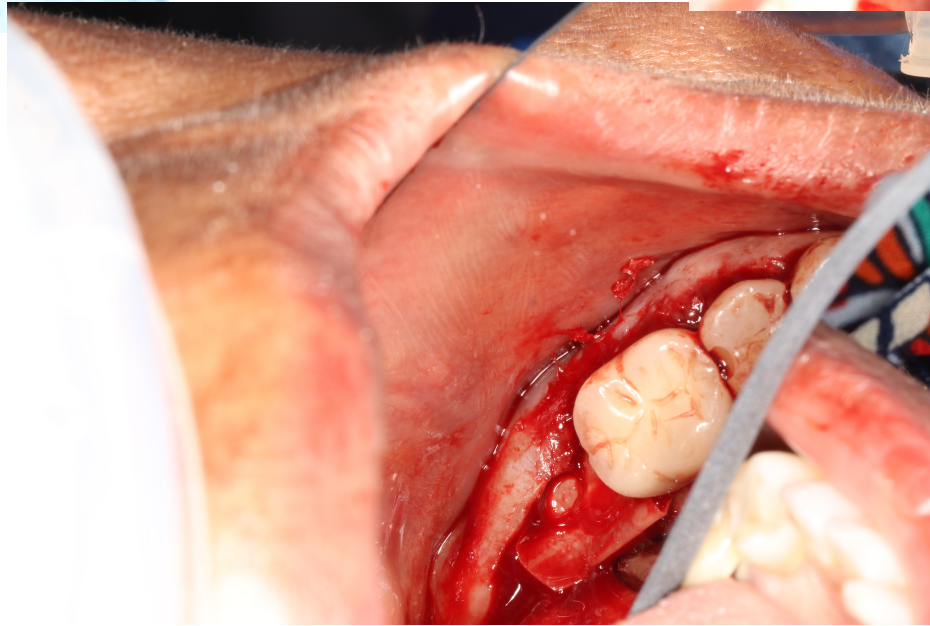


**Bone Graft**

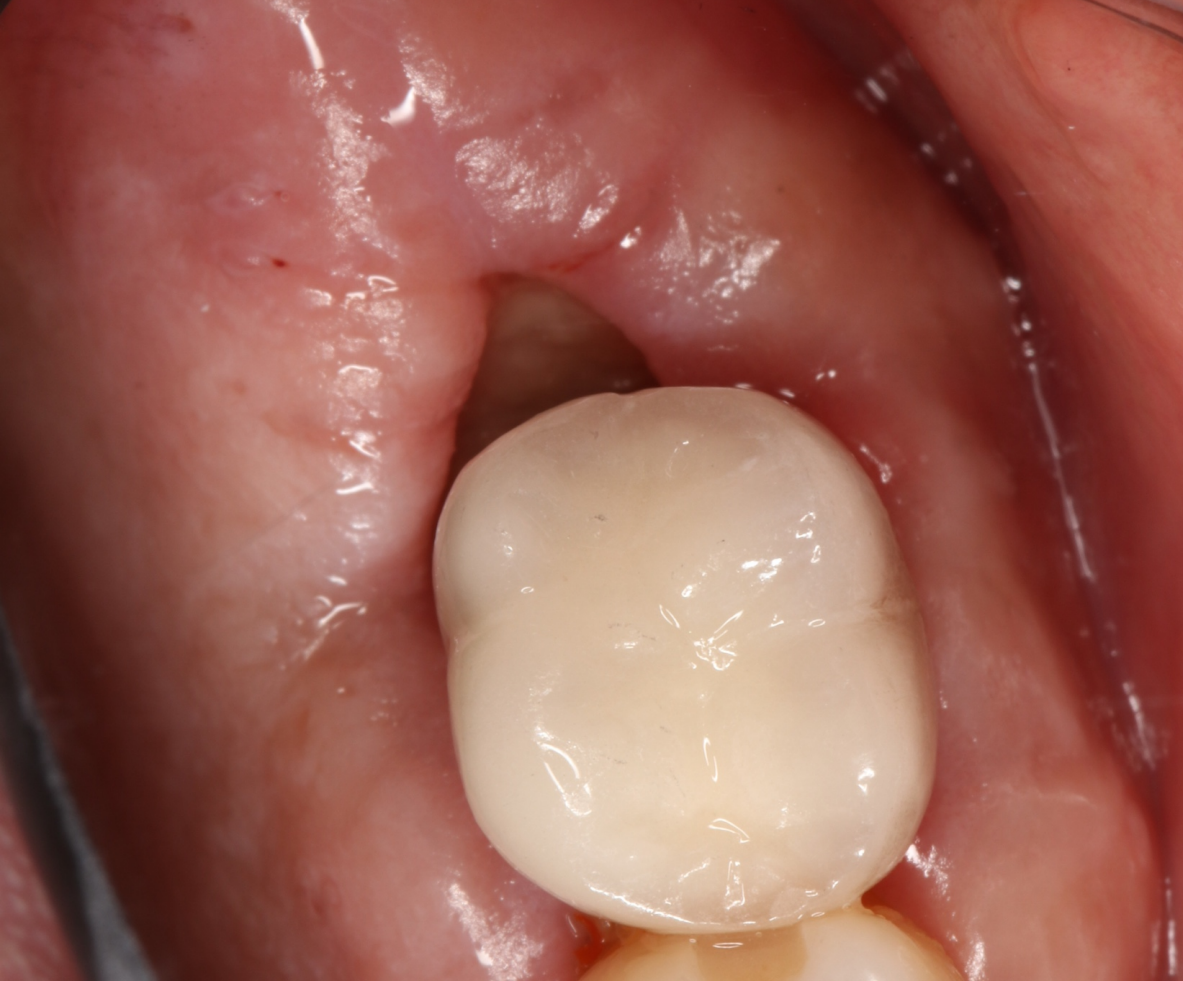**Membrane**



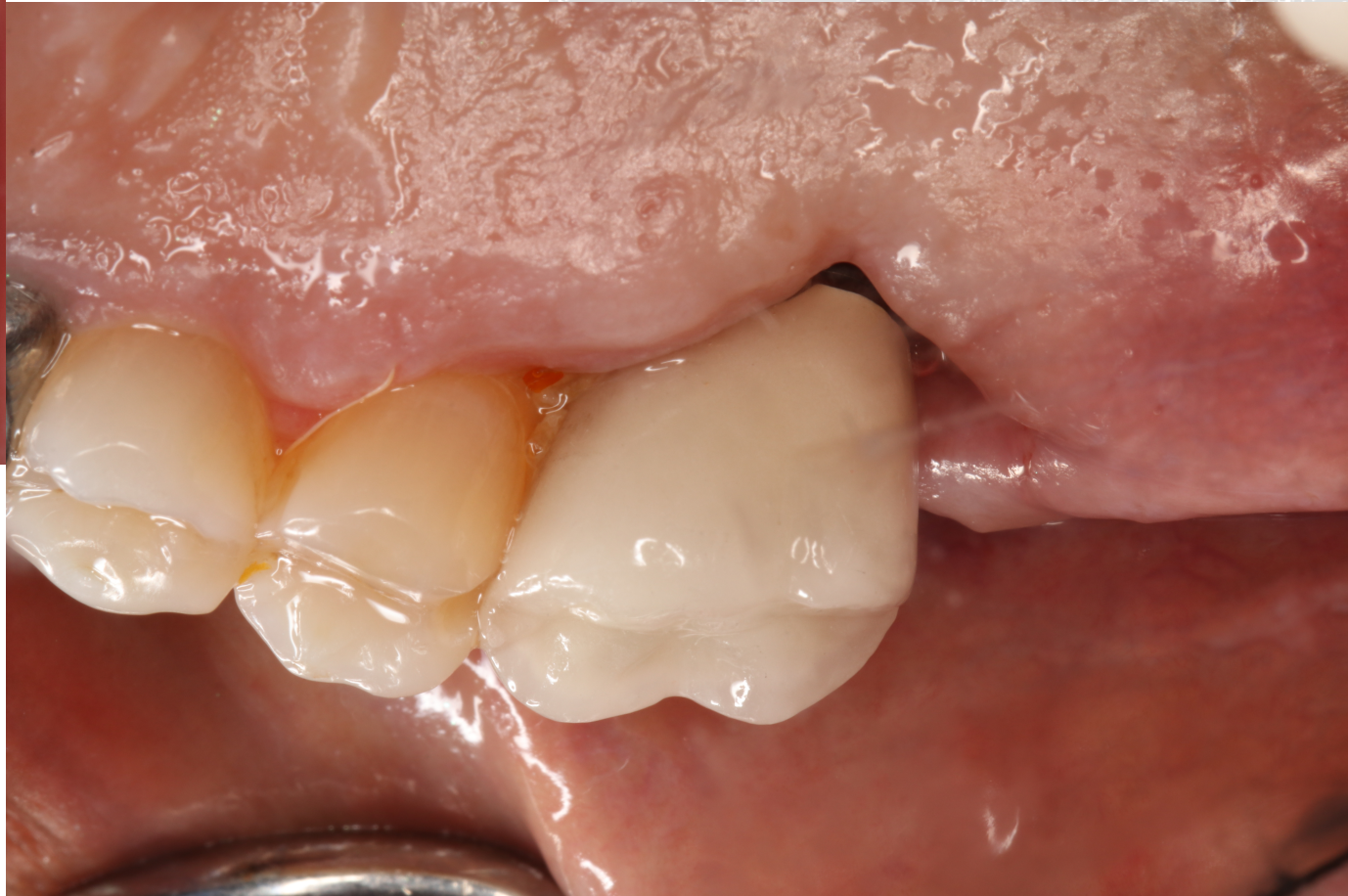**Sutures**







# POST-OP PICTURES





THANK YOU!

