

Evidence Based Dentistry Rounds

Periodontics

Group: 6B-3

Date: 10/21/2020

Rounds Team

- Group Leader: Dr. Cimrmancic
- Specialty Leader: Dr. Garcia
- Project Team Leader: D4 Angela Schmidt
- Project Team Participants:
 - D1 Christian Borer
 - D2 Juno Park
 - D3 Abdulkareem Harunani

Patient

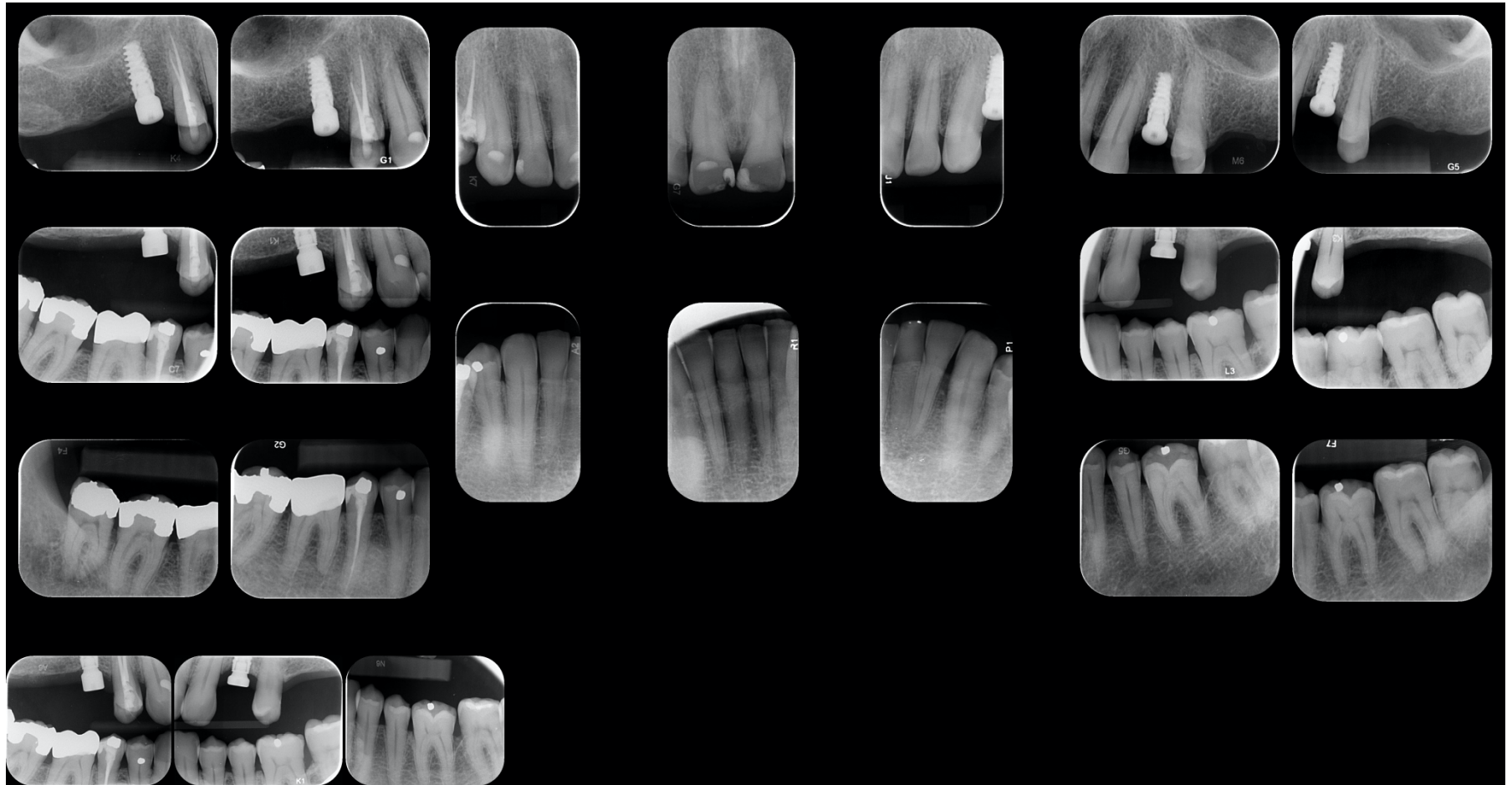
- 61-year-old Hispanic Male
- “I need to get my crowns for my implants”
- Patient is has Stage 3 Grade B periodontitis and extremely poor oral hygiene.
- Transferred patient in July 2020 ready to have final cast mounted and submitted to lab for fabrication of three implant crowns.

Medical History

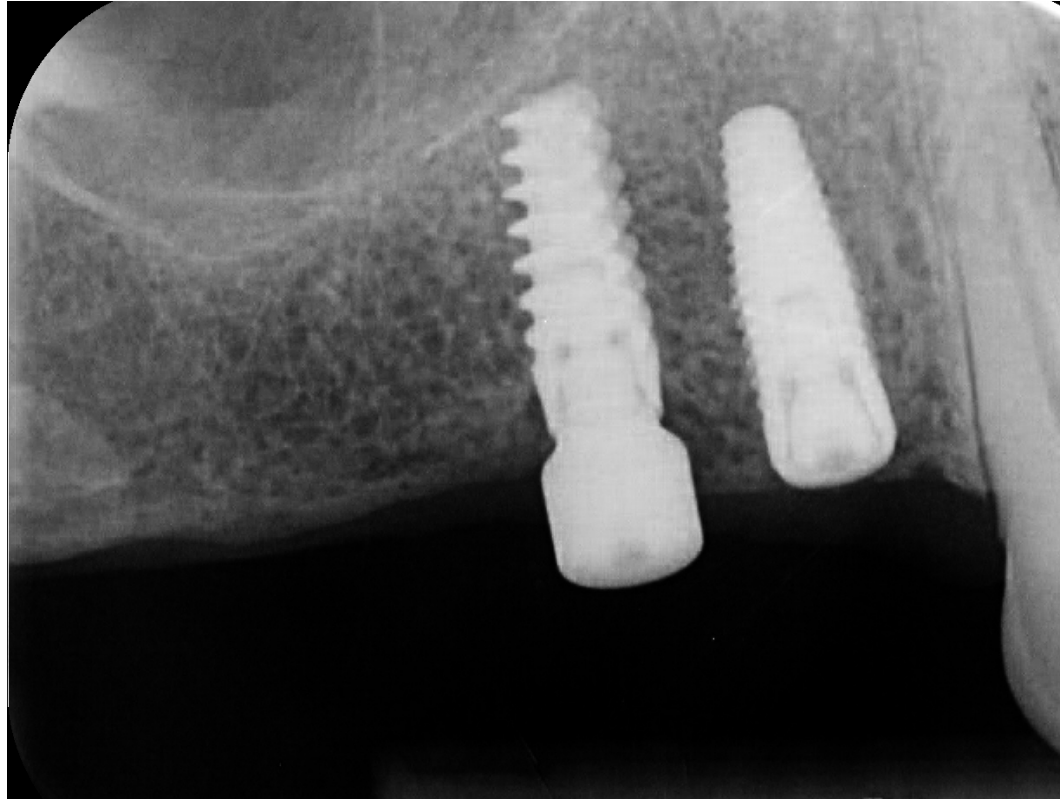
- Non-contributory medical history
 - High blood pressure
 - Stomach cancer 2009
 - Surgery for resection
 - Chemotherapy
 - Radiation
- Medications
 - Lisinopril 5mg, 1x/day

Dental History

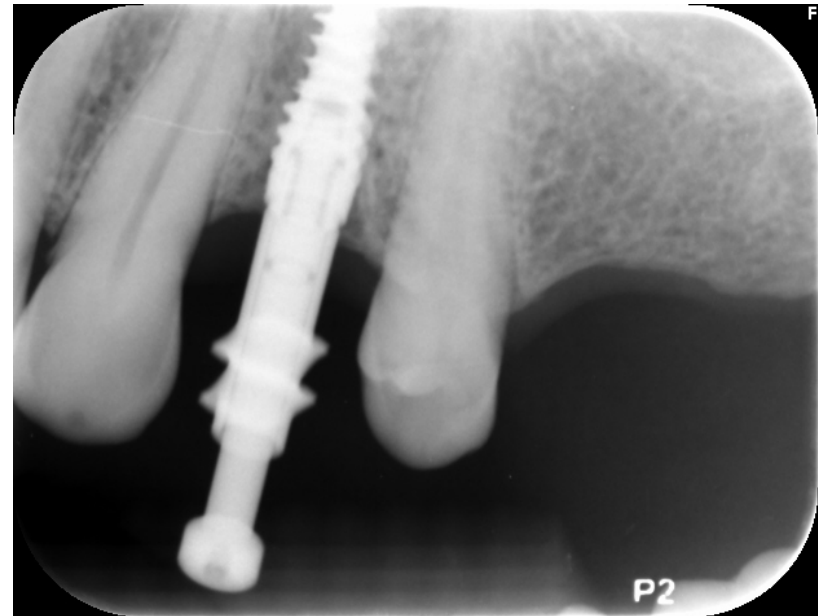
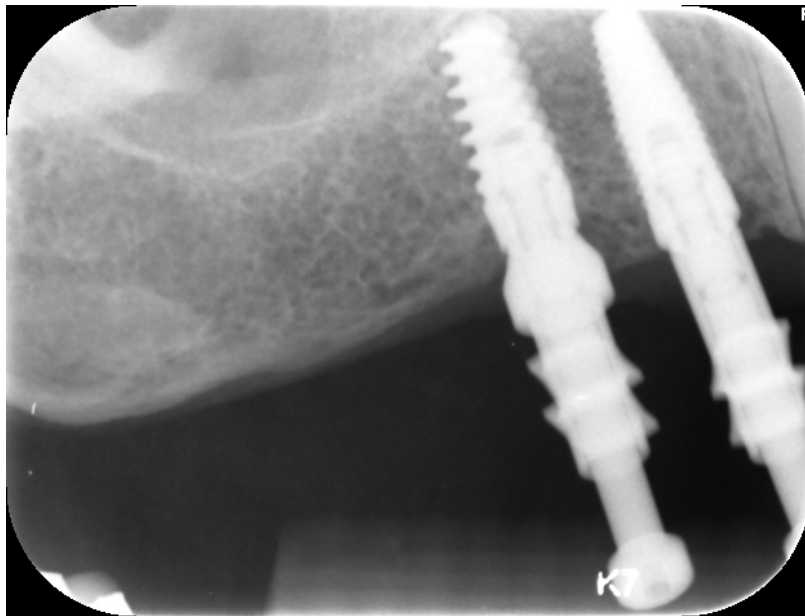
- Infrequent dental cleanings in the past
- SRP completed in November 2018 with perio maintenance completed June 2019 and February 2020
- Missing all maxillary posteriors except #13
- Implants placed at sites #4 and 12 at off-site oral surgery office over two years ago
- Implant placed at site #5 at Marquette November 2019
- Does not floss, infrequent brushing of teeth
- Has been recommended to extract mandibular third and possibly second molars for five+ years



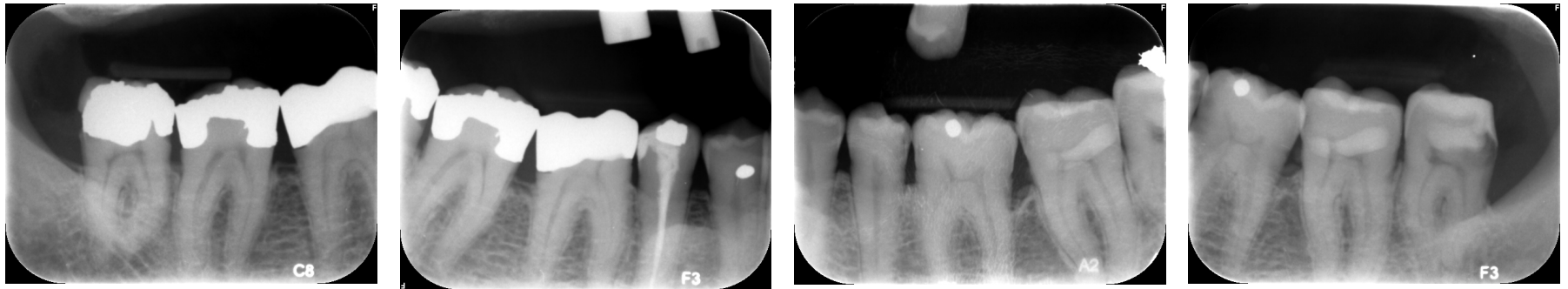
Radiographs: FMX 9/7/18



Radiographs: Implant Placed 7/12/19



Radiographs: Impression Copings 2/7/19



Radiographs: BW 9/4/20

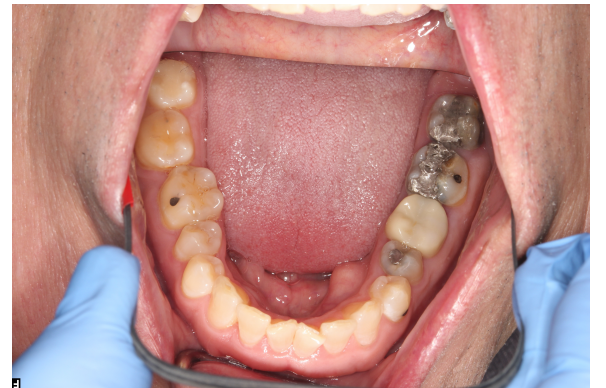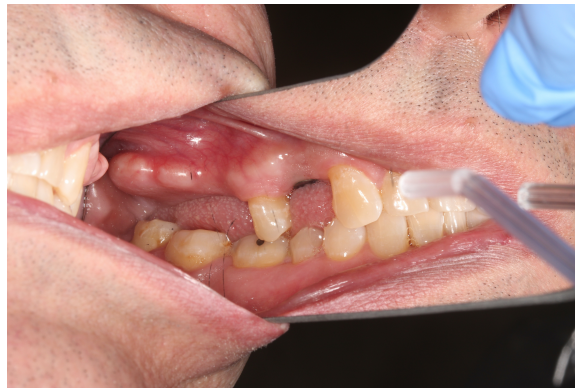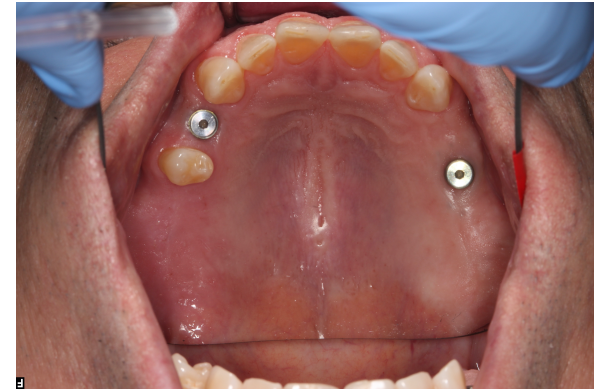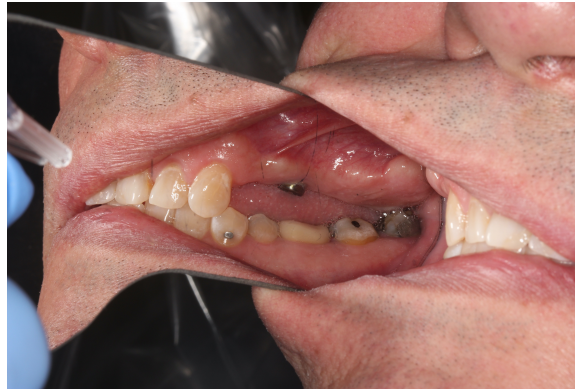Radiographic Findings

- Three maxillary unrestored implants
- Vertical bone loss tooth #17, 19
- Generalized horizontal bone loss full dentition
 - Primarily mandibular posteriors

Clinical Findings

- Heavy plaque, heavy calculus
- Enlarged and rolled marginal gingiva on all mandibular posterior teeth
- Red marginal gingiva buccal mandibular posteriors and facial maxillary anteriors
- Blunted and edematous papilla mandibular posteriors
- BOP 65 points
- Probing depths ranging 5-7mm all mandibular molars

Clinical Findings 5/3/2019



Specific Clinical Findings

- Uncontrolled periodontitis, Stage 3 Grade B
- Poor oral hygiene

Diagnosis

- Stage 3 Grade B Periodontitis

Problem List

- Three un-restored maxillary implants
- Uncontrolled periodontitis
- Deep pocketing and inflammation around second and third mandibular molars
- Poor oral hygiene
- Risk for peri-implantitis

D1 Basic Science

Question:

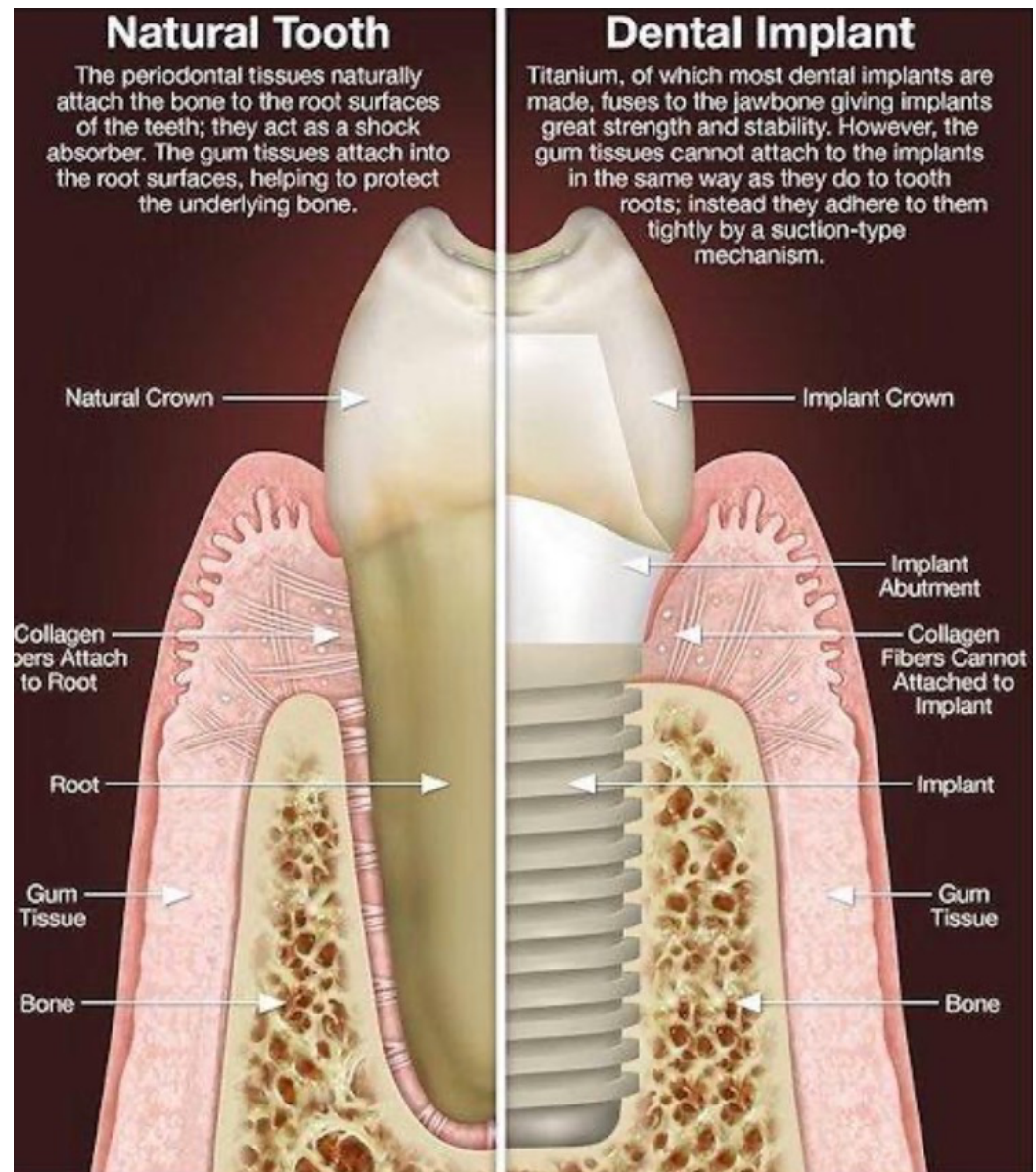
What is the anatomy of the periodontium supporting a single tooth vs. an implant?

Discussion:

The natural periodontium consists of an alveolar socket within which the root of each tooth rests.

The bone and the cementum are tethered to each other by the periodontal ligament

This ligament attaches the tooth to the alveolar socket and acts as a shock absorber.



D1 Basic Science

- In the case of a dental implant, the periodontal ligament is no longer present
- The titanium implant has direct contact with the bone.
- Titanium is one of the few materials that will osseointegrate into the surrounding bone tissue.

D2 Pathology

Question:

What is peri-implantitis?

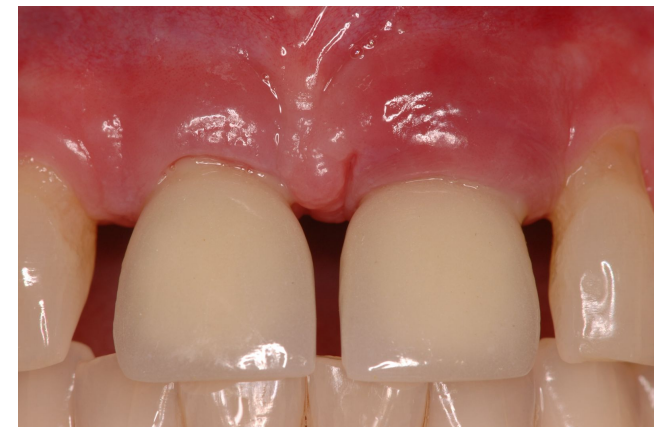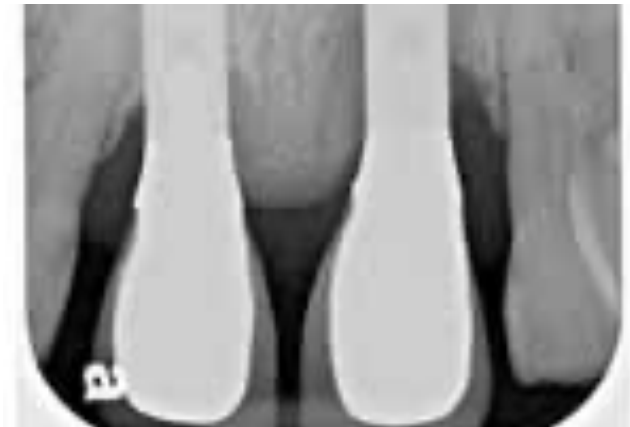Discussion:

Definition: Peri-implantitis is localized infectious disease that results in inflammatory process in soft tissue and bone loss around an Osseo-integrated implant. Unlike peri-implant mucositis, which is the other common peri-implant disease, there is deterioration in the bone supporting the dental implant.

Cause:

- Design of the implant
- Roughness of the implant
- Excessive mechanical load
- Poor oral hygiene
- Tobacco usage
- Systemic condition such as diabetes and osteoporosis
- Bruxism or parafunctional habits

Peri-implantitis
(bone involved)



Peri-implant mucositis
(bone not-involved)

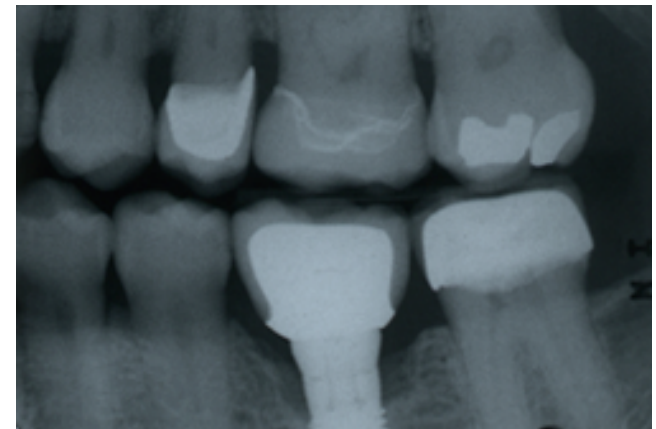
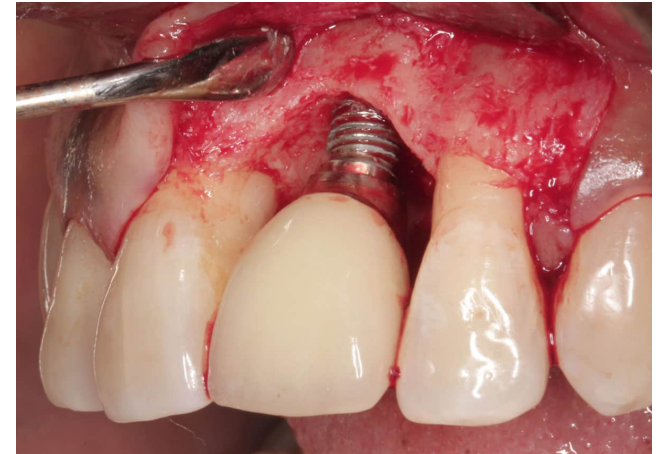
D2 Pathology

Diagnosis:

- 1) Gingiva color change – inflamed gum tissue
- 2) bleeding and probing depth of peri-implant pockets
- 3) Gradual loss of bone height around the tooth
- 4) Bad taste possible if pus is present (suppuration – discharging of pus)
- 5) X-ray → recession of bone surrounding implant

Treatment:

- 1) Control of infection
- 2) Detoxification of the implant surface
- 3) Regeneration of the alveolar bone



D₃ PICO

- **Clinical Question:**
 - What risk is this patient at for peri-implantitis with their history of periodontitis?

PICO Format

P: Incidence of Peri-Implantitis
I: Patients with Periodontitis
C: Patients without Periodontitis
O: Implant Success

PICO Formatted Question

- What is the incidence of peri-implantitis in patients with history of periodontitis compared to patients without periodontitis resulting in implant success?

Clinical Bottom Line

- A patient's severe periodontitis must be managed in order to decrease the likelihood of peri-implantitis and have a more successful treatment outcome

Search Background

- **Date(s) of Search:** 9/25/2020
- **Database(s) Used:** PubMed
- **Search Strategy/Keywords:** periimplantitis, periodontitis, peri-implantitis

Search Background

- MESH terms used: humans, dental, implants

Article 1

Citation, Introduction

- **Citation:** Sgolastra F, Petrucci A, Severino M, Gatto R, Monaco A. Periodontitis, implant loss and peri-implantitis. A meta-analysis. Clin Oral Implants Res. 2015 Apr;26(4):e8-e16.
- **Study Design:** Meta-Analysis
- **Study Need / Purpose:** “To assess the tole of periodontal disease as a risk factor for implant loss, peri-implantitis, and implant-bone loss”

Article 1

Synopsis

- **Methods:** 7391 publications were narrowed down to 16 for a systematic review. Dichotomous data was broken down into a risk ratio and confidence interval, and continuous data was broken into a standardized mean difference. A random effect model was created for both types of data. The pooled effect was then analyzed.
- **Results:** Periodontitis led to a statistically significant higher risk for implant loss and implant bone loss. Also led to a slightly lower but still statistically significant risk for peri-implantitis.
- **Conclusions:** Periodontitis is linked to peri-implantitis. Getting periodontitis under control is important prior to implant placement.


Article 1 Selection

- **Reason for selection:** Answers the question directly. Periodontitis leads to a higher risk of peri-implantitis.
- **Applicability to your patient:** Due to existing periodontitis, they are at a higher risk for peri-implantitis.
- **Implications:** Restoring implants might be a poor idea until the periodontitis is under control.

Levels of Evidence

- ☒ **1a** – Clinical Practice Guideline, Meta-Analysis, Systematic Review of Randomized Control Trials (RCTs)
- ☐ **1b** – Individual RCT
- ☐ **2a** – Systematic Review of Cohort Studies
- ☐ **2b** – Individual Cohort Study
- ☐ **3** – Cross-sectional Studies, Ecologic Studies, “Outcomes” Research
- ☐ **4a** – Systematic Review of Case Control Studies
- ☐ **4b** – Individual Case Control Study
- ☐ **5** – Case Series, Case Reports
- ☐ **6** – Expert Opinion without explicit critical appraisal, Narrative Review
- ☐ **7** – Animal Research
- ☐ **8** – In Vitro Research

Strength of Recommendation Taxonomy (SORT)

	A – Consistent, good quality patient oriented evidence
<input type="checkbox"/>	B – Inconsistent or limited quality patient oriented evidence
<input type="checkbox"/>	C – Consensus, disease oriented evidence, usual practice, expert opinion, or case series for studies of diagnosis, treatment, prevention, or screening

Article 2

Citation, Introduction

- **Citation:** Dreyer H, Grischke J, Tiede C, Eberhard J, Schweitzer A, Toikkanen SE, Glöckner S, Krause G, Stiesch M. Epidemiology and risk factors of peri-implantitis: A systematic review. J Periodontal Res. 2018 Oct;53(5):657-681.
- **Study Design:** Systematic Review
- **Study Need / Purpose:** “to assess the prevalence, incidence and risk factors of peri-implantitis in the current literature”

Article 2 Synopsis

- **Method:** 8357 studies were whittled down to 57. Heterogeneity analysis and a random effect meta-analysis was done for pre-selected risk factors for peri-implantitis.
- **Results:** "The prevalence of peri-implantitis on implant level ranged from 1.1% to 85.0% and the incidence from 0.4% within 3 years, to 43.9% within 5 years, respectively." ... "On a medium and medium-high level of evidence, smoking (effect summary OR 1.7, 95% CI 1.25-2.3), diabetes mellitus (effect summary OR 2.5; 95% CI 1.4-4.5), lack of prophylaxis and history or presence of periodontitis were identified as risk factors of peri-implantitis. There is medium-high evidence that patient's age (effect summary OR 1.0, 95% CI 0.87-1.16), gender and maxillary implants are not related to peri-implantitis. Currently, there is no convincing or low evidence available that identifies osteoporosis, absence of keratinized mucosa, implant surface characteristics or edentulism as risk factors for peri-implantitis."
- **Conclusions:** Periodontitis is linked to a higher risk of peri-implantitis.
- **Limitations:** Sample sizes are relatively small, and the studies used span from 1980 to 2016, so implant technology has changed much during that period. Therefore, some of the studies involved in the review are potentially done on old implant designs that are no longer in use.

Article 2 Selection


- **Reason for selection:** Article has high level of evidence and answers the question directly.
- **Applicability to your patient:** Patient has periodontitis just like the patients in the article and it is compared to a baseline of many different types of patients with varying levels of health including healthy patients.
- **Implications:** The periodontitis in the patient increases the risk for peri-implantitis.

Levels of Evidence



- ☒ **1a** – Clinical Practice Guideline, Meta-Analysis, Systematic Review of Randomized Control Trials (RCTs)
- ☐ **1b** – Individual RCT
- ☐ **2a** – Systematic Review of Cohort Studies
- ☐ **2b** – Individual Cohort Study
- ☐ **3** – Cross-sectional Studies, Ecologic Studies, “Outcomes” Research
- ☐ **4a** – Systematic Review of Case Control Studies
- ☐ **4b** – Individual Case Control Study
- ☐ **5** – Case Series, Case Reports
- ☐ **6** – Expert Opinion without explicit critical appraisal, Narrative Review
- ☐ **7** – Animal Research
- ☐ **8** – In Vitro Research

Strength of Recommendation Taxonomy (SORT)

	A – Consistent, good quality patient oriented evidence
<input type="checkbox"/>	B – Inconsistent or limited quality patient oriented evidence
<input type="checkbox"/>	C – Consensus, disease oriented evidence, usual practice, expert opinion, or case series for studies of diagnosis, treatment, prevention, or screening

Conclusions: D3

How does the evidence apply to this patient?

- This patient has periodontitis, and that leads to a higher risk of peri-implantitis from the literature. Placing new implants or loading current implants could be a poor decision due to the higher risk of failure or complications.

Based on the above considerations, how will you advise your D4?

- Prior to performing any treatment on the restoration or placement of implants, I would focus on increasing OHI and patient compliance to get a healthier mouth. I would also perform an SRP to help curb the periodontitis. If oral health/the periodontitis improves then I would look at placing/restoring the implants.

Conclusions: D4

Advise patient:

- Improve oral hygiene to avoid complications of peri-implantitis
- Extraction of hopeless teeth

Help to patient:

- 3-4 month recalls after completion of SRP
- Review of oral hygiene instruction at all appointments
- Set goals with patient for improvement in at home hygiene



Discussion Questions



THANK YOU