

Rounds Case

Evidence Based Dentistry Rounds Prosthodontics

Group 10

Team B-4

10/21/2020

Rounds Team

- **Group Leader:** Dr. Yray
- **Specialty Leader:** Dr. Velasquez
- **Project Team Leader:** Christopher Flood
- **Project Team Participants:** Benjamin Gutschow; Samuel Chen; Nikita Tongas

Patient

- 69 year old white male
- Presents to MUSoD Advanced Care Clinic for emergency treatment
- **CC:** "There is pain on the right side of my mouth and now it continues toward the front teeth. There has been a swelling on the right side before too."
- **HxCC:** Pain for about 1 year. Hydrogen peroxide, aspirin, codeine, and amoxicillin for the pain and swelling

Medical History

- Medical Conditions:
 - High blood pressure
 - Arrhythmia (irregular heart beat)
 - Asthma
 - Emphysema/COPD
 - Sleep apnea
 - Snoring
 - Type 2 diabetes
 - Frequent urination
 - Feelings of anxiety
 - Osteoarthritis
 - Vision problems
 - Hearing impairment

Medical History

- Medications:
 - acetylcysteine
 - acridinium bromide
 - albuterol sulfate
 - blood sugar diagnostic
 - brinzolamide-brimonidine
 - diclofenac sodium
 - dofetilide
 - dorzolamide-timolol (PF)
 - fluticasone-umeclidin-vilanter
 - furosemide

Medical History

- Medications:
 - gabapentin
 - insulin glargine
 - ipratropium-albuterol
 - isosorbide dinitrate
 - lancets
 - latanoprost
 - lisinopril
 - metoprolol succinate
 - montelukast
 - nitroglycerin

Medical History

- Medications:
 - oxybutynin chloride
 - pen needle diabetic
 - potassium chloride
 - ramelteon
 - sertraline
 - simvastatin
 - tamsulosin
 - tizanidine
 - tramadol
 - varenicline
 - warfarin

Medical History

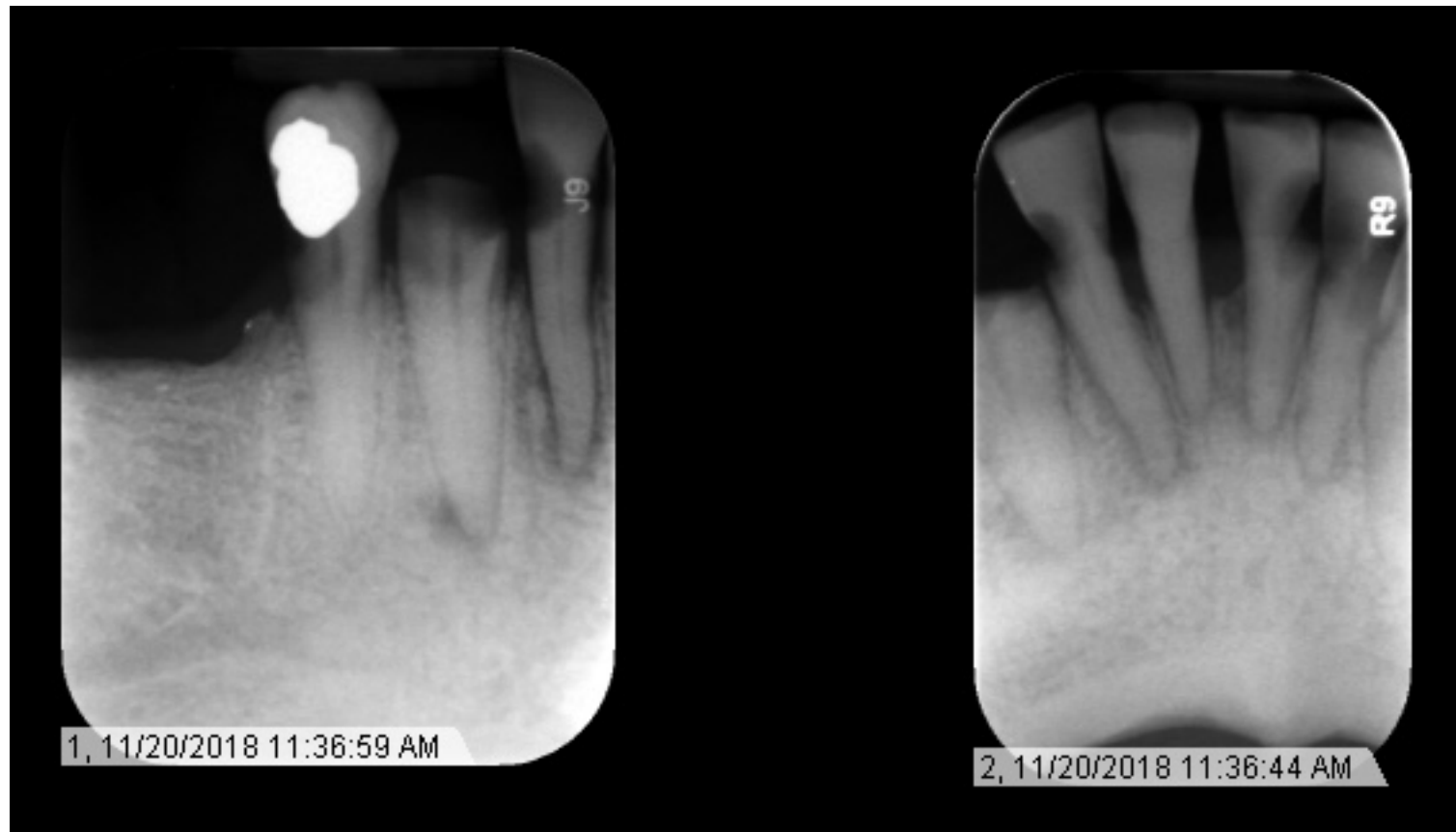- General Medical Information:
 - Sees general physician
 - Past smoker ~5 cigarettes/day
 - Metal plates in both his neck and foot
- Allergies:
 - NKDA

Dental History

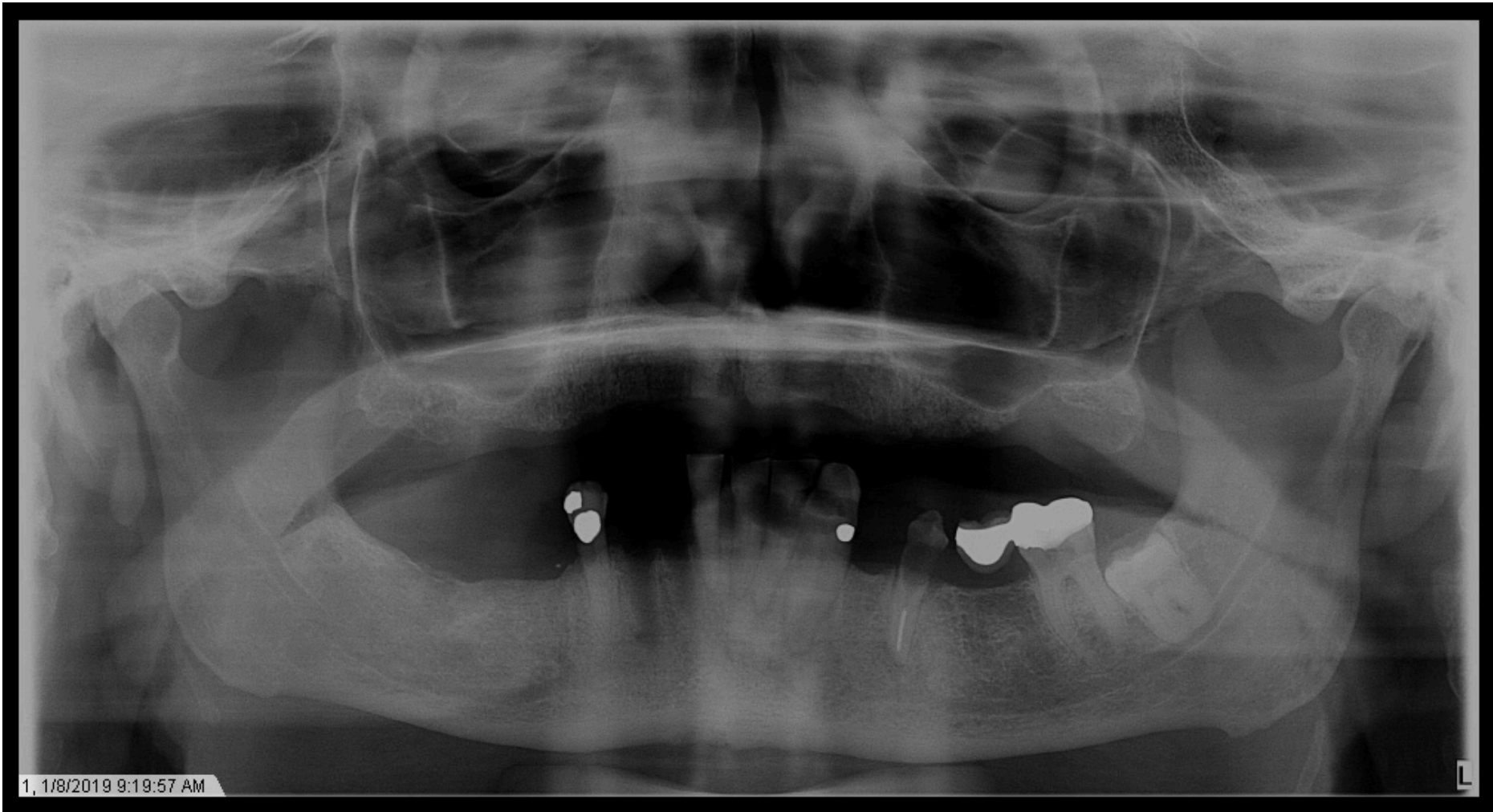
- Has had previous dental treatment
 - Extractions, dentures, root canal therapy
- Sensitivity to cold and pressure
- Trouble chewing
- Loose teeth
- Headaches, earaches, neck pains
- TMJ clicking and popping
- Serious injury to head or mouth
- Unhappy with the appearance of his teeth
- Does not brush or floss

Radiographs

- Advanced Care Clinic: #26 and #27 EXT



Radiographs



Radiographic Findings

- #17 impacted
- #22 root canal therapy
- Generalized gross caries

Clinical Findings

- #18 FCC FPD with cantilever PFM pontic (#19)
- #22 F amalgam
- #22 DL resin
- #28 DOB amalgam
- Generalized gross caries

Periodontal Charting

																MOBILITY
																FURCA
																PLAQUE
																BOP
																MGJ
																CAL
																P.D.
																FGM
1	2	3	4	5	6	7	8	9	10	11	12	13	14	15	16	
																FGM
																P.D.
																CAL
																MGJ
																BOP
																PLAQUE
																FURCA
																PROGNOSI
																PROGNOSI
																FURCA
																PLAQUE
								B B B		B B B			B B B	B B B		BOP
				7 7 7			5 5	5 5 5		5 5 5		5 5 5	5 5 5	5 5 5		MGJ
				5 5 5			7 8 8	7 6 7		4 3 3		2 2 5	0 0 0	5 4 5		CAL
				2 2 2			2 3 3	3 2 3		3 2 2		2 2 5		3 2 3		P.D.
				3 3 3			5 5 5	4 4 4		1 1 1		0 0 0	0 0 0	2 2 2		FGM
32	31	30	29	28	27	26	25	24	23	22	21	20	19	18	17	
				3 3 2			5 5 2	2 3 2		1 3 1		1 4 1	0 0 0	0 0 0		FGM
				2 3 2			2 2 4	3 3 3		3 3 3		2 2 4		4 3 4		P.D.
				5 6 4			7 7 6	5 6 5		4 6 4		3 6 5	0 0 0	4 3 4		CAL
				5 5 5			5 5 5	5 5 5		5 5 5		5 5 5	5 5 5	5 5 5		MGJ
													B B B	B B B		BOP
																PLAQUE
																FURCA
																MOBILITY

Periodontal Charting

													PROGNOSIS
													FURCA
													PLAQUE
					B B B		B B B			B B B	B B B		BOP
	7 7 7			5 5	5 5 5		5 5 5		5 5 5	5 5 5	5 5 5		MGJ
	5 5 5			7 8 8	7 6 7		4 3 3		2 2 5	0 0 0	5 4 5		CAL
	2 2 2			2 3 3	3 2 3		3 2 2		2 2 5		3 2 3		P.D.
	3 3 3			5 5 5	4 4 4		1 1 1		0 0 0	0 0 0	2 2 2		FGM
29	28	27	26	25	24	23	22	21	20	19	18	17	
	3 3 2			5 5 2	2 3 2		1 3 1		1 4 1	0 0 0	0 0 0		FGM
	2 3 2			2 2 4	3 3 3		3 3 3		2 2 4		4 3 4		P.D.
	5 6 4			7 7 6	5 6 5		4 6 4		3 6 5	0 0 0	4 3 4		CAL
	5 5 5			5 5 5	5 5 5		5 5 5		5 5 5	5 5 5	5 5 5		MGJ
										B B B	B B B		BOP
													PLAQUE
													FURCA
													MOBILITY

Diagnosis

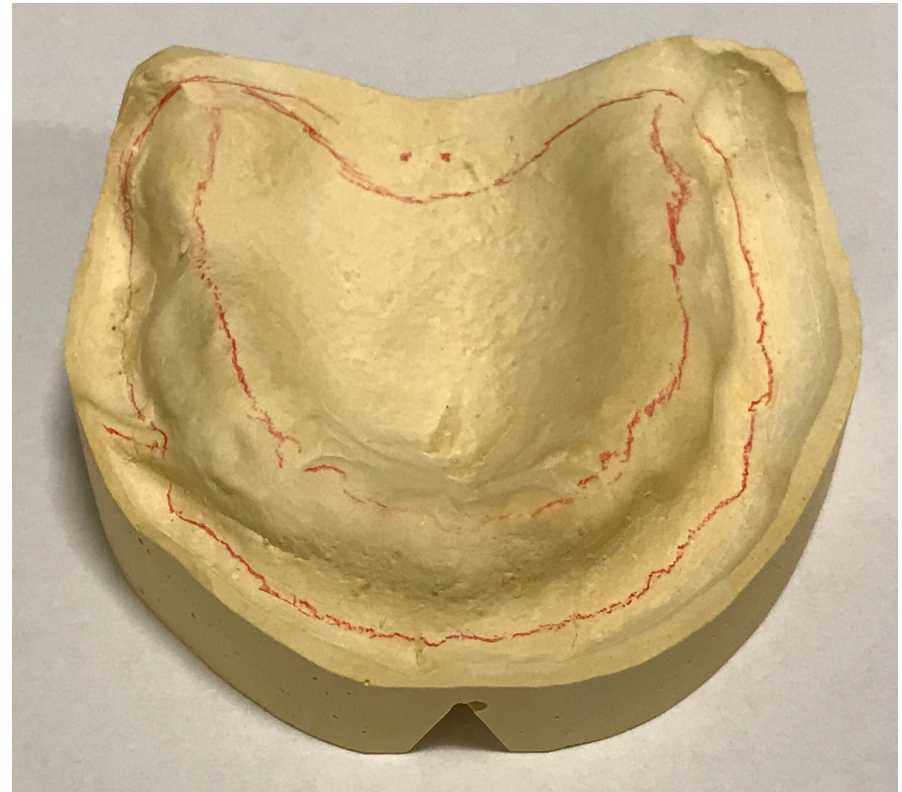
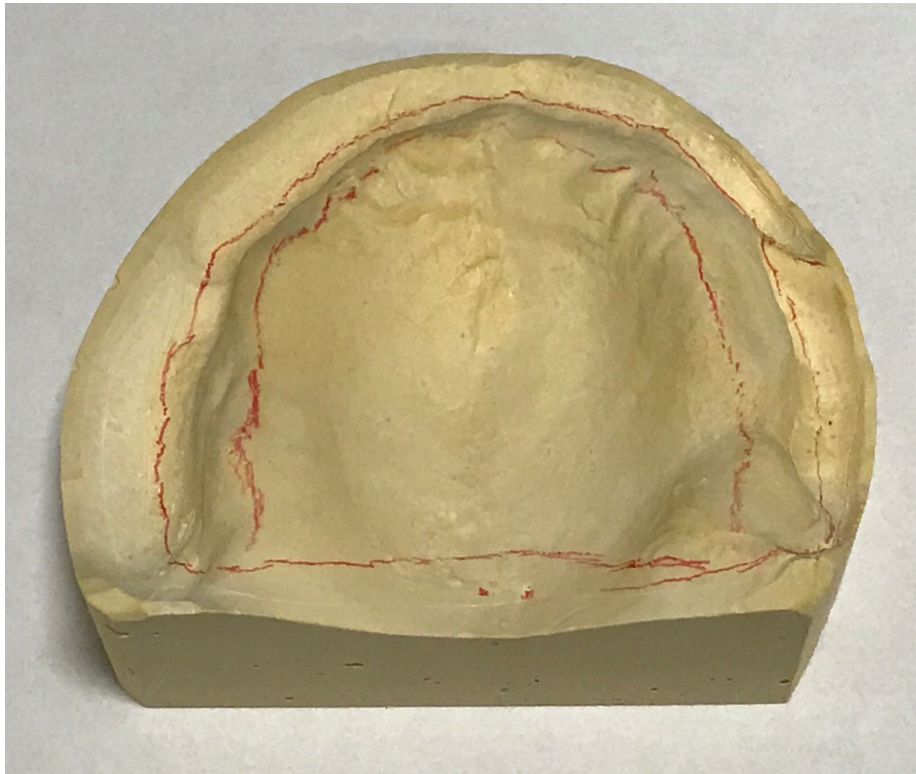
- Non-salvageable dentition
- Depleted dentition
- Non-restorable caries
- AAP
 - Generalized moderate chronic periodontitis
- ADA
 - IV – Advanced chronic periodontitis

Previous Student

- #18, #19, and #20 EXT

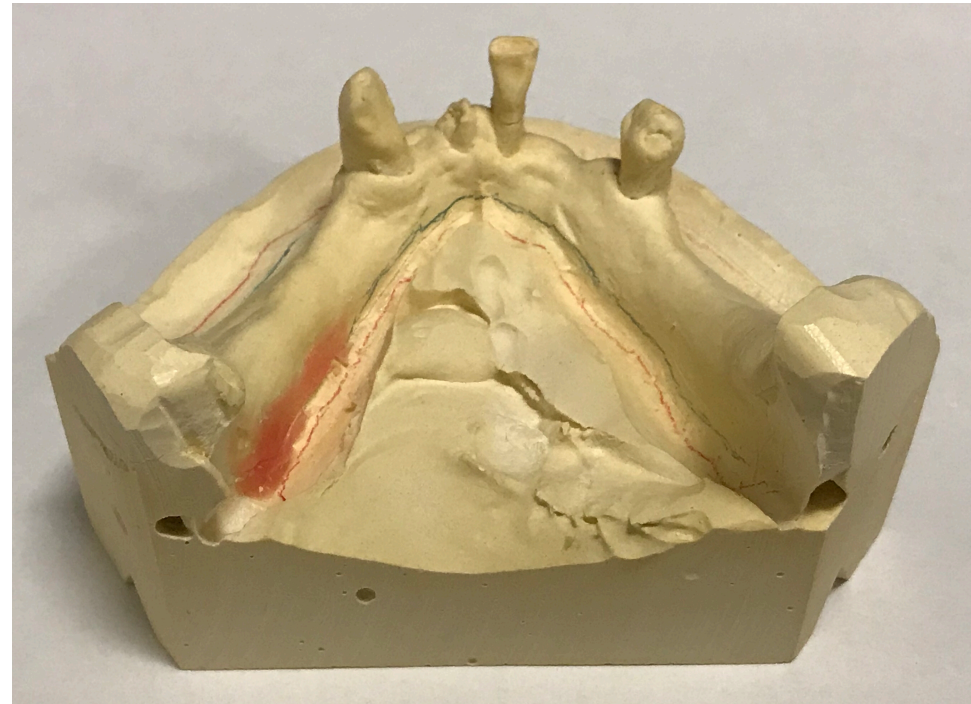
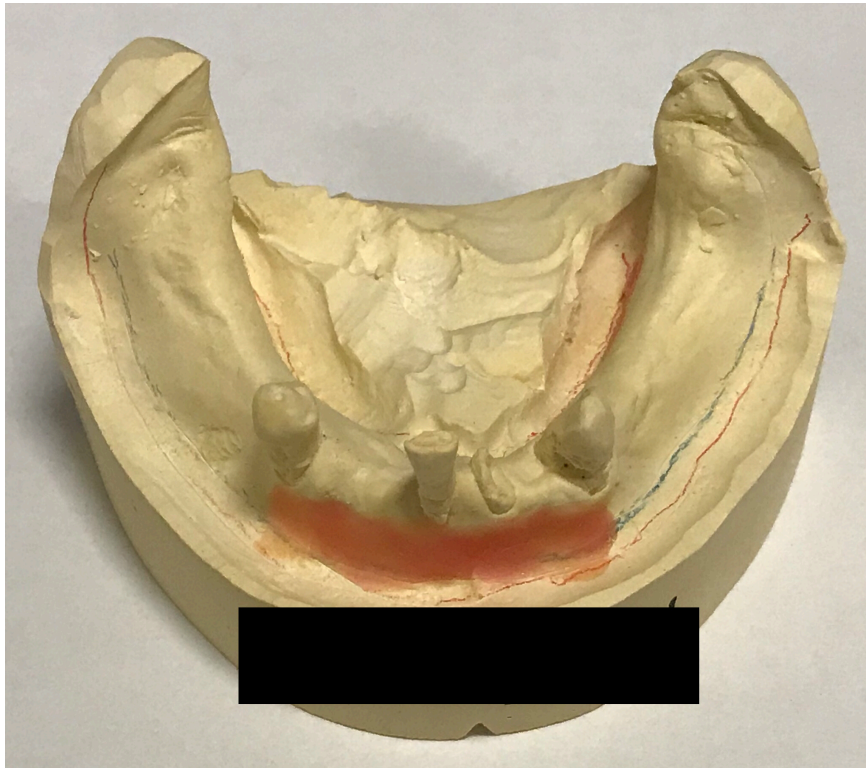Casts

- Maxilla



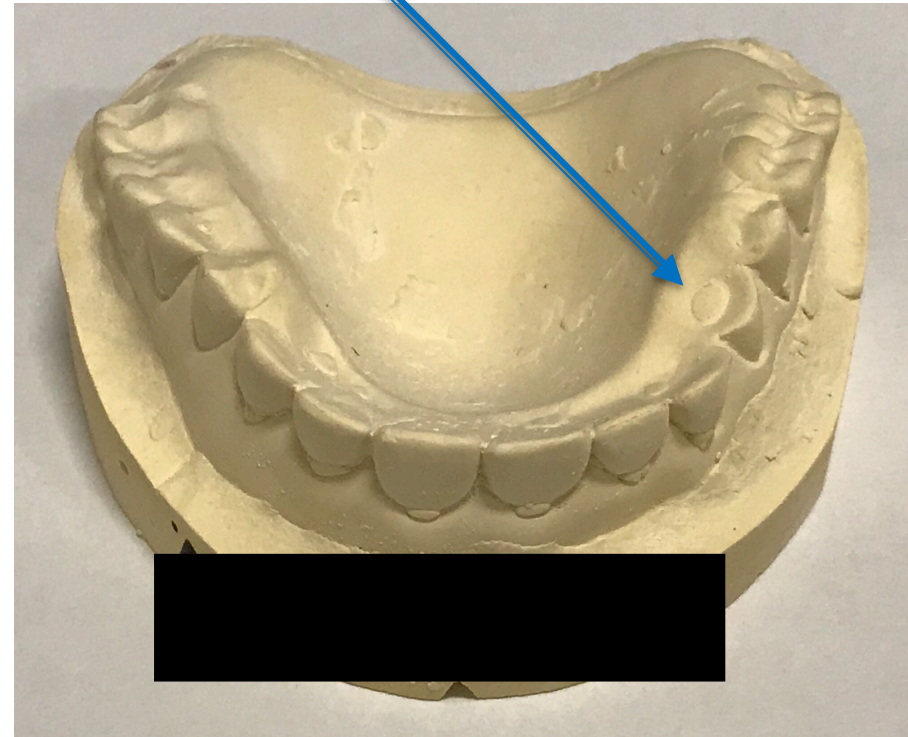
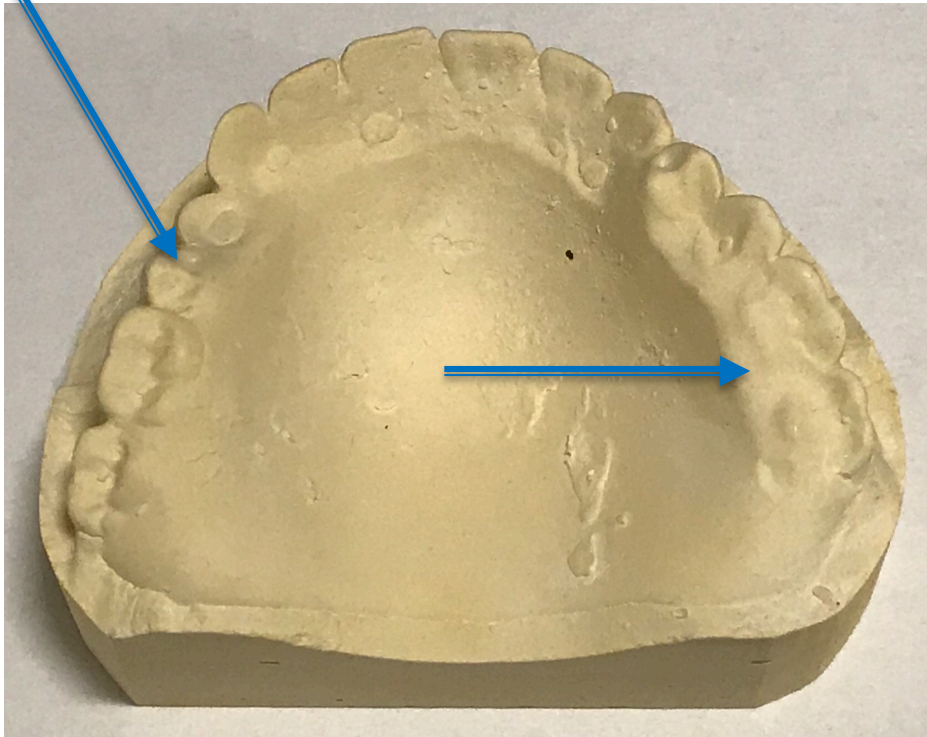
Casts

- Mandible



Worn Denture

- Maxilla



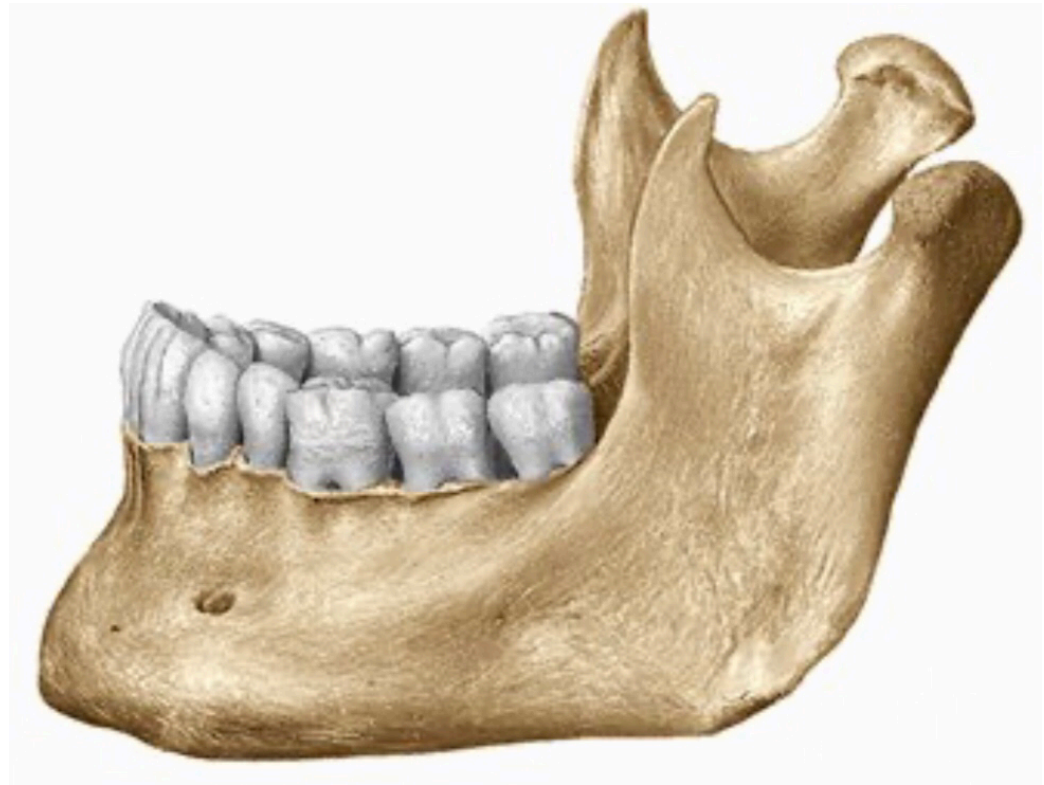
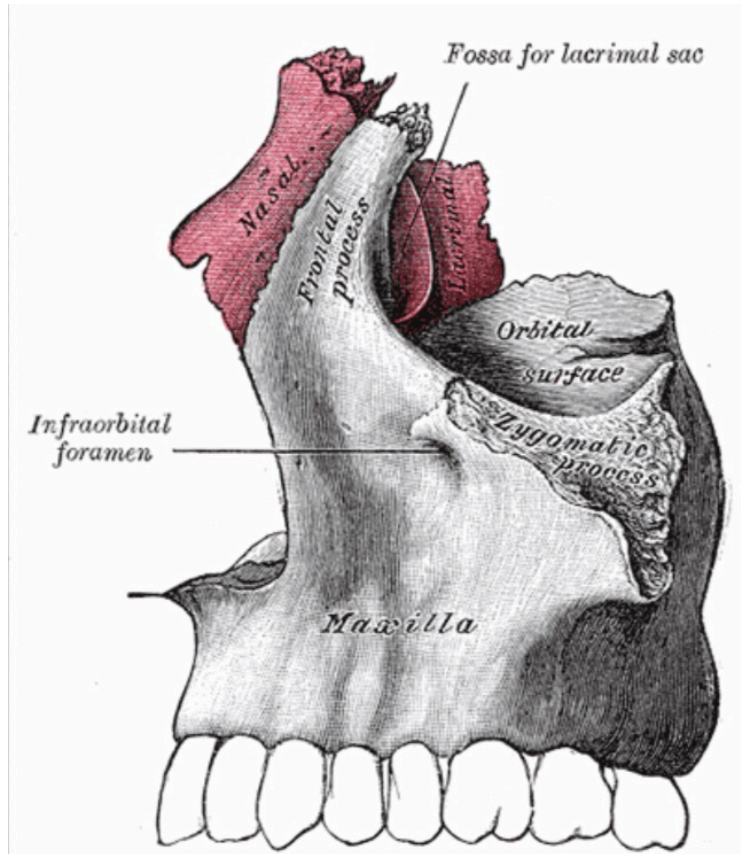
Problem List

- Gross caries
- Existing dentures are defective
- Esthetics
- Fractured tooth
- Home care
- Missing teeth
- Mobile teeth
- Perio disease
- Sensitivity

D1 Basic Science

- What is the alveolar ridge and how does it change after extractions?

Alveolar Ridge



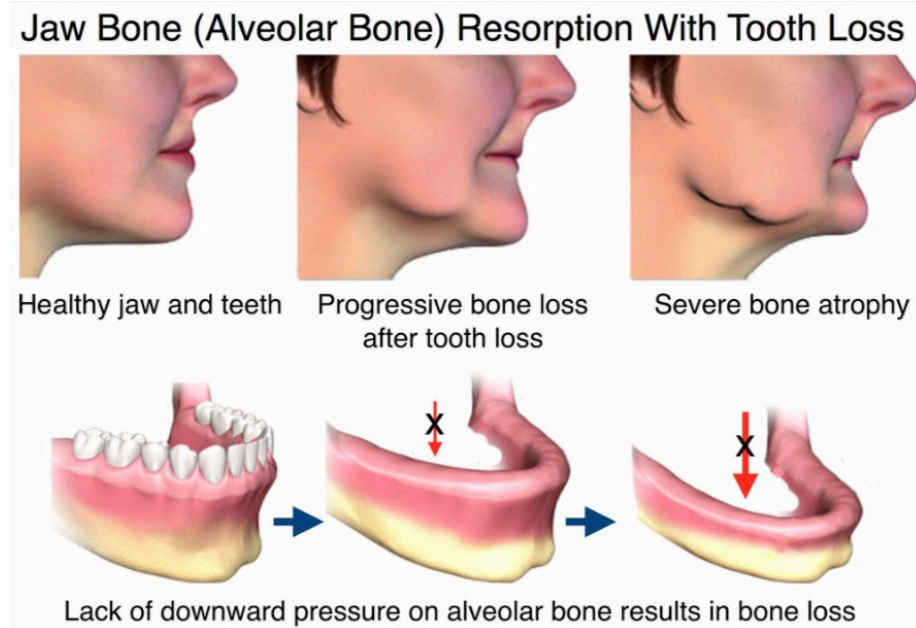
Alveolar Ridge Components

- Tooth stability/contains tooth sockets
- Two cortical plates
 - Compact bone
 - Lamina dura lines socket
- Inner bone
 - Cancellous bone



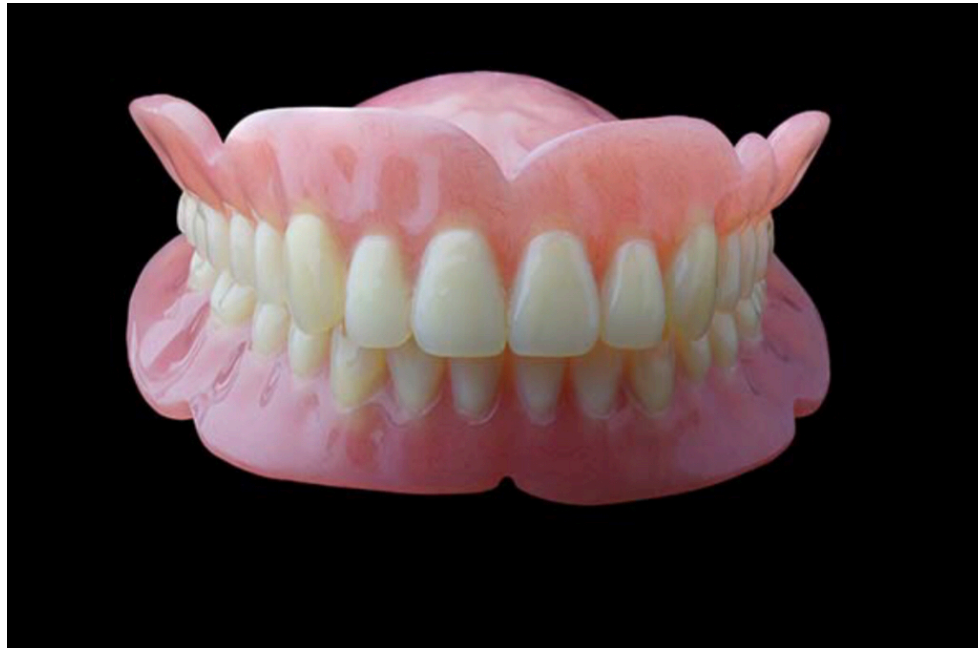Extraction and Resorption

- Tooth extraction = loss of physical stress
 - Mastication
 - Daily function
- Osteoclasts
 - Demineralization
 - Calcium and phosphate released into blood
 - 30-60% of original bone structure lost



D2 Pathology

- How does the immediate placement of a removable prosthesis affect the healing of extraction sites?



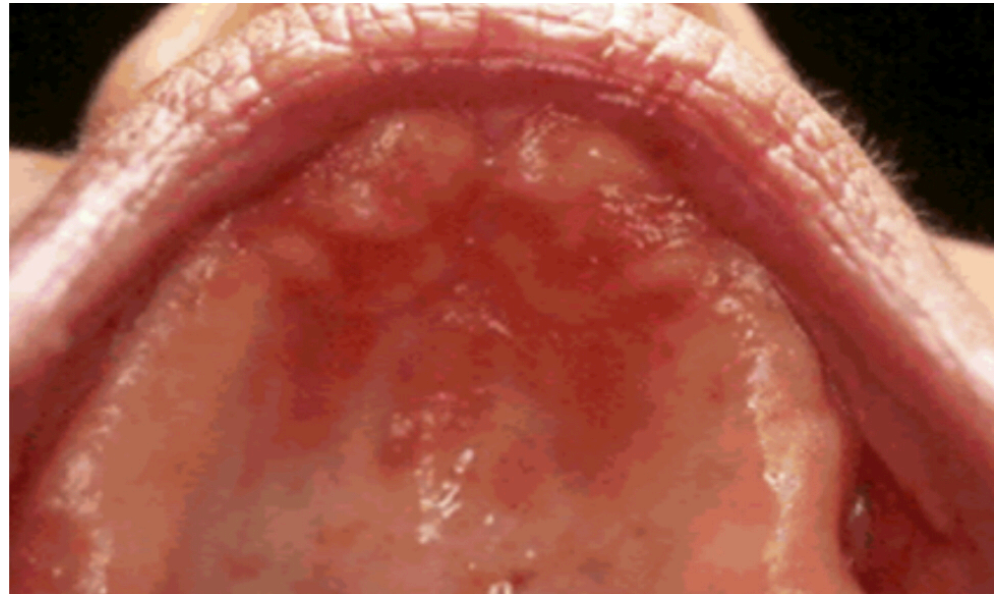
Immediate Denture Effects on Extraction Site Healing

- **Benefits**

- Tissue protection
- Clot stabilization
- Reduced sensitivity

- **Drawbacks**

- Improper hygiene
 - Denture stomatitis
- Poor realignment
 - Ulceration/irritation



D3 PICO

- **Clinical Question:** *Should I deliver a removable prosthesis immediately following my patient's edentulation?*

PICO Format



P: *Denture-seeking patients who still need extractions*

I: *Immediate placement of a complete denture*

C: *Placement of a complete denture after healing*

O: *Patient Satisfaction*

PICO Formatted Question

- In denture-seeking patients who still need extractions, how does the immediate placement of a complete denture compare to the placement of a completed denture after healing in regards to patient satisfaction?

Clinical Bottom Line

- According to an Individual Cohort Study and various Clinical Case Reports, patient satisfaction with denture treatment is significantly influenced by their expectations prior to treatment. As a result, this is a difficult topic to determine the “best” treatment for patient satisfaction. If the provider can adequately inform the patient and they are well prepared for the difficulties surrounding the transition to dentures, then they are likely to be more satisfied with the quality of their dentures, regardless if they wait for healing or proceed with an interim denture.

Search Background

- **Date of Search:** 10/18/2020
- **Database(s) Used:** PubMed.gov; Google Scholar
- **Search Strategy/Keywords:** Complete Denture, Edentulation, Patient Satisfaction, Tooth Extraction, Residual Ridge Resorption, Expectations
- **Mesh Terms Used:** Complete Denture AND Tooth Extraction NOT Dental Implant

Article 1

- Marachlioglou, Carlos Ricardo Martins Zeitune, et al. "Expectations and final evaluation of complete dentures by patients, dentist and dental technician." *Journal of oral rehabilitation* 37.7 (2010): 518-524.
- **Study Design:** *Individual Cohort Study (2b)*
- **Reason for Selection:** *Addresses patient satisfaction aspect of PICO question*

Article 1 Synopsis

- Before and after treatment, patients had higher expectations for aesthetics and function of their complete dentures than both the dentist and dental technician evaluating the case.
 - Dental professionals are more aware of potential limitations and complications after completing an initial examination
- Significant variation between dentist and patient regarding the expected outcome of complete denture treatment.
 - Perception of dentist / prior dental experiences influenced how satisfied patients were with treatment.

Article 1 Results

Table 1. Comparison of baseline (expectations) and post-treatment completion ratings for aesthetics and function per raters ($n = 20$)

	Dentist				Patients				Technician			
	Expectations		Post-treatment completion rating		Expectations		Post-treatment completion rating		Expectations		Post-treatment completion rating	
	Aesthetic	Function	Aesthetic	Function	Aesthetic	Function	Aesthetic	Function	Aesthetic	Function	Aesthetic	Function
Average	7.70	7.00	8.88	8.33	9.60	9.30	9.45	9.00	8.95	8.65	8.85	8.50
Median	8	7	9	9	10	10	10	10	9	9	9	9
Standard deviation	1.30	1.38	1.28	1.05	0.82	1.22	1.36	1.59	0.69	1.04	1.18	1.32
Confidence interval	0.57	0.60	0.56	0.46	0.36	0.53	0.59	0.70	0.30	0.46	0.52	0.58
<i>P (Aesthetic)</i>	0.017*				0.886				0.773			
<i>P (Function)</i>	0.003*				0.334				0.623			

Article 2

- Fitzpatrick, Brian. "Standard of care for the edentulous mandible: a systematic review." The Journal of prosthetic dentistry 95.1 (2006): 71-78.
- **Study Design:** Systematic Review
- **Reason for Selection:** *Compares treatment options for denture seeking patients*

Article 2 Synopsis

- 244 articles identified, 39 selected for review
 - 7 randomized control trials, 32 clinical trials
- While there is not a consensus standard of care for the edentulous mandible, an implant supported overdenture (with 2 implants) has shown the greatest combination of patient and dentist satisfaction
 - Also the most expensive option
- Prior experiences as well as patient expectation proved to have the biggest impact on patient satisfaction with treatment for edentulation.

Article 3

- Critchlow, Simon B., and Janice S. Ellis. "Prognostic indicators for conventional complete denture therapy: a review of the literature." *Journal of dentistry* 38.1 (2010): 2-9.
- **Study Design:** *Narrative Review*
- **Reason for Selection:** *Discusses different factors influencing complete denture therapy*

Article 3 Synopsis

- 33 articles were reviewed
 - 3 RCTs, 19 clinical experimental studies, 7 non-experimental clinical studies, 4 review papers.
- Varying results in patient satisfaction for potential prognostic indicators of: Age, Demographics, Psychological factors, Expectations / Attitudes, Residual Ridge Form / Anatomy, Dentist-Patient Relations
- Patients who had been edentulous for the least amount of time expressed lower satisfaction levels in comparison to patients who had been edentulous for longer.

Levels of Evidence

- ☒ **1a** – Clinical Practice Guideline, Meta-Analysis, Systematic Review of Randomized Control Trials (RCTs)
- ☐ **1b** – Individual RCT
- ☐ **2a** – Systematic Review of Cohort Studies
- ☒ **2b** – Individual Cohort Study
- ☐ **3** – Cross-sectional Studies, Ecologic Studies, “Outcomes” Research
- ☐ **4a** – Systematic Review of Case Control Studies
- ☐ **4b** – Individual Case Control Study
- ☐ **5** – Case Series, Case Reports
- ☒ **6** – Expert Opinion without explicit critical appraisal, Narrative Review
- ☐ **7** – Animal Research
- ☐ **8** – In Vitro Research

Strength of Recommendation

Taxonomy (SORT)

<input type="checkbox"/>	A – Consistent, good quality patient oriented evidence
<input checked="" type="checkbox"/>	B – Inconsistent or limited quality patient oriented evidence
<input type="checkbox"/>	C – Consensus, disease oriented evidence, usual practice, expert opinion, or case series for studies of diagnosis, treatment, prevention, or screening

Conclusions: D3

- Although there is limited quality patient-oriented evidence comparing patient satisfaction with the timing of delivery for complete dentures in relation to last tooth extractions, there are plenty of quality publications that can be pieced together to form a bigger picture. When focusing on patient satisfaction, the most important aspect of delivering dentures is preparing the patient mentally and managing their expectations. If a patient expects to restore an unreasonable amount of function, they will be greatly disappointed. At the end of the day, it is better to undersell the function of dentures so that the patients might be pleasantly surprised.

Conclusions: D4

- Be sure to manage the patient's expectations regarding dentures and their function.
- The placement of interim/immediate dentures following extractions does not contribute much to patient satisfaction in the denture process.
 - Immediate prosthesis placement may be a good idea if the patient is worried about esthetics, protecting extraction sites, chewing, practicing with prosthesis
- Make sure patient understands the denture process: interim vs. immediate, refabricate vs. reline, etc.

Discussion Questions

THANK YOU
