

# THE MAGICAL BRIDGE TO PROSTHODONTICS

EVIDENCE BASED DENTISTRY ROUNDS  
**PROSTHODONTICS**

9B-3

ZACH FINNEGAN, AMANDA WADDLE, RACHEL  
EHLERS, ALEXIS SCHROEDER

10/28/2020

# ROUNDS TEAM

- **Group Leader: Dr. Derderian**
- **Specialty Leader: Dr. Keesler**
- **Project Team Leader: D4 Zachery Finnegan**
- **Project Team Participants:**
  - **D1 - Alexis Schroeder**
  - **D2 - Rachel Ehlers**
  - **D3 - Amanda Waddle**

# PATIENT

- 1-2 slides, patient background
- Age: 41
- Gender: Female
- Ethnicity: Caucasian
- Chief Complaint: "I want to get my crowns"
- Misc. Pt Info:
  - REFUSES removable options
  - Cannot be without A tooth (posteriors included)
    - Maybe 3 weeks?

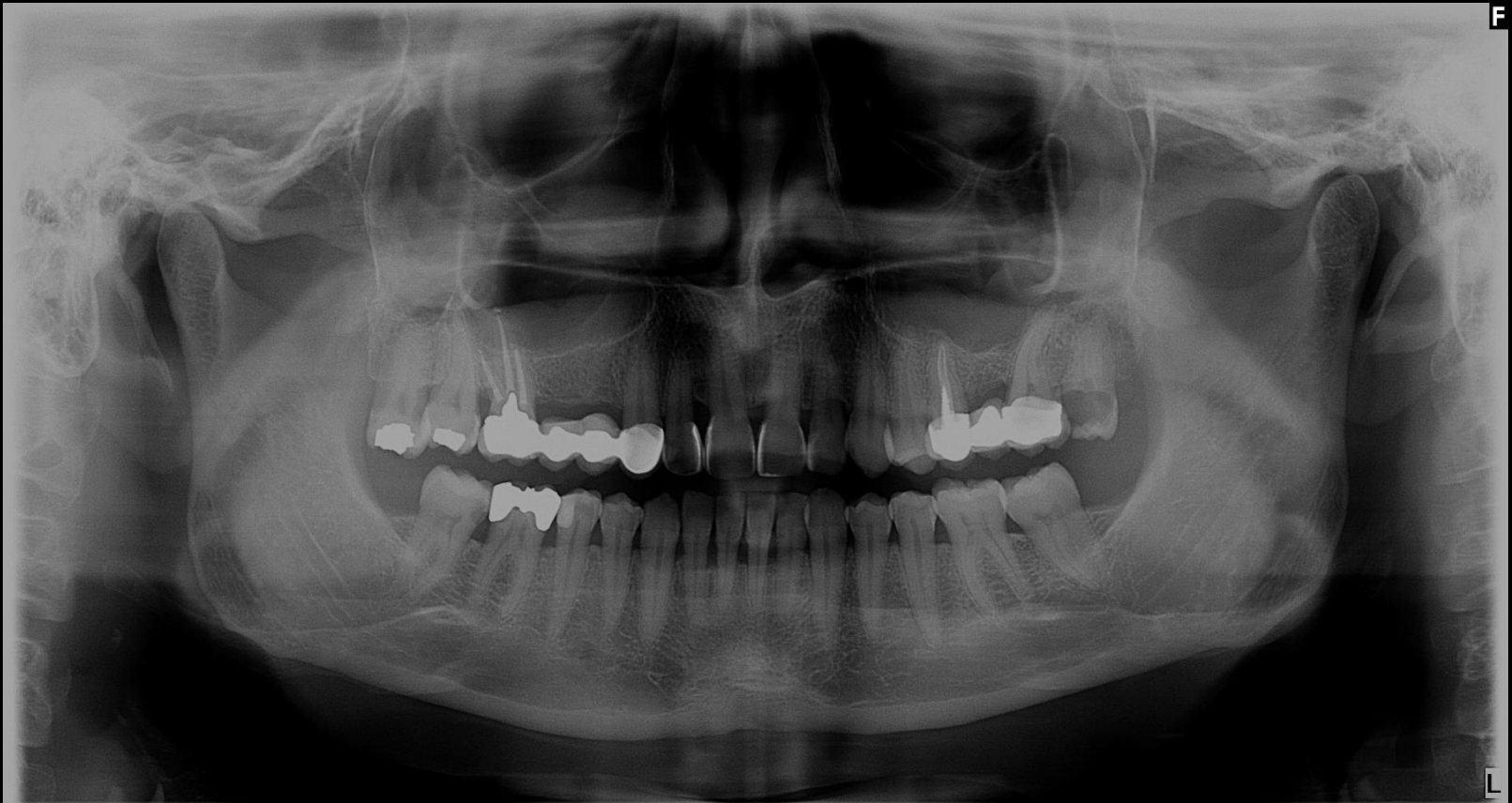# MEDICAL HISTORY

- Current & past:
  - Diagnoses: Renal failure
  - Conditions: n/a
  - Medications: none
  - Medical Consults, if any: none
- Treatment considerations:
  - Antibiotic adjustments? (GFR dependent?)
  - Caution with NSAIDs
    - Acetaminophen for dental pain

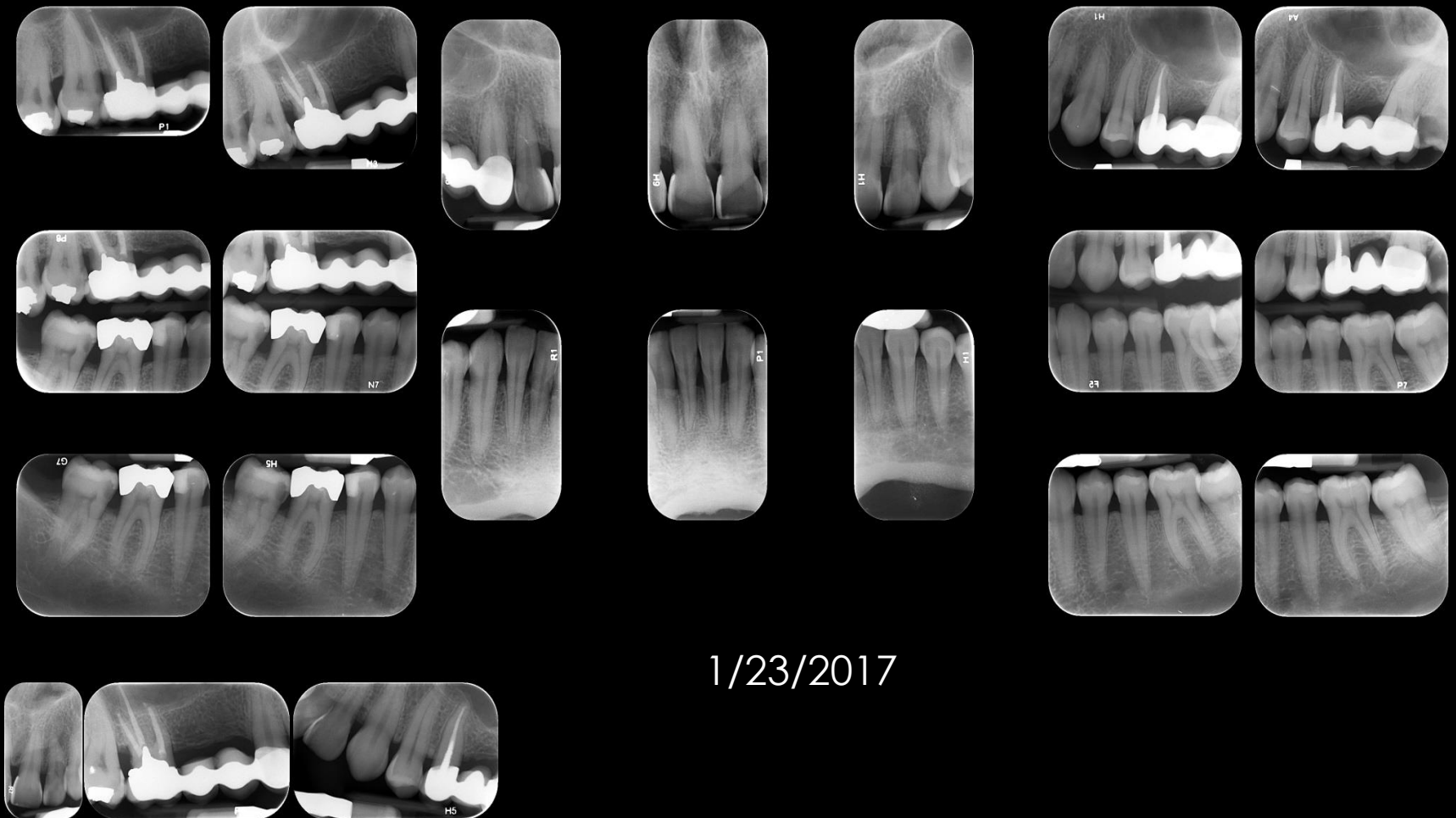# DENTAL HISTORY

- Past Perio Tx – “deeper cleanings”
- Lingual veneers on Mx anteriors (outside of the US)
- Bridges
- Root canals
- Prior to Marquette – no extractions???

# RADIOGRAPHS



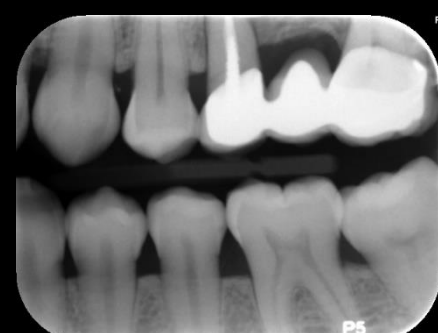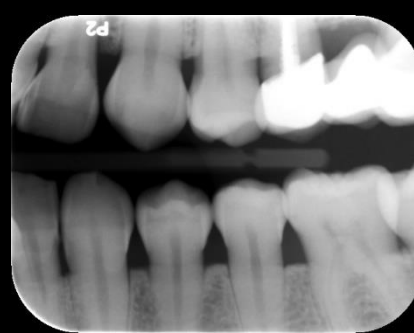
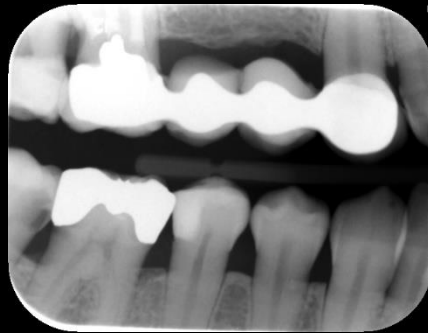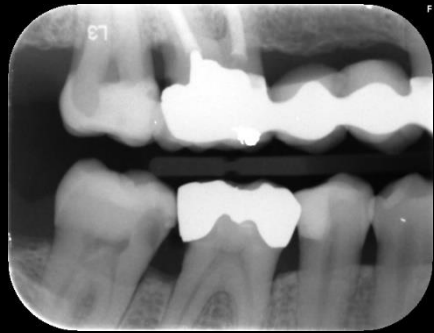# RADIOGRAPHS – LAST FMX



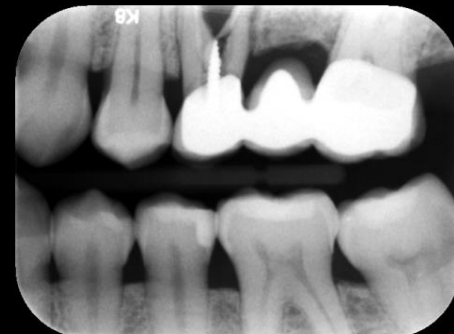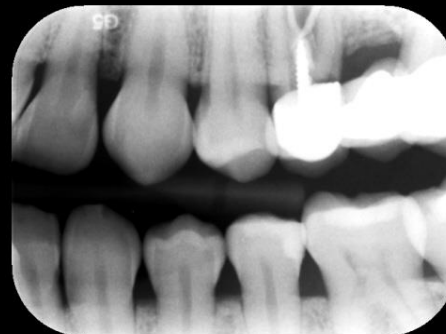
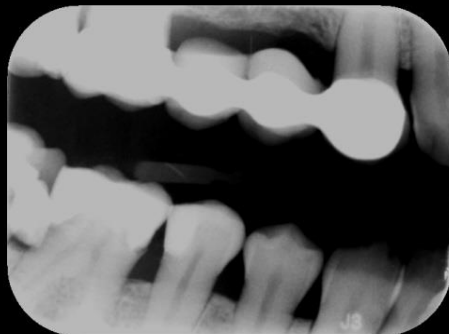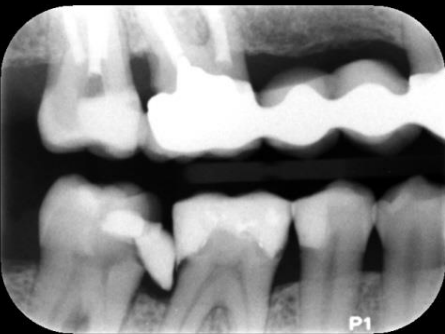1/23/2017



# RADIOGRAPHS - BWS



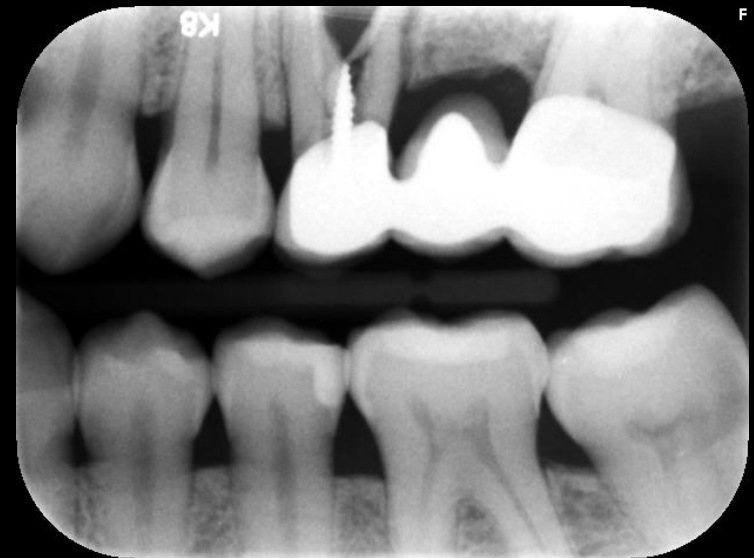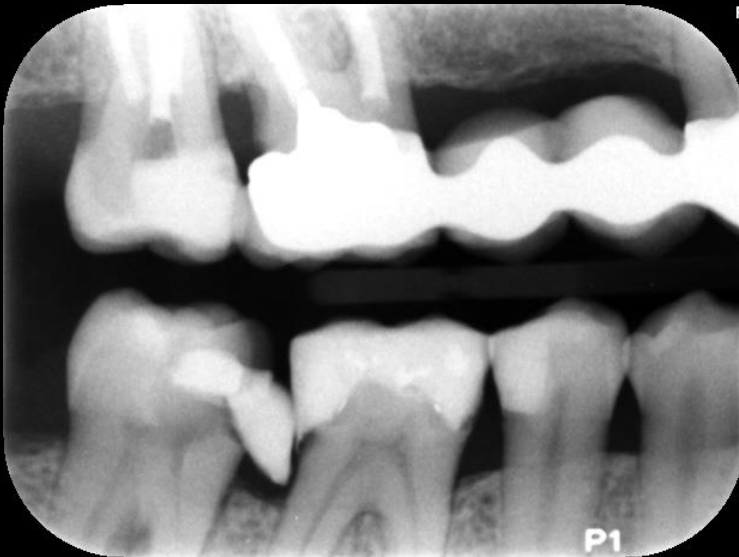10/9/2018



10/30/2019



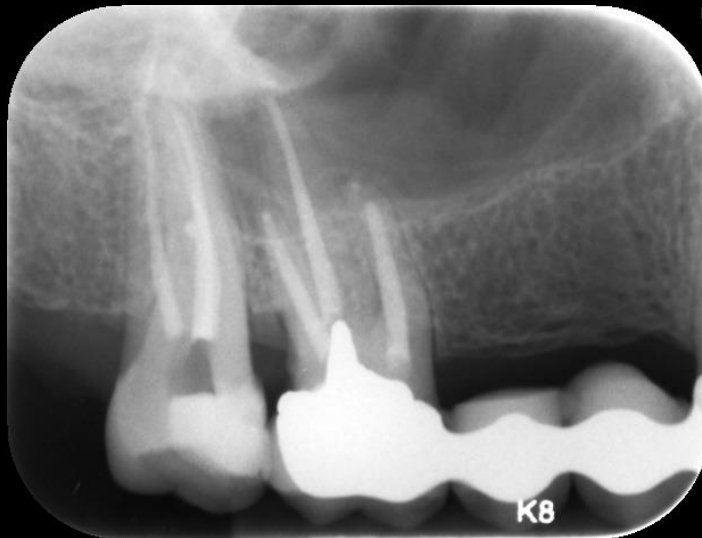
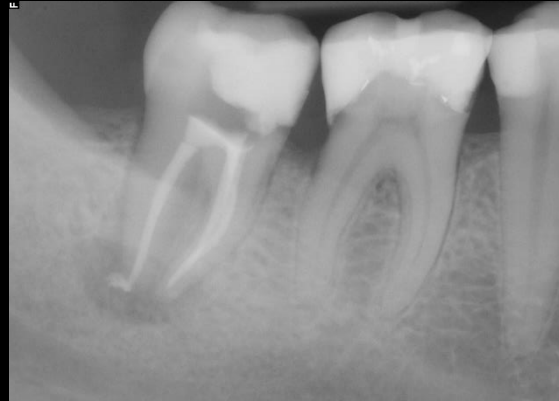# RADIOGRAPHS – RECENT BWS



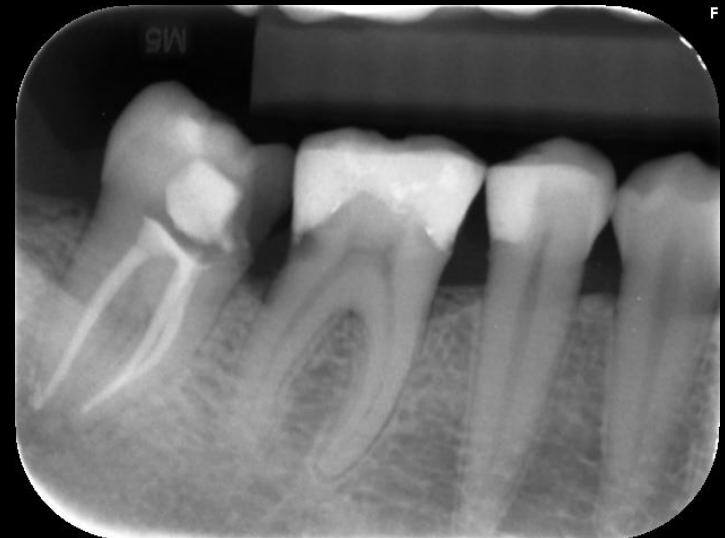10/30/2019

# RADIOGRAPHS

2/4/2020



9/9/2020



Group 9B-3

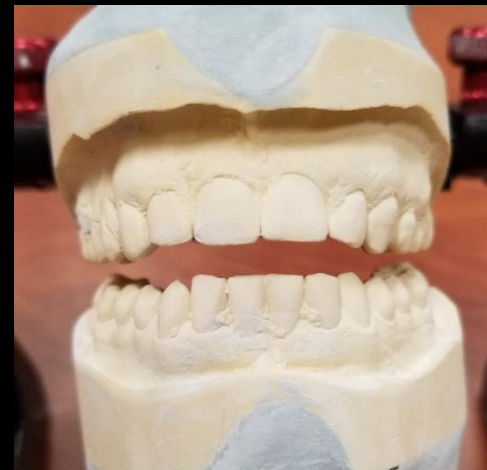
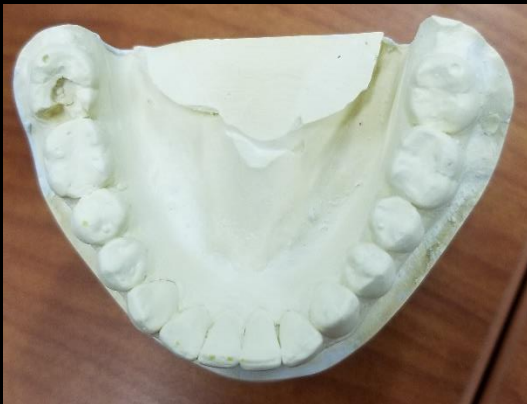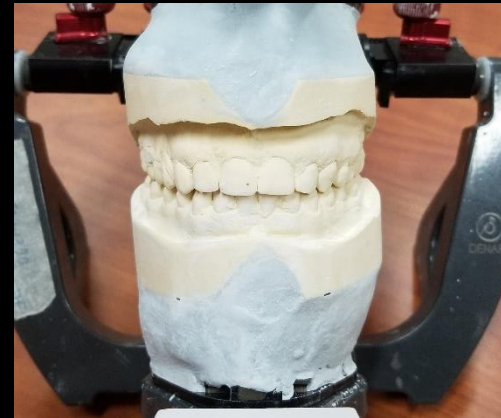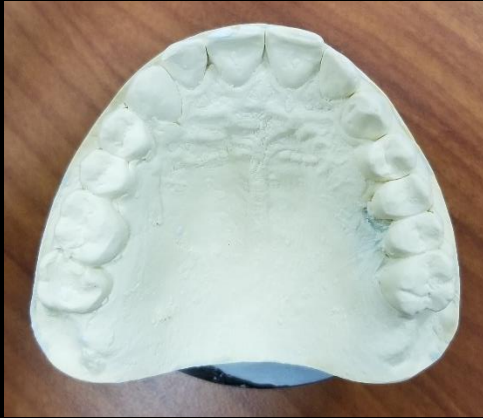# RADIOGRAPHIC FINDINGS

- Bone loss
- RCT: #2, 3, 13 (w/ tapered, threaded post), 31
- Recurrent decay D #3, 29, & #30 and M #31
- Fractured root #13,

# CLINICAL FINDINGS

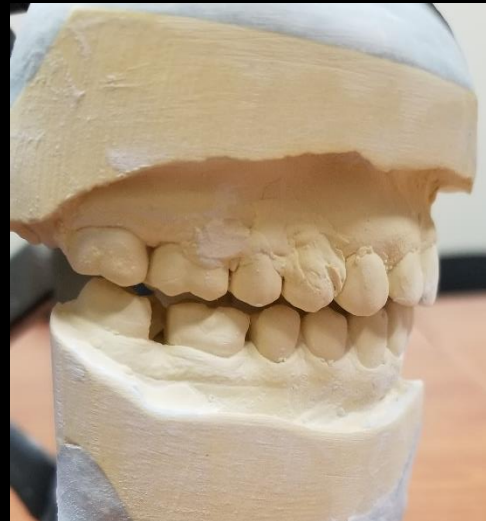
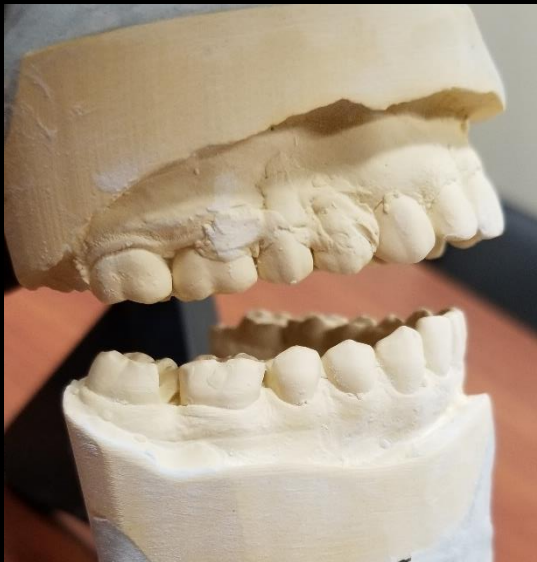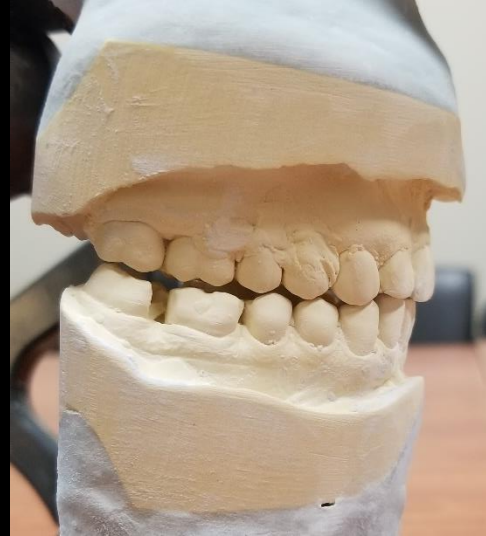
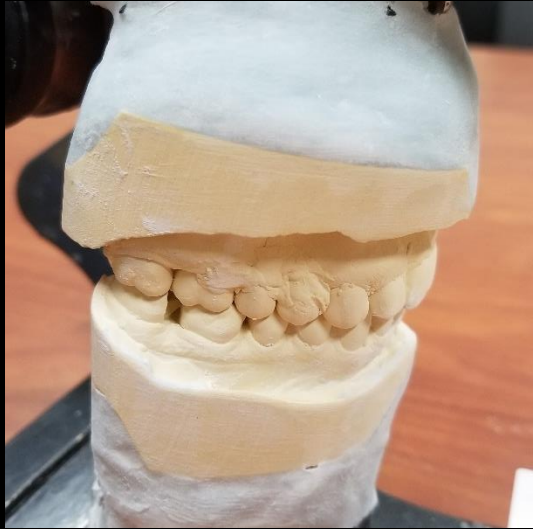- Extraoral: non-significant
- Soft Tissue: generalized BOP
- Hard Tissue:
  - Visible fracture #13
  - Temporary restorations: MO#2,31
  - Primary Caries O#18
  - Recurrent decay (D#3, O#12, D#30, MO#31)
    - #30 and 31 deemed non-restorable
  - Defective restoration #3, #15, #31

# CLINICAL FINDINGS



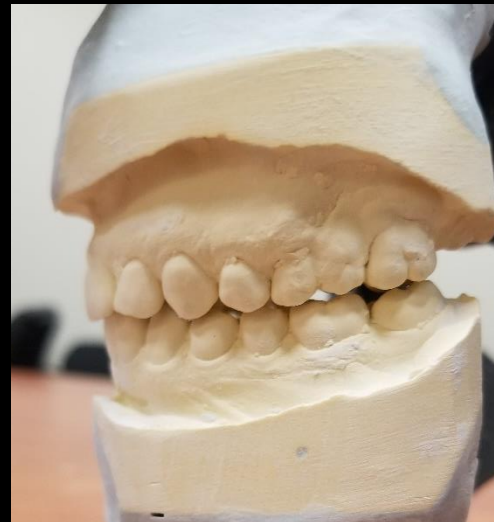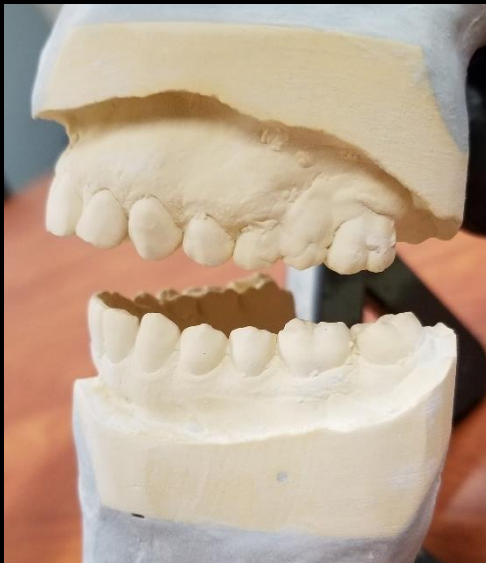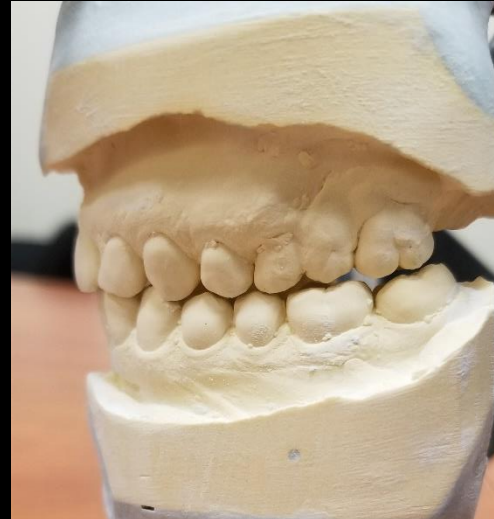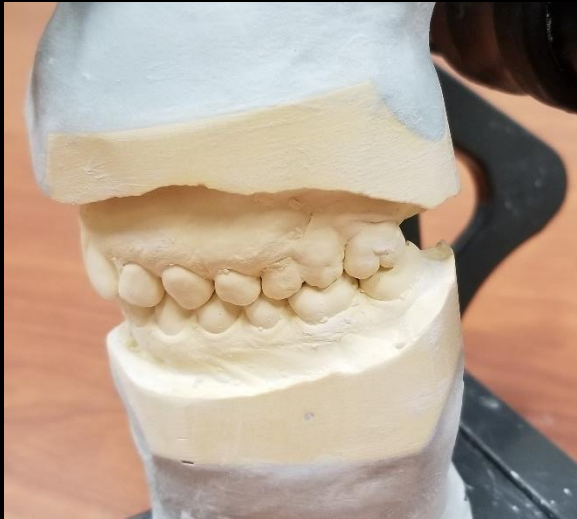


# CLINICAL FINDINGS





# CLINICAL FINDINGS



# SPECIFIC FINDINGS

- #3- recurrent decay on D
- #13- fractured
- #15- defective restoration (interference to arc of closure)

[illegible]

# DIAGNOSIS

(As pertaining to rounds discussion topic)

- ADA Class III – Moderate Chronic Periodontitis (unstable)
- Repeated recurrent caries
- #3 = recurrent decay; questionable prognosis
- #13 = RCT, symptomatic apical periodontitis, non-restorable

# PROBLEM LIST

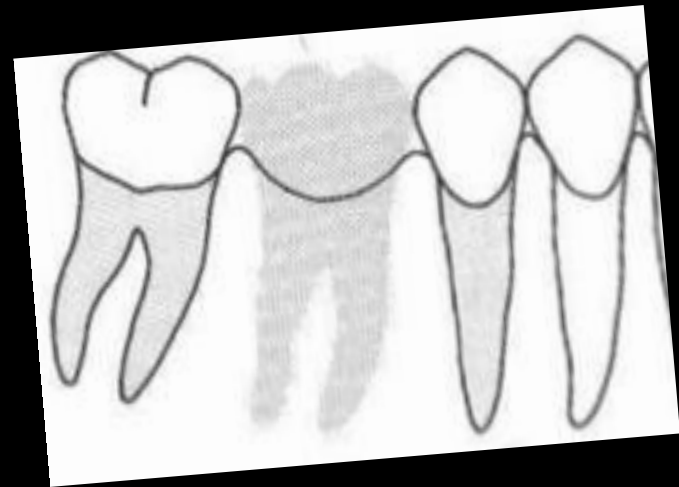
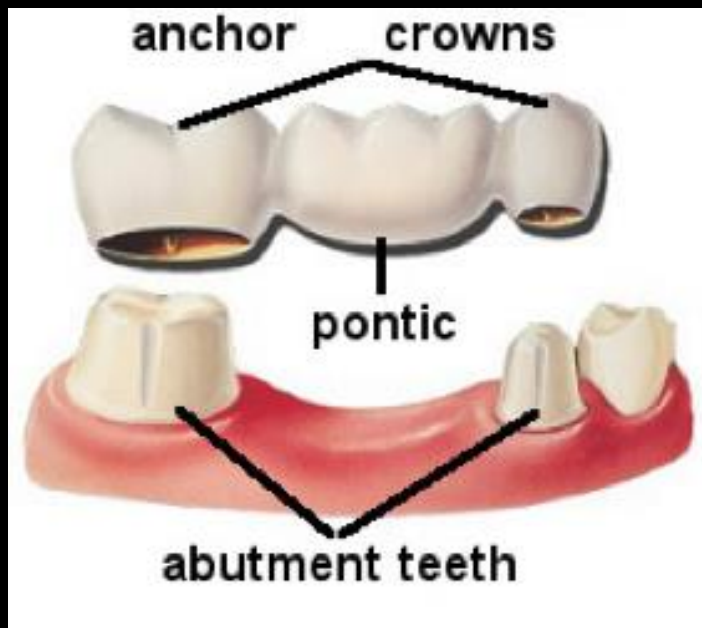
- Missing teeth
- Defective and [longstanding] temporary restorations
- Caries (primary and recurrent)
- Fractured tooth
- Periodontitis and gingival inflammation

# D1 BASIC SCIENCE

## ***D1 Question: What is Ante's Law?***

“The combined root surface area of the **abutment teeth** should equal or be greater than that of the teeth being replaced by **pontics**.”

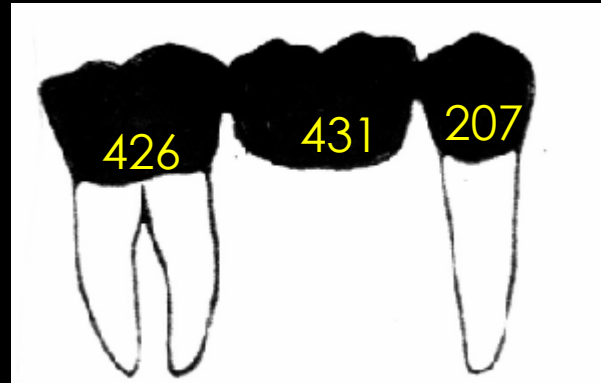
-Irwin Ante, 1926






# ANTE'S LAW

Mandibular	
Central incisor	154
Lateral incisor	168
Canine	268
First premolar	180
Second premolar	207
First molar	431
Second molar	426
Third molar	373



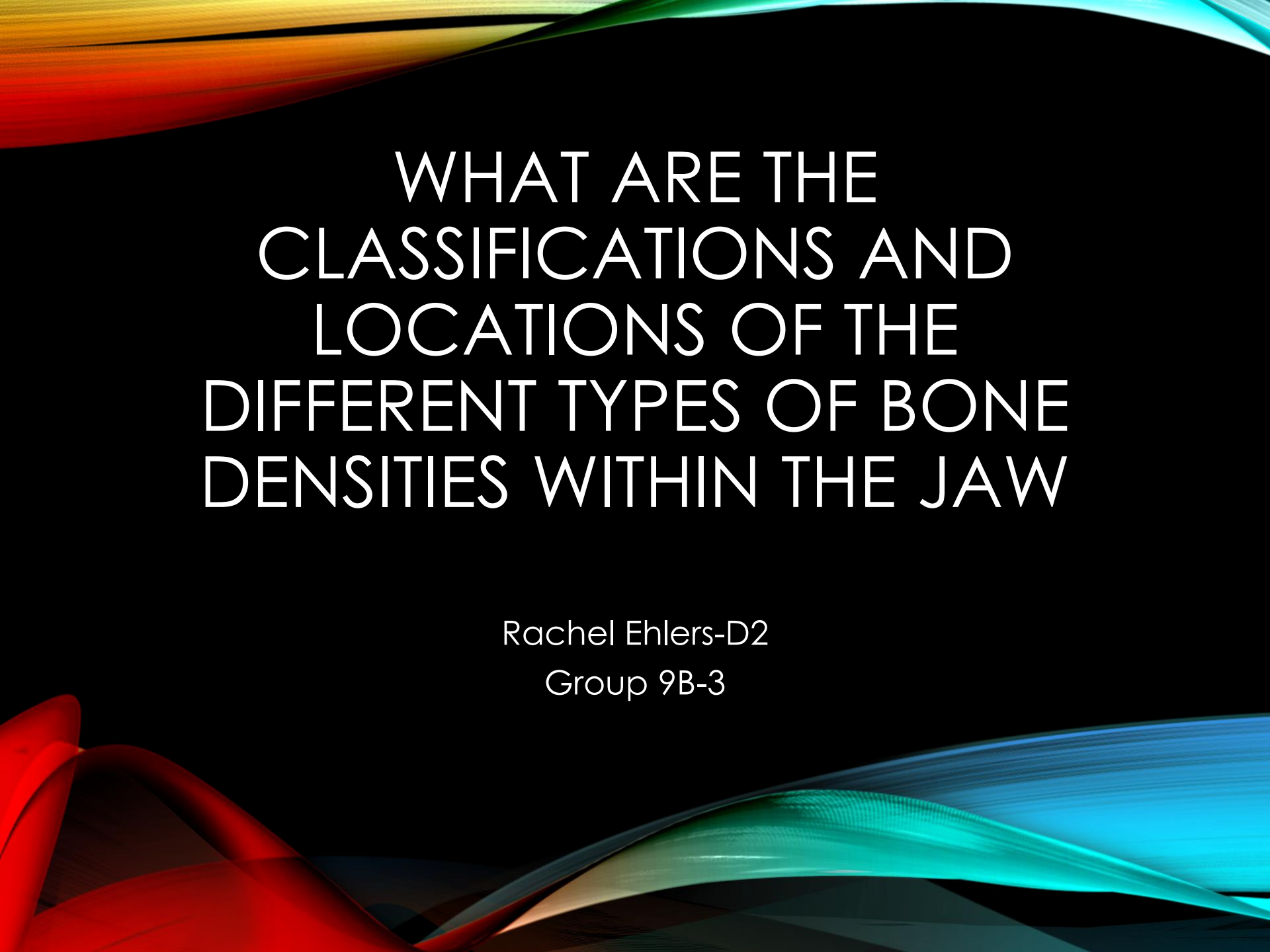
$426 + 207 = 633$   
 $633 > 431$   
 Obeys Ante's Law



$426 + 268 = 694$   
 $431 + 207 + 180 = 818$   
 $818 > 694$   
 Does NOT obey  
 Ante's Law

## References:

- Ante IH, "The Fundamental Principles of Abutments," *Mich State Dent Soc Bull*, 1926.
- Jepsen A, "Root Surface Measurement and a Method for X-ray Determination of Root Surface Area," *Acta Odontol Scand*, 1963.
- Lexicomp for Dentistry. (13, March 28). Average Root Surface Area and Fixed Prosthetic Replacements. Retrieved October 18, 2020, from <http://0-online.lexi.com.libus.csd.mu.edu/lco/action/doc/retrieve/docid/ihtcd/908997?cesid=alto6QAHG0s>



# WHAT ARE THE CLASSIFICATIONS AND LOCATIONS OF THE DIFFERENT TYPES OF BONE DENSITIES WITHIN THE JAW

Rachel Ehlers-D2

Group 9B-3

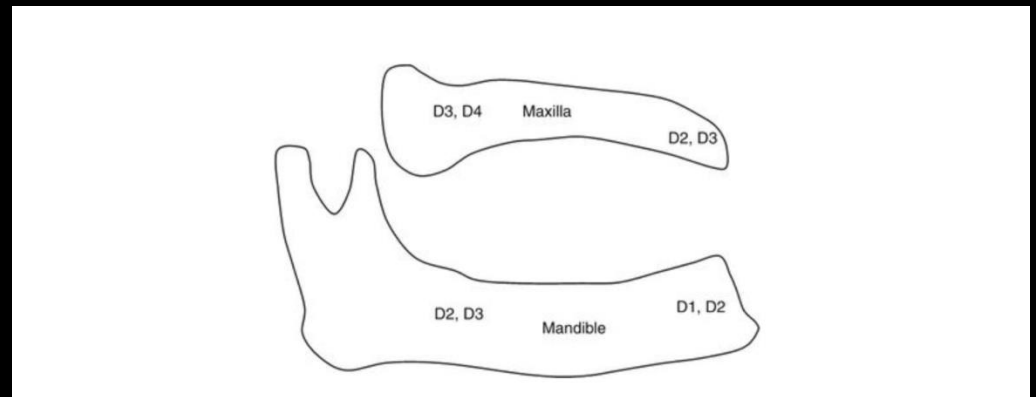
- Jaw is made up of cortical and trabecular bone
  - i. Differences seen microscopically
  - ii. Cortical bone= stiffer and more brittle
  - iii. Cortical bone= heals with little to no woven bone which yields bone strength when healing next to an implant
  - iv. Trabecular bone= sparsely located in the jaw → surgical implant challenges

<https://www.ncbi.nlm.nih.gov/pmc/articles/PMC4955555/>

[https://www.researchgate.net/publication/221917615\\_Bone\\_Quality\\_Assessment\\_for\\_Dental\\_Implants](https://www.researchgate.net/publication/221917615_Bone_Quality_Assessment_for_Dental_Implants)

# MISCH BONE DENSITY CLASSIFICATION

- D1= Homogenous, dense cortical
- D2= Thick, porous cortical with coarse trabecular
- D3= Thin, porous cortical with fine trabecular
- D4= Fine trabecular



- Trabecular bone in D4 can be up to 10x weaker than the cortical bone in D1
- Implant success is generally most predictable in D1/D2 bone (anterior mandible). D3/D4 (maxillary posterior) has the most complications/failures.
- Higher implant failure rates in posterior maxilla
- Mandible has higher implant success rate compared to maxilla- specifically posterior mandible

# D3 PICO

- **Clinical Question:**
  - What is/are the best fixed treatment options when it comes to restoring long-span edentulous areas?



# PICO FORMAT

**P: Patients with long-span edentulism**

**I: 3-unit implant-supported FDPs**

**C: 4+ unit tooth-supported FDPs**

**O: Higher long-term survival**

# PICO FORMATTED QUESTION

- In patients with long-span edentulous areas, will 3-unit implant supported fixed dental prostheses, compared with 4+ unit tooth-supported fixed dental prostheses, have increased long-term survival.

# CLINICAL BOTTOM LINE

- Recommend 3-unit implant supported FDP on patients UR, and 3-unit implant-tooth supported FDP on UL.

# SEARCH BACKGROUND

- **Date(s) of Search:** 9/19/2020, 10/18/2020, 10/19/2020
- **Database(s) Used:** Pubmed, Google Scholar
- **Search Strategy/Keywords:** Long-span, bridge, dental implant, implant-supported, tooth-supported

# SEARCH BACKGROUND

- **MESH terms used:**
  - Dental restoration failure
  - Denture, partial, fixed

# ARTICLE 1:

- Pol CWP, Raghoobar GM, Kerdijk W, Boven GC, Cune MS, Meijer HJA. A systematic review and meta-analysis of 3-unit fixed dental prostheses: Are the results of 2 abutment implants comparable to the results of 2 abutment teeth?. J Oral Rehabil. 2018;45:147–160.
- Study Design: systematic review & meta-analysis
- Study Need / Purpose: To compare the performance of 3-unit bridge on teeth with 3-unit bridges on implants, evaluating survival of the bridges, survival of the support, conditions of the hard and soft tissues surrounding the supports, complications and patient-reported outcome measures after at least 1 year.



# ARTICLE 1 SYNOPSIS

- Method
  - Literature search completed, and eligibility criteria applied, resulting in 66 articles included in the analysis, identifying 1973 3-unit FDPs supported by teeth, and 765 supported by implants.
- Results
  - No significant differences found in survival of the supporting abutments or survival of the prosthesis.
- Conclusions
  - Implant-supported 3-unit FDPs seem to be a reliable treatment with survival rates comparable to 3-unit tooth supported FDPs at 5-years.
- Limitations
  - Most studies were limited to short- or medium-term follow up; lack of long-term survival statistics.

# ARTICLE 1 SELECTION

- Reason for selection
  - Relevance to PICO (implant vs. tooth supported)
- Applicability to your patient
  - Looking at edentulous space of three adjacent teeth on upper right.
- Implications
  - Recommendation of 3-unit implant supported fixed dental prosthesis.

## ARTICLE 2:

- Manja von Stein-Lausnitz, Hans-Joachim Nickenig, Stefan Wolfart, Konrad Neumann, Axel von Stein-Lausnitz, Benedikt Christopher Spies, Florian Beuer, Survival rates and complication behaviour of tooth implant-supported, fixed dental prostheses: A systematic review and meta-analysis, Journal of Dentistry, Volume 88, 2019, 103167, ISSN 0300-5712, <https://doi.org/10.1016/j.jdent.2019.07.005>.
- Study Design:
  - Systematic review & meta-analysis
- Study Need / Purpose:
  - To assess the survival and complication rates of tooth-implant supported fixed dental prostheses.

# ARTICLE 2 SYNOPSIS

- Method
  - Electronic search for randomized control trials or prospective studies with observation period of at least 3 years with at least 10 participants. Studies were qualitatively assessed. Survival rates, technical and biological complications of tooth-implant FDPs were obtained, and were pooled by weighting each rate in inverse proportion to its variance.
- Results
  - 8 studies were considered, and showed that Estimated survival rates of T-I FDPs were 90.8% for 5 years and 82.5% after 10 years. Implant survival rates were 94.8% and 89.8% for 5 and 10 years respectively.
- Conclusions
  - Tooth-implant supported dental prostheses are recommendable treatment option in partial dentition, and should be rigidly constructed with a maximum of four units.
- Limitations
  - Lack of 10+ year follow up, so difficult to determine long-term prognosis.

# ARTICLE 2 SELECTION

- Reason for selection
  - Level of evidence
  - Relevance to PICO and clinical questions
- Applicability to your patient
  - Treatment option for edentulous space on UL
- Implications
  - Consider tooth-implant supported 3-unit FDP in UL

# ARTICLE 3:

- De Backer H, Van Maele G, De Moor N, Van den Berghe L. Long-term results of short-span versus long-span fixed dental prostheses: an up to 20-year retrospective study. Int J Prosthodont. 2008 Jan-Feb;21(1):75-85. PMID: 18350953.
- Study Design:
  - Retrospective study
- Study Need / Purpose:
  - To evaluate the efficacy and determine the frequency and causes of failures in short-span and long-spans fixed dental prostheses.

# ARTICLE 3 SYNOPSIS

- Method
  - 236 Ss-FDPs and 86 Ls-FDPs made in an undergraduate university clinic for 149 and 70 patients, respectively, were evaluated over a 20-year period.
- Results
  - Overall survival of short-span FDPs is higher than long-span FDPs (70.8% vs. 52.8%). No significant difference at year T9 between RCT abutments. Most common reason for failure in short-span FDPs was biological, compared to technical failure in long-span FDPs.
- Conclusions:
  - Overall survival of short-span and long-span FDPs favorable over 20 years, but short-span statistically significantly better. The use of RCT abutment becomes more significant in FDPs with 4 or more units.
- Limitations
  - Single cohort. Limited by patients who returned to remain in the study over time.



# ARTICLE 3 SELECTION

- Reason for selection
  - Relevance to PICO and clinical questions
- Applicability to your patient
  - Patient has RCT abutment teeth for FDPs in both edentulous areas.
- Implications:
  - Avoid using RCT teeth as supports, especially if using a 4+ unit FDP.

# LEVELS OF EVIDENCE

- ☒ **1a** – Clinical Practice Guideline, Meta-Analysis, Systematic Review of Randomized Control Trials (RCTs)
- ☐ **1b** – Individual RCT
- ☐ **2a** – Systematic Review of Cohort Studies
- ☒ **2b** – Individual Cohort Study
- ☐ **3** – Cross-sectional Studies, Ecologic Studies, “Outcomes” Research
- ☐ **4a** – Systematic Review of Case Control Studies
- ☐ **4b** – Individual Case Control Study
- ☐ **5** – Case Series, Case Reports
- ☐ **6** – Expert Opinion without explicit critical appraisal, Narrative Review
- ☐ **7** – Animal Research
- ☐ **8** – In Vitro Research

# STRENGTH OF RECOMMENDATION TAXONOMY (SORT)

<input checked="" type="checkbox"/>	<b>A</b> – Consistent, good quality patient oriented evidence
<input type="checkbox"/>	<b>B</b> – Inconsistent or limited quality patient oriented evidence
<input type="checkbox"/>	<b>C</b> – Consensus, disease oriented evidence, usual practice, expert opinion, or case series for studies of diagnosis, treatment, prevention, or screening

# CONCLUSIONS: D3

How does the evidence apply to this patient?

Span of planned FDP; FDP support; RCT abutment teeth

Based on the above considerations, how will you advise your D4?

3-unit implant-supported FDP in UR, discuss options of 4-unit tooth-supported bridge or 3-unit tooth-implant supported FPD in UL.

# CONCLUSIONS: D4

Based on your D3's bottom line recommendations, how will you **advise** your patient?

- UR: 3-unit implant supported prosthesis
- UL: 3-unit implant-tooth supported prosthesis
- [Lower: Single implants]

How will you **help** your patient?

- Refer

# DISCUSSION QUESTIONS

- 1-2 slides
- List posted discussion questions
- Questions may also be from Group Leader or Specialist

# DISCUSSION QUESTIONS



# THANK YOU

AND THEN I SAID, "YOU MIGHT LOSE THE TOOTH..."



...BUT WE'LL CROSS THAT **BRIDGE** WHEN  
WE GET TO IT"