

Perio-Endo Lesions

Evidence Based Dentistry Rounds

Specialty

10A-4

Theresa, Jeffrey, Kristen, & Sarah

11/11/2020

Rounds Team

- ▶ **Group Leader: Dr. Yray**
- ▶ **Specialty Leader: Dr. Rawal**
- ▶ **Project Team Leader: D4 Theresa Ellner**
- ▶ **Project Team Participants: D1 Sarah Salcedo; D2 Kristen Wu; D3 Jeffrey Schootman**

Patient Background

- ▶ 74 year old
- ▶ Male
- ▶ White
- ▶ Chief complaint: “was told I need to get a tooth taken out and want an implant”
- ▶ Patient had all other work completed at a different dental school. Was told he had to go somewhere else for the lower left.

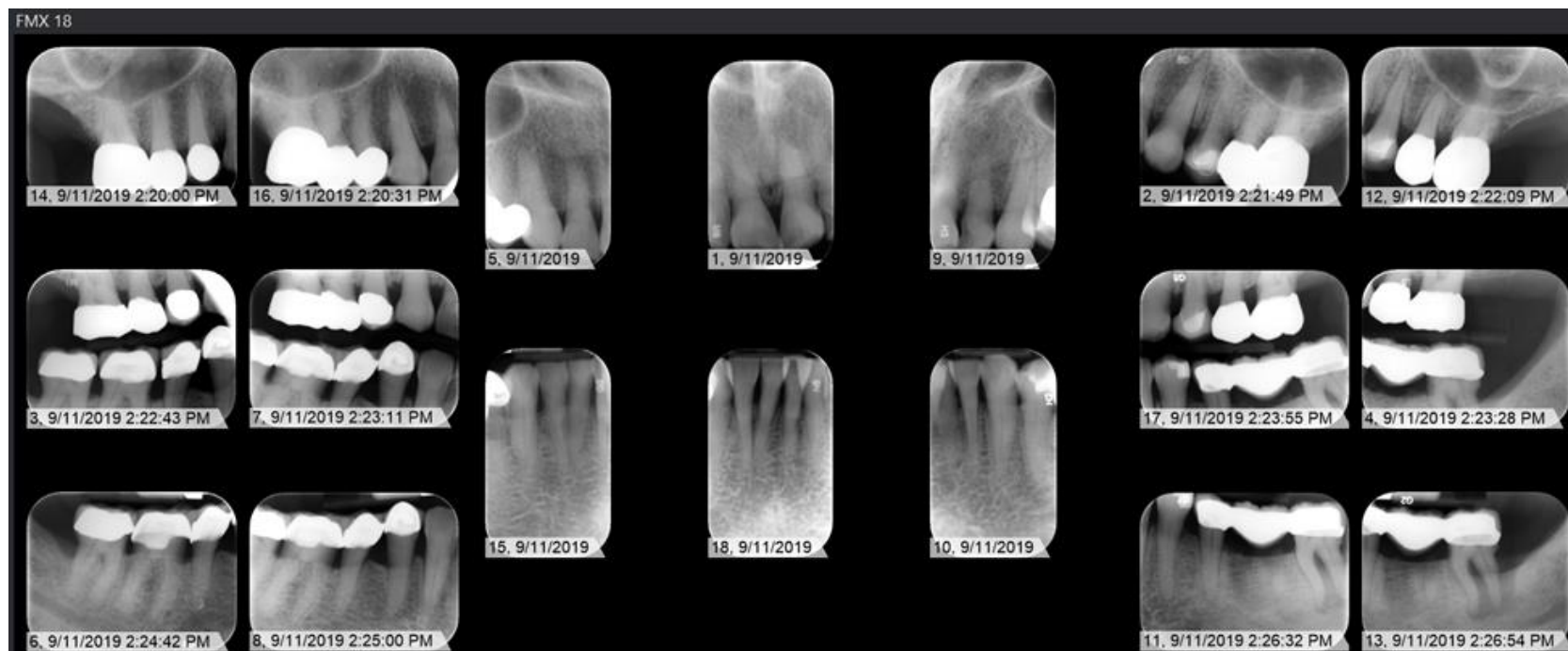Medical History

- ▶ Allergies: Seasonal
- ▶ Past cigarettes use, High Blood Pressure, COPD, Sleep apnea, type 2 diabetes (controlled)
- ▶ Medications list:
 - ▶ Levothyroxine, AndroGel (testosterone), azelastine, vanicream, spironolactone, triamcinolone acetonide, losartan, methylphenidate HCl, metformin, furosemide, flaxseed oil, vitamin C, presser vision lutein, fexofenadine, coricidin HBP chest cong-cough, chlorpheniramine maleate, restasis, align, anoro ellipta, ProAir HFA, mometasone, montelukast, betimol, diltiazem

Dental History

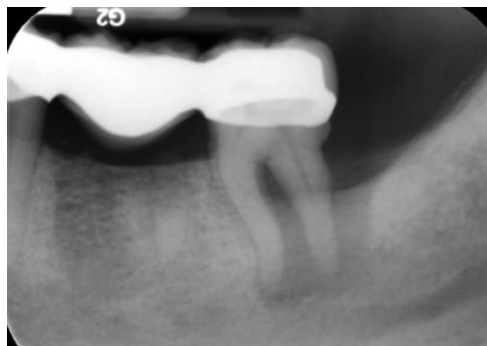- ▶ Patient regularly see a dentist. Was previously being seen at a different dental school.
- ▶ History of extractions, periodontal treatment, crowns, bridges, root canal treatment
- ▶ Patient reports clenching/grinding and sensitivity to hot/cold
- ▶ Patient states he brushes 2x daily and flosses 1x daily

Radiographs

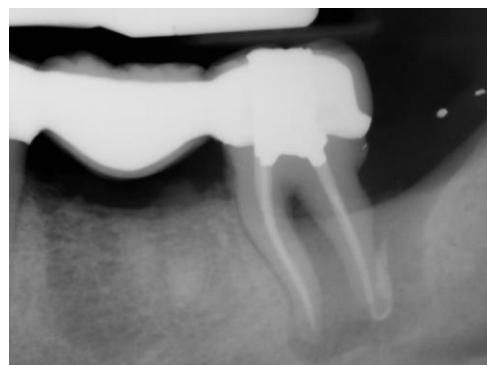

Radiographs

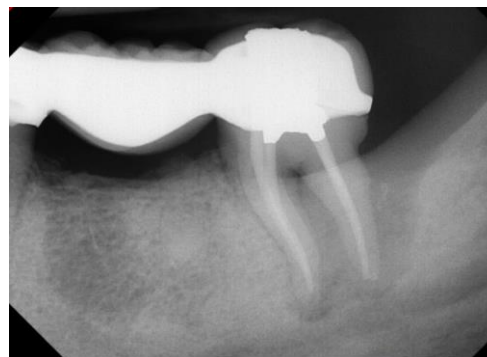
► Before endo



► After endo



► After Micro surgery



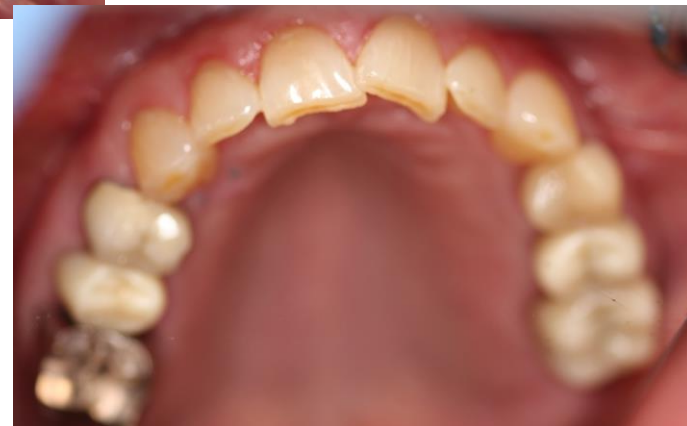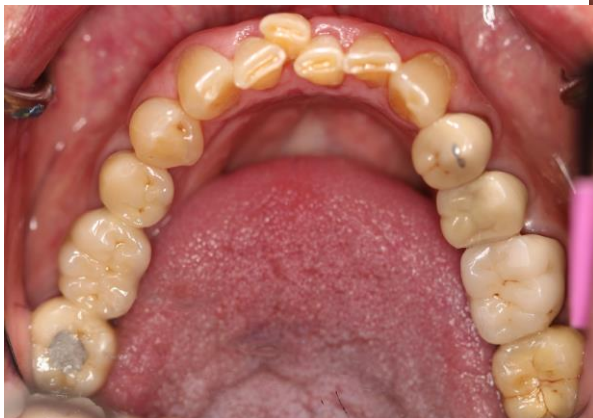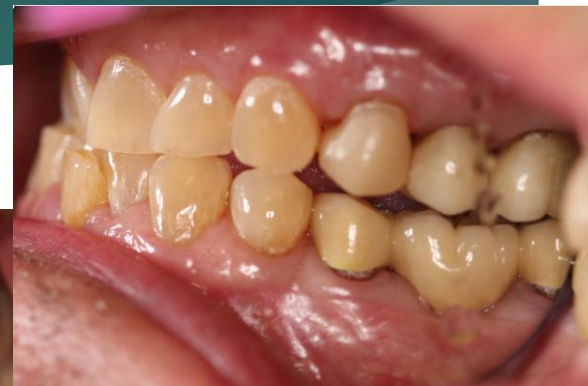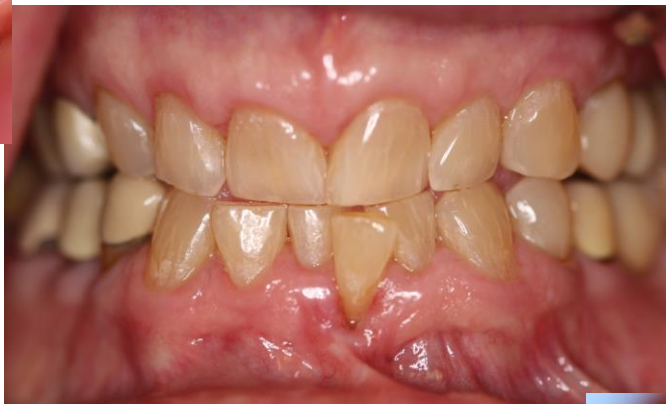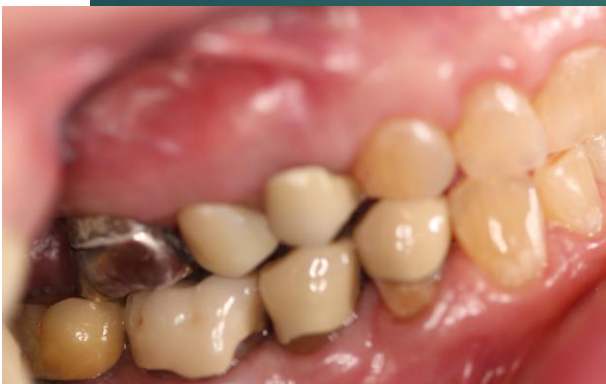Radiographic Findings

- ▶ Multiple restorations (crowns on posterior teeth)
- ▶ PARL #18
 - ▶ Extensive bone loss
- ▶ Remaining root tips #19
- ▶ Generalized bone loss

Clinical Findings

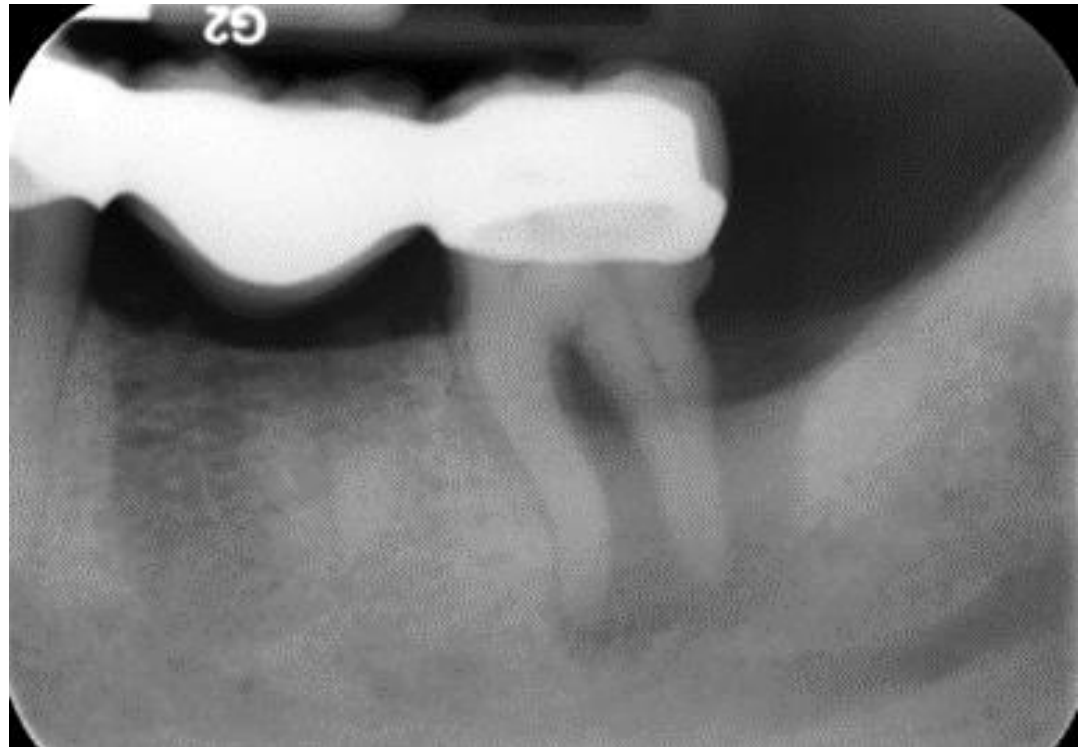- ▶ Mucogingival defect #24
- ▶ Draining sinus tract #18
- ▶ Class 2 furcation #18
- ▶ Generalized gingival recession

Clinical Photos



Specific Findings

- ▶ Draining sinus tract #18
- ▶ Class 2 furcation #18
- ▶ PARL #18



Periodontal Charting

[illegible]

Diagnosis

- ▶ Due to the location of the sinus tract in regard to the furcation, it was determined that #18 was a perio-endo lesion.
- ▶ Treatment for this area includes SRP and endodontic treatment.
- ▶ Periodontal diagnosis of the entire dentition
 - ▶ Stage III: severe perio (>5mm ID CAL) with localized distribution
 - ▶ Grade B: moderate rate of progression
 - ▶ ADA designation: IV advanced chronic periodontitis

Problem List

- ▶ Draining sinus tract/bone loss around #18.
- ▶ Mucogingival defect #24- leaving it alone because coverage will be difficult if not impossible.

D1 Basic Science

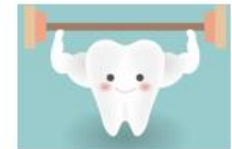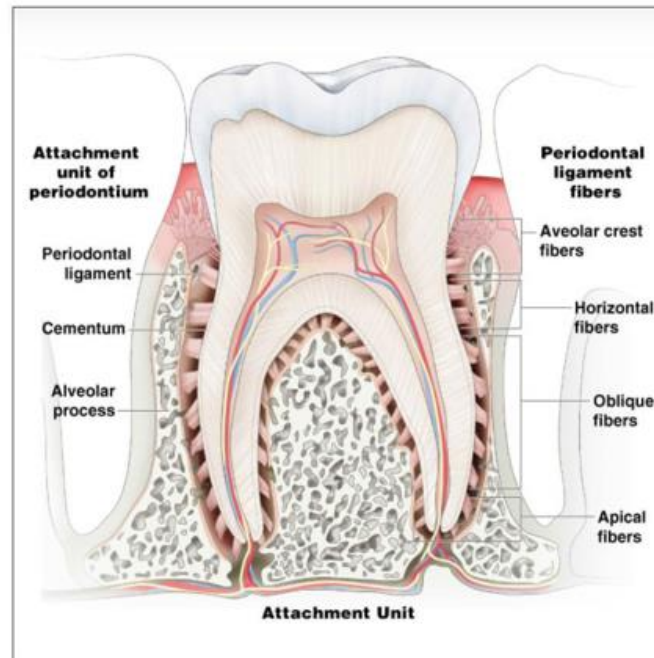
What does the periodontium consist of and what is each of its function?

The Periodontium

Supporting structures

Includes:

- * Alveolar bone
- * Gingiva
- * Cementum
- * Periodontal Ligament



Provide support and protection



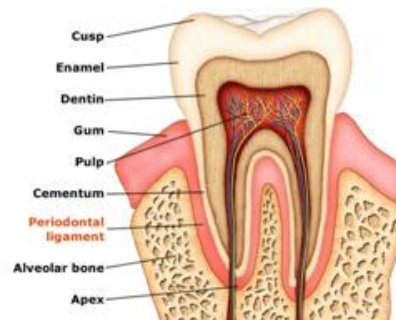D1- Functions of the periodontium

ALVEOLAR BONE

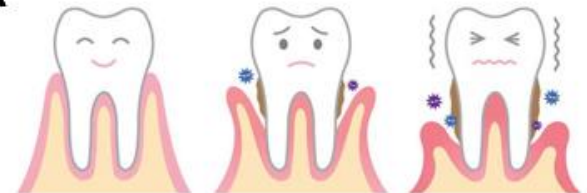- * protect and support roots of teeth

CEMENTUM

- * Point of attachment
- * Anchoring



GINGIVA



PERIODONTAL LIGAMENT

- * Suspension
- * Nutritional support
- * Protective seal to withstand mechanical forces
- * Line of defense

D1- Citation

► **Reference Citation(s)**

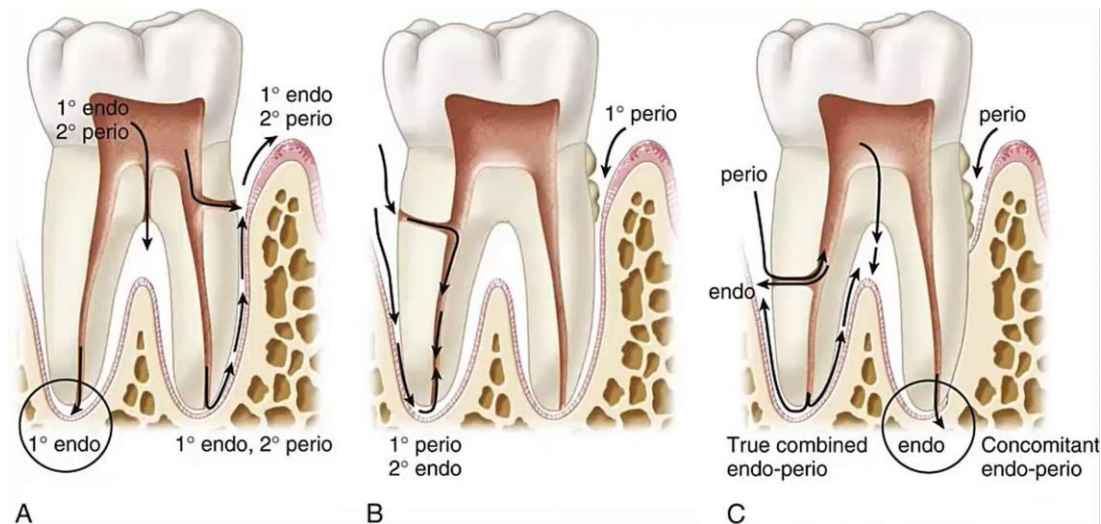
Gehrig, Jill S., et al. Foundations of Periodontics for the Dental Hygienist. Wolters Kluwer, 2019.

Tomokiyo, Atsushi, et al. "Periodontal Ligament Stem Cells: Regenerative Potency in Periodontium." *Mary Ann Liebert, Inc., Publishers*, 25 July 2019.

Zhao, Jing, et al. "Mesenchymal Stem Cells in Teeth." *Encyclopedia of Bone Biology*, Academic Press, 30 June 2020.

D2 Pathology

- ▶ *What is a Perio-endo Lesion?*
 - ▶ *A region of damage involving both periodontal tissues and pulp*
 - ▶ *Acute vs. Chronic*
- ▶ *What is the etiology of this type of lesion?*



D2 Citation

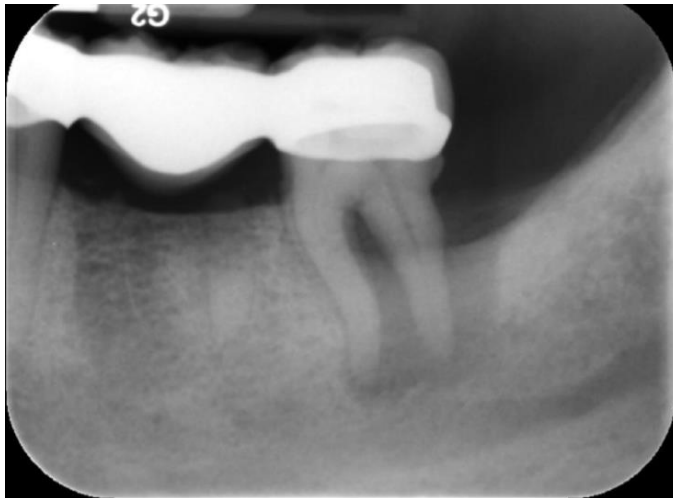► **Reference citation(s):**

- M, Herrera D;Retamal-Valdes B;Alonso B;Feres. "Acute Periodontal Lesions (Periodontal Abscesses and Necrotizing Periodontal Diseases) and Endo-Periodontal Lesions." *Journal of Clinical Periodontology*, U.S. National Library of Medicine, 4 Oct. 2016, pubmed.ncbi.nlm.nih.gov/29926493/.

D3 PICO

► Clinical Question:

- What is the survivability of a Perio-Endo lesion?



PICO Format

- ▶ **P:** Patients with a Perio-endo lesion
- ▶ **I:** Endo therapy followed by Perio therapy
- ▶ **C:** alternative therapy
- ▶ **O:** Survivability of the affected tooth

PICO Formatted Question

- ▶ Among patients with a perio-endo lesion that receive endodontic therapy followed by periodontal therapy compared to alternative therapy alone, what is the survivability of the tooth?

Clinical Bottom Line

- ▶ Perio-endo lesions are complex and require multiple stages of intervention for a successful outcome.
- ▶ In practice, nearly all lesions must be treated with endodontic therapy followed by periodontal therapy.
- ▶ Some research suggests (Singh 2011) that early intervention treating the primary cause may resolve the lesion, though more investigation is needed

Search Background

- ▶ **Date(s) of Search:** 10/22/2020, 11/1/2020
- ▶ **Database(s) Used:** PubMed
- ▶ **Search Strategy/Keywords:** Periodontal, Endodontal, Lesion, Treatment, Therapy

Search Background

- ▶ **MESH terms used:** Periodontal disease, Root Canal Therapy/methods, Dental, Treatment Outcome

Article 1 Citation: Endo-Perio Dilemma

- ▶ Citation
 - ▶ Singh P. (2011). Endo-perio dilemma: a brief review. *Dental research journal*, 8(1), 39–47.
- ▶ Study design
 - ▶ Expert Opinion
- ▶ Purpose
 - ▶ To inform practitioners about the standard of care for perio-endo lesions

Article 1 Synopsis: Endo-Perio Dilemma

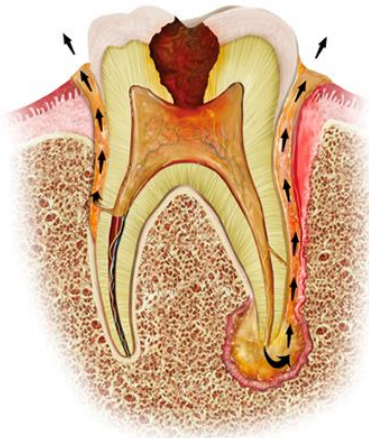
- ▶ Classification of perio-endo lesions
 - ▶ Endodontic
 - ▶ Periodontal
 - ▶ True combined
 - ▶ Iatrogenic
- ▶ Early Treatment of lesions
 - ▶ Primary Endodontic → Standard RCT with or without Perio intervention: fair prognosis
 - ▶ Primary Periodontal → Surgical/non-surgical periodontal intervention with endodontal therapy: guarded prognosis
 - ▶ True combined/Iatrogenic: Standard RCT with Perio intervention: poor/hopeless prognosis

Article 1 Synopsis: Endo-Perio Dilemma

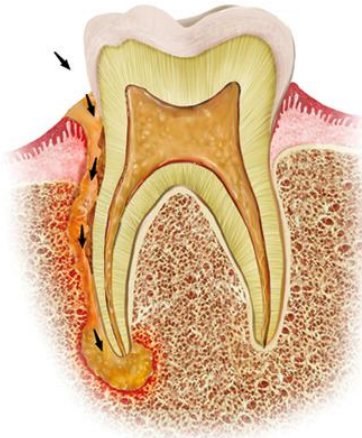
- ▶ Conclusion
 - ▶ A thorough history is important to arrive at a correct diagnosis
 - ▶ Treatment depends largely on establishing a correct diagnosis and timely treatment
 - ▶ Regenerative treatments improve outcomes
 - ▶ At best, perio-endo lesions with proper treatment have a fair prognosis
- ▶ Limitations
 - ▶ Does not directly state survival rates
 - ▶ Older publication (2011)
 - ▶ Low level of evidence (5)

Article 1: Endo-Perio

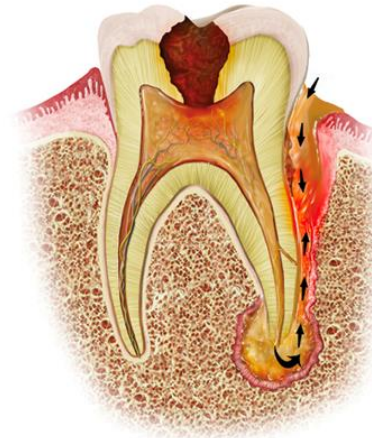- ▶ Reason for selection
 - ▶ Addresses PICO question
 - ▶ Provides sufficient guidelines for a complex lesion
 - ▶ Reputable source



Primary endo/secondary perio lesion



Primary perio/secondary endo lesion



True combined lesion

Article 2: Endo-Perio lesions, a Synergistic Approach

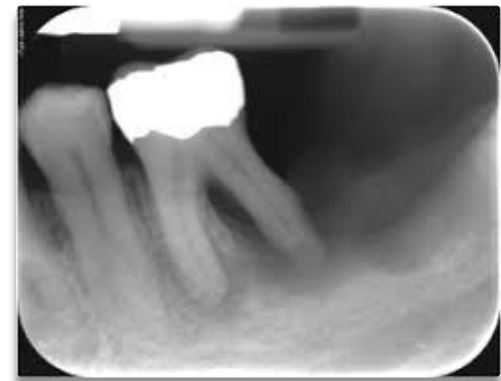- ▶ Citation
 - ▶ Raveendran S, Shruthi S , Batra P, A Magadum S, Guru S, Nisha K.J . Endo perio lesions- A synergistic approach. Int J Periodontol Implantol 2019;4(4):147-151
- ▶ Study design
 - ▶ Case series
- ▶ Purpose
 - ▶ To provide an understanding of perio-endo lesions and how to treat them

Article 2: Endo-Perio lesions, a Synergistic Approach

- ▶ Synopsis
 - ▶ The pulp and periodontium come from a similar embryonic origin
 - ▶ Perio-endo lesion treatments generally have success rates between 27-37%
 - ▶ Case studies
 - ▶ All cases were treated with Endodontal therapy followed by periodontal regenerative therapy and remained functional at 12 months
 - ▶ One case described a successful hemi-section followed by crown placement
- ▶ Discussion
 - ▶ Regenerative therapy results in more favorable outcomes compared to standard periodontal therapy alone

Article 2 : Endo-Perio Lesion, a Synergistic Approach

- ▶ Limitations
 - ▶ Case series (4 cases)
 - ▶ Cases from a single institution → poor generalizability
 - ▶ Moderate level of evidence (4)
- ▶ Reason for selection
 - ▶ Directly answers the PICO question
 - ▶ Compares various treatment methods
 - ▶ Author credibility
 - ▶ Recent publication



Article 3: Treatment of Perio-Endo Lesions

▶ Citation

- ▶ Schmidt JC, Walter C, Amato M, Weiger R. Treatment of periodontal-endodontic lesions--a systematic review. J Clin Periodontol. 2014 Aug;41(8):779-90. doi: 10.1111/jcpe.12265. Epub 2014 Jul 2. PMID: 24766568.

▶ Study design

- ▶ Systematic review

▶ Purpose

- ▶ To inform the treatment of periodontal-endodontal lesions and understand the challenges that come along with them

Article 3: Treatment of Perio-Endo Lesions

► Synopsis

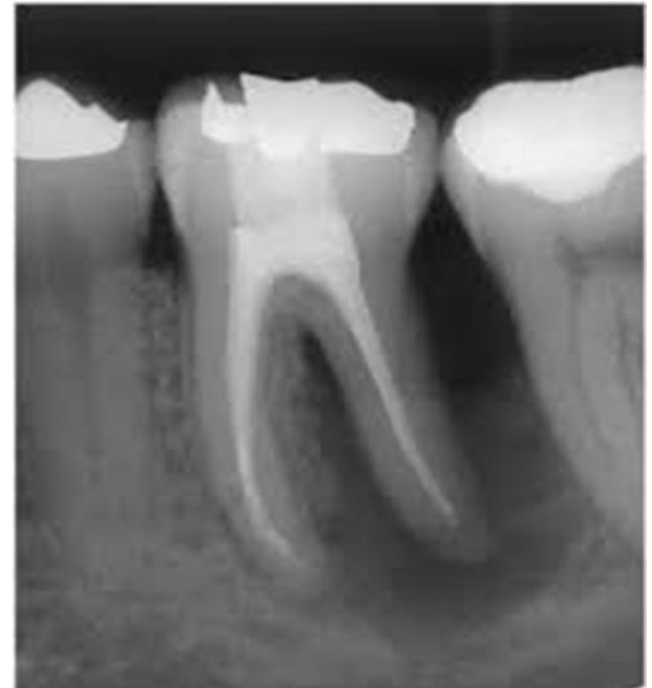- Literature search identified 23 paper relating to perio-endo lesions (111 total teeth)
- Some teeth were treated with only RCT, some with RCT and non-surgical perio therapy, and some with RCT + perio surgical therapy with guided regeneration
- RCT is the required first treatment for a positive outcome
- The article looked at whether the time delay between endo and perio therapy is significant. It appears to be clinically insignificant with similar outcomes

Article 3: Treatment of Perio-Endo Lesions

- ▶ Conclusion
 - ▶ Endo therapy must precede periodontal therapy
 - ▶ Perio therapy leads to better outcomes, generally
 - ▶ When perio therapy is preformed has little to no influence on outcomes
- ▶ Limitations
 - ▶ High level of evidence (1b), with very small sample size (111 teeth)
 - ▶ The study did not directly answer the PICO question, but did inform what the standard of care is.

Article 3: Treatment of Perio-Endo Lesions

- ▶ Reason for selection
 - ▶ High level of evidence
 - ▶ Reputable
 - ▶ Relates to the PICO question
 - ▶ Compares various treatment modalities



Levels of Evidence

- ★ **1a** – Clinical Practice Guideline, Meta-Analysis, Systematic Review of Randomized Control Trials (RCTs)
- ☐ **1b** – Individual RCT
- ☐ **2a** – Systematic Review of Cohort Studies
- ☐ **2b** – Individual Cohort Study
- ☐ **3** – Cross-sectional Studies, Ecologic Studies, “Outcomes” Research
- ☐ **4a** – Systematic Review of Case Control Studies
- ☐ **4b** – Individual Case Control Study
- ★ **5** – Case Series, Case Reports
- ★ **6** – Expert Opinion without explicit critical appraisal, Narrative Review
- ☐ **7** – Animal Research
- ☐ **8** – In Vitro Research

Strength of Recommendation Taxonomy (SORT)

<input type="checkbox"/>	A – Consistent, good quality patient oriented evidence
★	B – Inconsistent or limited quality patient oriented evidence
<input type="checkbox"/>	C – Consensus, disease oriented evidence, usual practice, expert opinion, or case series for studies of diagnosis, treatment, prevention, or screening

Conclusions: D3

The evidence collected from the literature search indicates...

- ▶ Treatment should be endo + perio
- ▶ Endo treatment should happen promptly
- ▶ Perio treatment is not especially time sensitive

Based on the above considerations, how will you advise your D4?

- ▶ My D4 should perform a standard RCT followed by SRP and follow up with the patient in 4-6 weeks

Conclusions: D4

Based on your D3's bottom line recommendations, how will you **advise** your patient?

- ▶ Treatment outcomes are unpredictable
- ▶ If the patient wants to try to save the tooth, we would do endo and perio treatment. Perio treatment would be started with SRP and evaluate healing. Follow-up 4-6 weeks.

How will you **help** your patient?

- ▶ Make sure the patient understands the risks included.
- ▶ Treat patient appropriately and consider the patients goals in treatment.

Discussion Questions

Submitted by	Submission Date	Discussion Question
Martin, India	10/29/2020	What treatments are indicated for perioendo lesions?
Nguyen, Olivia	11/01/2020	What are some possible pathways for bacteria to enter the tissues?
Tunio, Maryam	11/02/2020	How does a perioendo lesion affect restorability?
Umhoefer, Eric	11/03/2020	What is the prognosis of a tooth with a perioendo lesion?
Park, Edward	11/04/2020	What is the worst outcome of a tooth that has a perioendo lesion?
Young, Scarlett	11/04/2020	How does the timeline of treating a perioendo lesion complicate the overall treatment plan for the patient?
Cain , Carneisha	11/04/2020	When performing endo treatment on this specific lesion would the procedure be different from a typical endodontics procedure ?

THANK YOU
