

Dude, where's my teeth?

Evidence Based Dentistry Rounds

Pediatrics

Group 5

Team A2

Date 11/11/20

Rounds Team

- **Group Leader: Dr. Dix**
- **Specialty Leader: Dr. Gungor**
- **Project Team Leader: D4 Taylor McElwee**
- **Project Team Participants:**
 - **D1: Wasef Mahmoud and Tatiana McBride**
 - **D2: Mariah Kane**
 - **D3: Rachel Bohn**

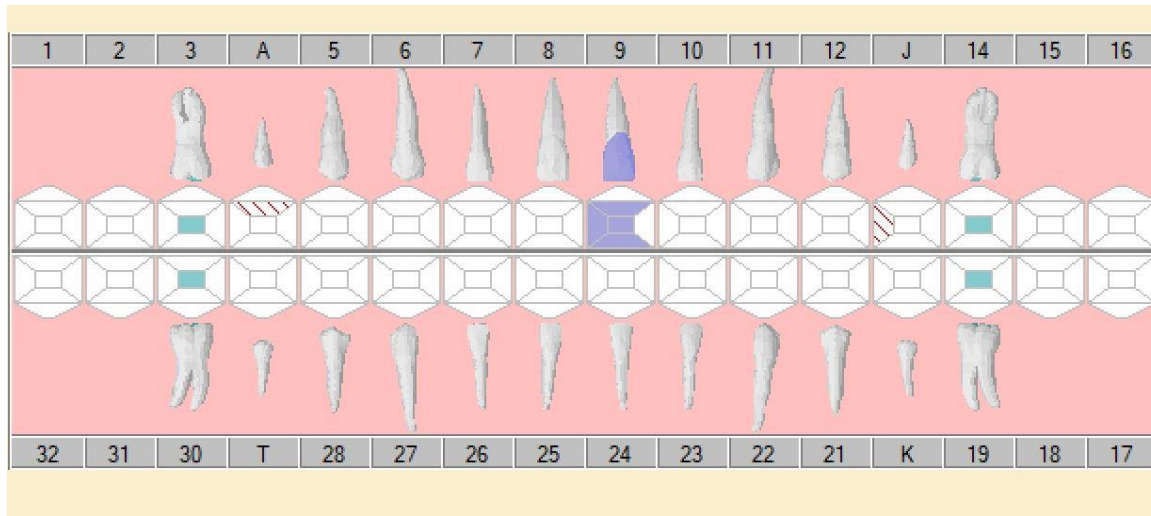
Patient

- 12 year old male
- Hispanic
- CC: "Here for my check up"
- Regularly seen pt at MUSOD since May 2016

Medical History

- Condition: Asthma
 - Medications: Albuterol inhaler prn
- Condition: Allergy to peanut butter
 - Pt has hives if exposed to peanut butter
- Treatment considerations:
 - Issues with rubber dam in the past due to difficulty breathing- isodry helped

Dental History

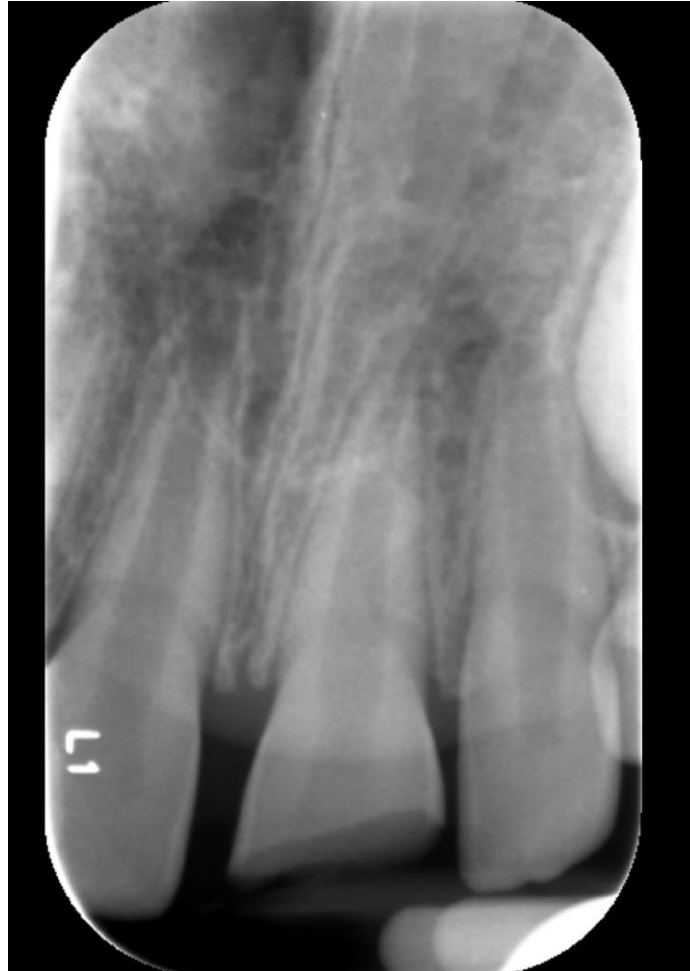

- #9: MIFL resin → Ellis Class 2 fracture 2016.
- L: DO resin
- Sealants: #3, #14, #19, #30
- Buccal of A and mesial of J : watch

Radiographs

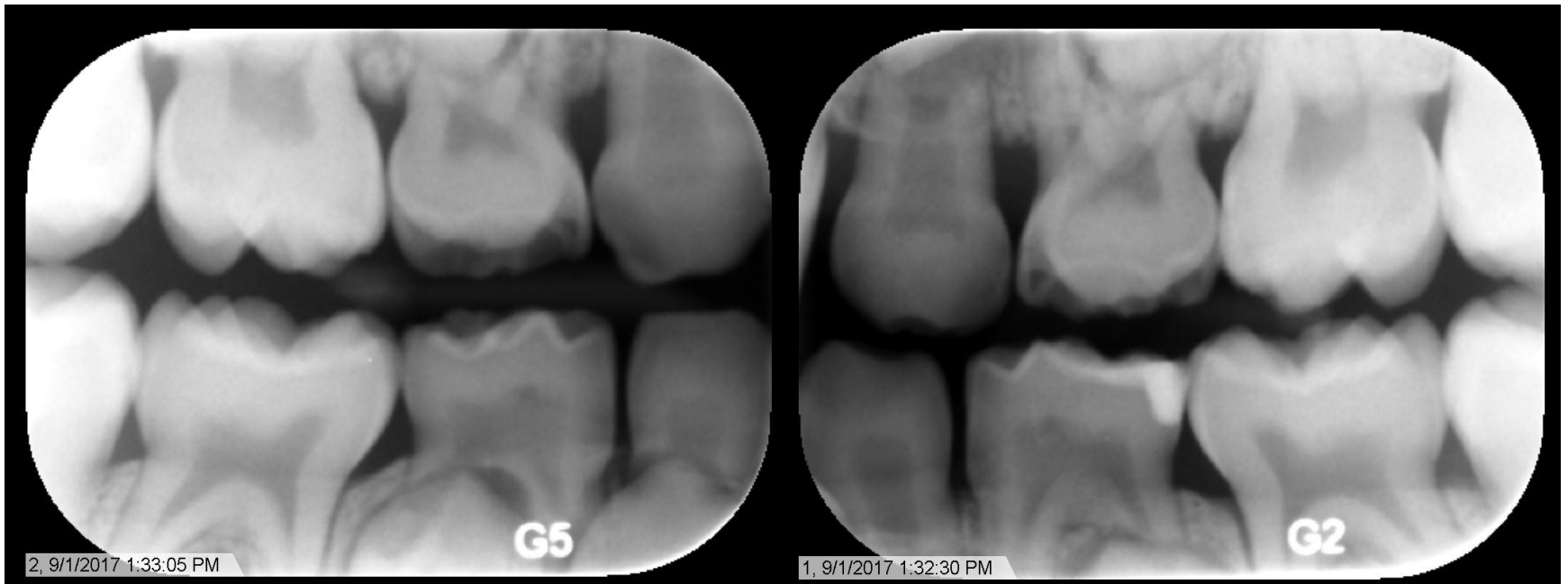Ellis Class 2 fracture:
Involvement of
enamel and dentin
excluding the pulp

May 2016



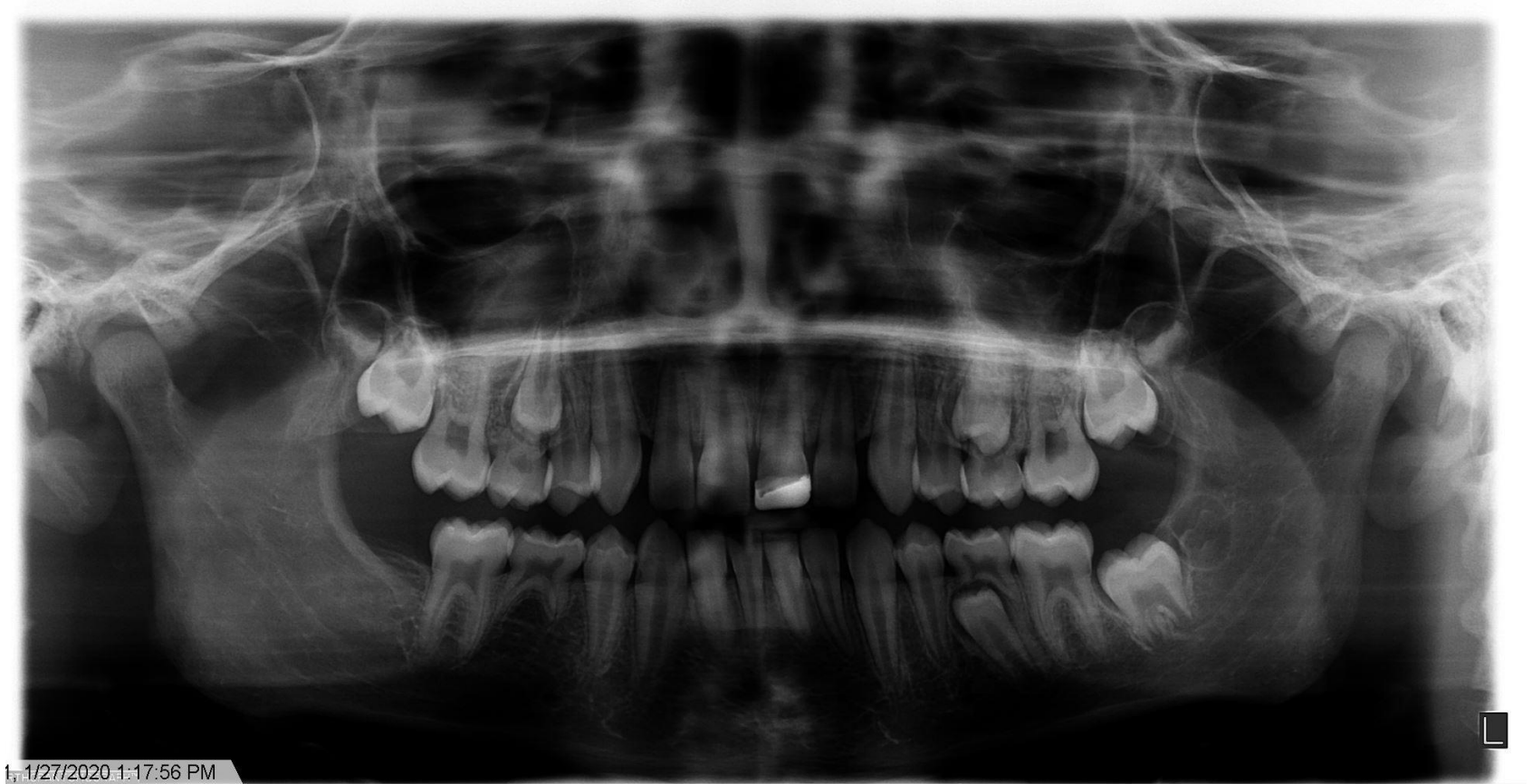Radiographs

Bitewings: 2017

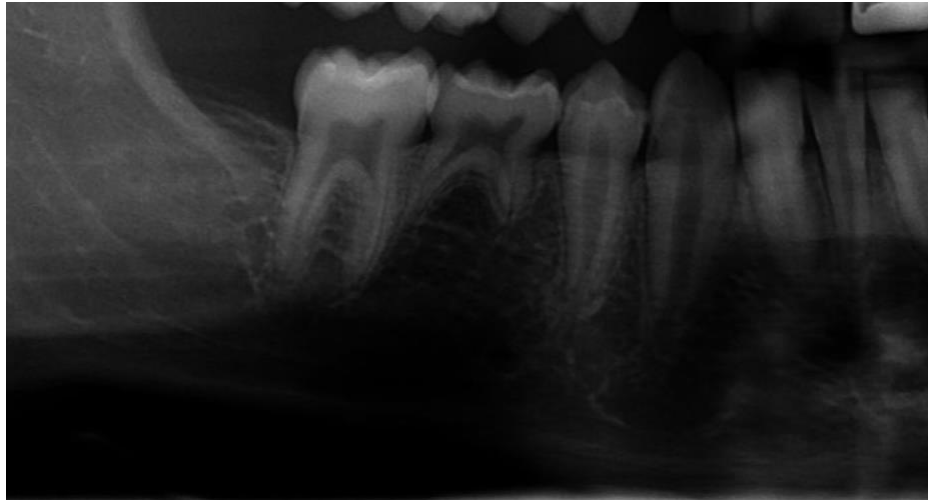


Radiographs

PAN: January 2020



Radiographic Findings



Missing: #29, #31, #32

Clinical Findings

- Defective sealants #3, #14, #19, #30
- Low caries risk
 - good oral hygiene
- No space loss!
- Excellent behavior

Periodontal Charting

- None

Diagnosis


- Congenitally missing #29, #32, #31

Problem List

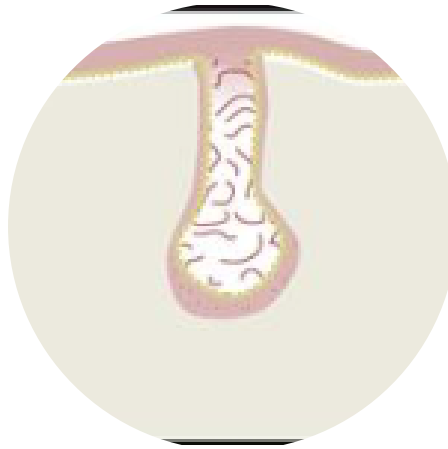
[illegible]

D1 Basic Science

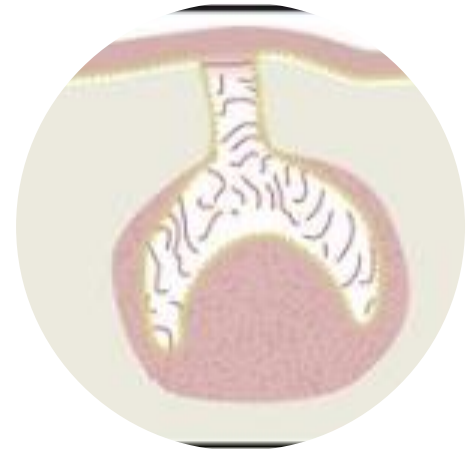Tooth Development



1. Initiation
(6th-7th week)

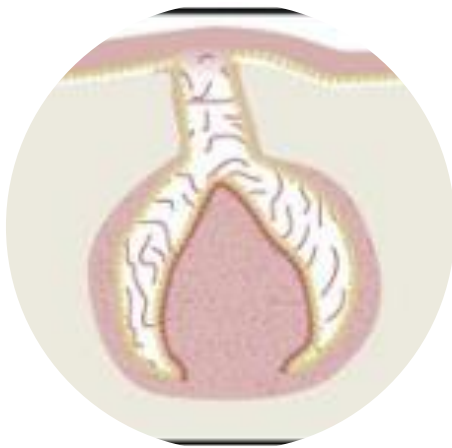

2. Bud Stage
(8th week)

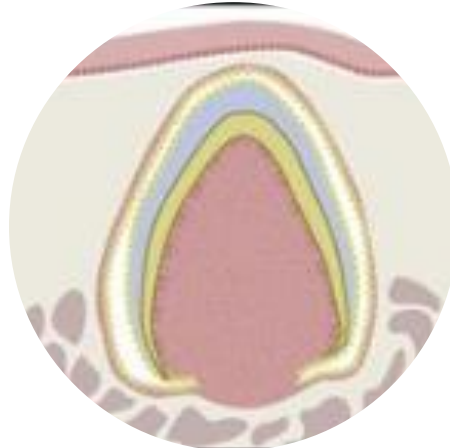

3. Cap Stage
(9th - 10th week)

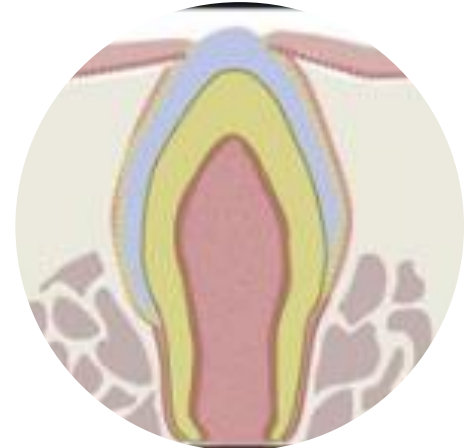Tooth Development



4. Bell Stage
(11th – 12th week)



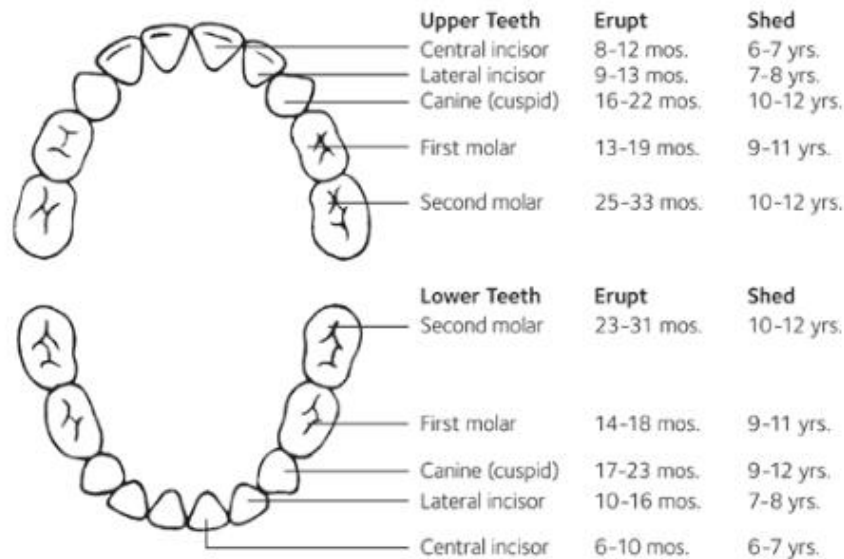
5. Apposition Stage
(Varies Per Tooth)



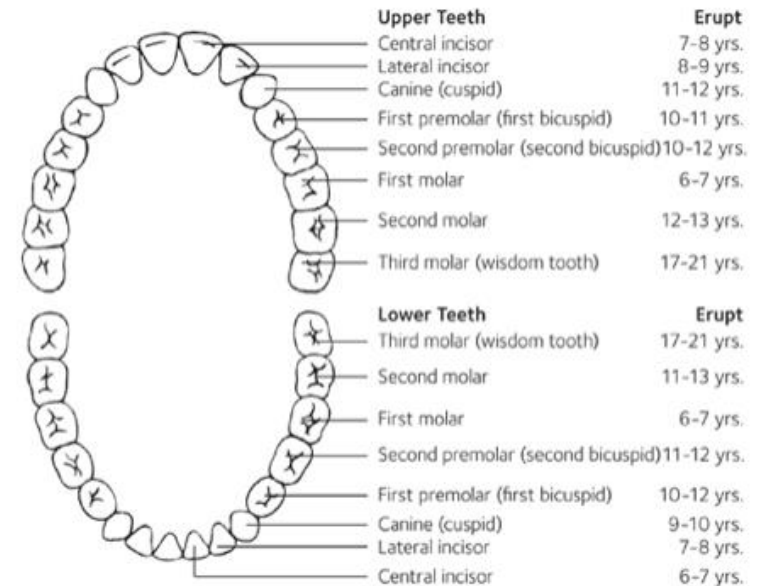
6. Maturation Stage
(Varies Per Tooth)

What are the Main Differences between Deciduous and Permanent Teeth?

Baby Teeth Eruption Chart



Permanent Teeth Eruption Chart



What are the Main Differences between Deciduous and Permanent Teeth?

- Number of teeth
- Succedaneous teeth
- Structure
- Composition
- Internal anatomy

D2 Pathology

- *Hypodontia: six or less missing teeth*
- *Anodontia: Congenital total absence of teeth*
- *Oligodontia: more than six missing teeth.*
- **Reference citation(s):** Rakhshan V. Congenitally missing teeth (hypodontia): A review of literature concerning the etiology, prevalence, risk factors, patterns and treatment. *Dent Res J (Isfahan)*. 2015;12(1):1-13.

D3 PICO Clinical question:

- What is the etiology of congenitally missing teeth?
 - Hypodontia
 - Can cause problems with: esthetics (confidence, self-esteem), occlusion, periodontal damage, bone growth, etc
 - Disturbance during the early stages of development
 - Genetic, environmental, infection, trauma, drugs, etc

Rakhshan V. (2015). Congenitally missing teeth (hypodontia): A review of the literature concerning the etiology, prevalence, risk factors, patterns and treatment. *Dental research journal*, 12(1), 1–13. <https://doi.org/10.4103/1735-3327.150286>

PICO Format

P: Congenitally missing 2nd premolars

I: Extracting deciduous second molar

C: retaining deciduous molar

O: Better restorative option/management

PICO Formatted Question

- Among patients with congenitally missing second premolars, does extracting the deciduous second molar (allowing the first molar to drift) versus retaining the deciduous molar for as long as possible (then seek a pros solution) lead to a better restorative management?

Clinical Bottom Line

- What treatment should the patient have going forward to allow the best restorative management considering his congenitally missing second premolars?
- To obtain better restorative management retaining the deciduous molar is the best option.

Search Background

- **Date(s) of Search:** 11/4/2020; 11/5/2020
- **Database(s) Used:** PubMed and Google Scholar
- **Search Strategy/Keywords:** Focused on congenitally missing premolars, specifically second premolars; restorative management; retaining deciduous molar and extracting.

Search Background

- **MESH terms used:**
 - Congenitally missing premolars
 - Congenitally missing teeth
 - Hypodontia
 - Retain deciduous molar
 - Management
 - Outcome
 - Permanent missing premolar
 - Rehabilitation
 - Preservation of deciduous teeth

Article 1 Citation, Introduction

- **Citation:** Rakhshan, V., & Rakhshan, A. (2016). Systematic review and meta-analysis of congenitally missing permanent dentition: Sex dimorphism, occurrence patterns, associated factors and biasing factors. *International orthodontics*, 14(3), 273–294. <https://doi.org/10.1016/j.ortho.2016.07.016>
- **Study Design:** Systematic Review
- **Study Need / Purpose:** Identified etiology of congenitally missing teeth

Article 1 Synopsis

- Method: Electronic search was performed to find all available literature regarding CMT during Sept 2012 to June 2013
- 74 studies were included
- Aim was to determine factors in CMT, patterns, and involved teeth
- Results: Mean CMT prevalence in males was 6.42 and females was 7.55

Article 1 Synopsis

- Conclusions: CMT is more common in females
- Limitations:
 - No orthodontic or dental patients were included in any studies (only epidemiological studies)
 - Low quality because of this
 - Not much research (especially on treatment options)

Article 1 Selection

- This article was selected because
 - it shows prevalence of CMT which is what our patient is diagnosed with (hypodontia)
 - it has a high level of evidence
- However, with limited studies and not touching on the treatment options, this study does not directly pertain to the PICO question, only the clinical question

Article 2 Citation, Introduction

- **Citation:** Terheyden, H., & Wüsthoff, F. (2015). Occlusal rehabilitation in patients with congenitally missing teeth-dental implants, conventional prosthetics, tooth autotransplants, and preservation of deciduous teeth-a systematic review. *International journal of implant dentistry*, 1(1), 30. <https://doi.org/10.1186/s40729-015-0025-z>
- **Study Design:** Systematic Review
- **Study Need / Purpose:** This report directly relates to the PICO question and addresses treatment of CMT

Article 2 Synopsis

- In patients with CMT does:
 - Dental implants, autotransplants, conventional prosthetics on teeth, or preservation of deciduous teeth have a better survival outcome
- Electronic search with a total of 63 relevant studies

Article 2 Synopsis

- Survival rate; failure rate:
 - Implants: 95.3% and 3.317%
 - Autotransplants: 94.4% and 1.061%
 - Deciduous teeth: 89.6% and 0.908%
 - Conventional prostheses: 60.2% and 5.144%
- Therefore:
 - implants had the best outcome (however, not in patients younger than 13)
 - Autotransplant and deciduous teeth had very low failure rates and would be appropriate treatment options for children
 - Conventional prosthetics had low survival rates and high failure rates compared to the rest of the options and would not be recommended based on this study

Article 2 Synopsis

- Limitations:
 - Implants were included in the study as a potential treatment option which is not part of the PICO question
 - Some of the studies included were retrospective
 - Low number of studies
 - Some cases used data from patient reported outcomes
 - Therefore, the outcomes of this study need to be looked at with caution

Article 2 Selection

- This report was selected because:
 - it directly addresses the PICO question
- High level of evidence

Article 3 Citation, Introduction

- **Citation:** Jha, P., & Jha, M. (2012). Management of congenitally missing second premolars in a growing child. *Journal of conservative dentistry : JCD*, 15(2), 187–190. <https://doi.org/10.4103/0972-0707.94577>
- **Study Design:** Case Report
- **Study Need / Purpose:** This report directly relates to the PICO question and addresses treatment of CMT

Article 3 Synopsis

- 14 year old female with bilaterally congenitally missing second mandibular premolars with crowding
- Tx options:
 - Extract deciduous second molar
 - Retain deciduous molar and hemisection
- Retaining the deciduous mandibular second molars after hemisection is a viable treatment option
- Limitations: Only 1 patients treatment & Crowding of teeth

Article 3 Selection

- This report was selected because:
 - it directly addresses the PICO question
- However, as this is a case report it does not have a high level of evidence

Levels of Evidence

- ☒ **1a** – Clinical Practice Guideline, Meta-Analysis, Systematic Review of Randomized Control Trials (RCTs)
- ☐ **1b** – Individual RCT
- ☒ **2a** – Systematic Review of Cohort Studies
- ☐ **2b** – Individual Cohort Study
- ☐ **3** – Cross-sectional Studies, Ecologic Studies, “Outcomes” Research
- ☐ **4a** – Systematic Review of Case Control Studies
- ☐ **4b** – Individual Case Control Study
- ☒ **5** – Case Series, Case Reports
- ☐ **6** – Expert Opinion without explicit critical appraisal, Narrative Review
- ☐ **7** – Animal Research
- ☐ **8** – In Vitro Research

Strength of Recommendation Taxonomy (SORT)

<input type="checkbox"/>	A – Consistent, good quality patient oriented evidence
<input checked="" type="checkbox"/>	B – Inconsistent or limited quality patient oriented evidence
<input type="checkbox"/>	C – Consensus, disease oriented evidence, usual practice, expert opinion, or case series for studies of diagnosis, treatment, prevention, or screening

?

Double click table to activate check-boxes

Conclusions: D3

How does the evidence apply to this patient?

- The literature available does show that retaining the deciduous molar has a better survival rate and lower failure rate when compared to extracting, space maintaining, and put prosthetic on later
- However, this should be looked at with caution as there was a small amount of studies available
- Specialist consult: recommended to retain as well

Based on the above considerations, how will you advise your D4?

- retain deciduous molar

Conclusions: D4

- Advice to patient and patient's parent:
 - Continue to monitor #9
 - For hygiene, keep up the good work!
 - It is very important that pt keeps T clean. T gone= need to address space loss
 - Pt must also take great care of #30. #30 gone= no molar occlusion on left side
 - Continue to monitor the lower left

Discussion Questions

- Any questions?

THANK YOU

43 days until Christmas 😊