

# Group 4B-1 Rounds

EBD Rounds

**Specialty: Prosthodontics**

Group 4B-1

Date: 11/18/20

# Rounds Team

- **Group Leader: Dr. Grady**
- **Specialty Leader: Dr. Chien**
- **Project Team Leader: D4- Xavier Goode**
- **Project Team Participants:**
  - **D1- Ryan Sweenson**
  - **D2-Sundeep Khahra**
  - **D3-Matthew Ang**

# Patient

- 71 y/o
- Male
- Caucasian
- “I want my missing tooth fixed”
- Received this patient after hopeless teeth were extracted and mandibular partial was fabricate to restore partial edentulism in the mandible.
- Radiographs are prior to our transfer exam

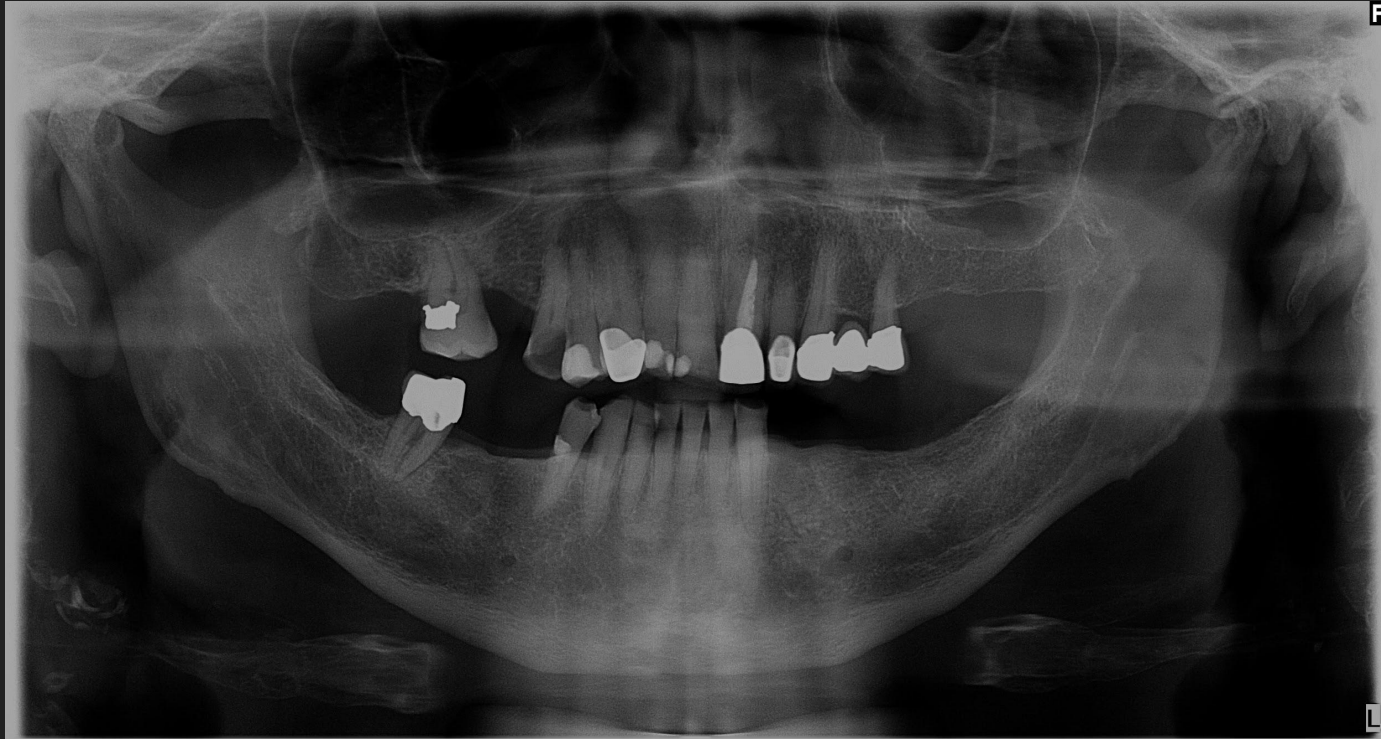
# Medical History

- Latex allergy
- High Cholesterol
- High blood pressure
- Stent placement in 2000
- Kidney stones in 2015
- Medications: Atorvastatin, Latanoprost, Fish Oil, baby aspirin, Iron supplement.

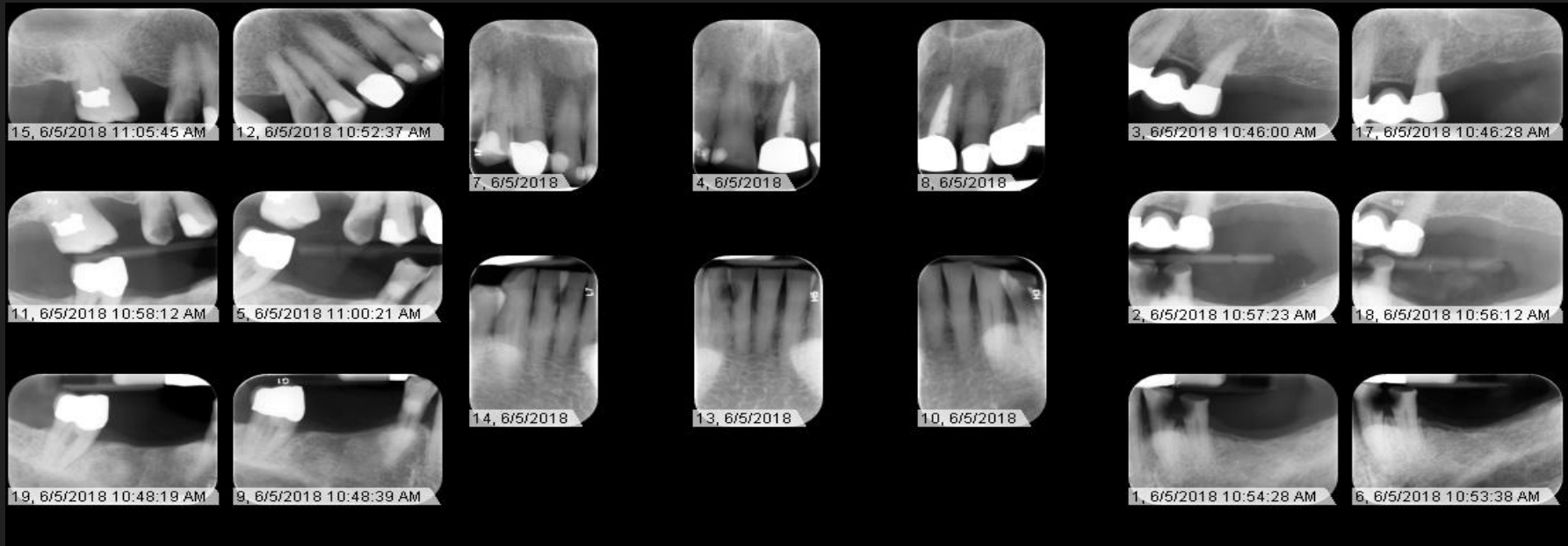# Dental History

- Non- frequent dental visits more than 2 years since last visit
- Pt brushes once a day and sometimes flosses
- Mandibular partial done at MUSoD in 2019
- Maxillary bridge #11-13 done over 30 years ago in private practice
- Defective crown margin on lingual of #10 done by aspen dental, plan to remake.

# Radiographs: Dec 2018



# Radiographs: June 2019



# Radiographic Findings

- 1 slide summarizing pertinent radiologic findings
- Illustrate with radiograph and/or other graphics as needed



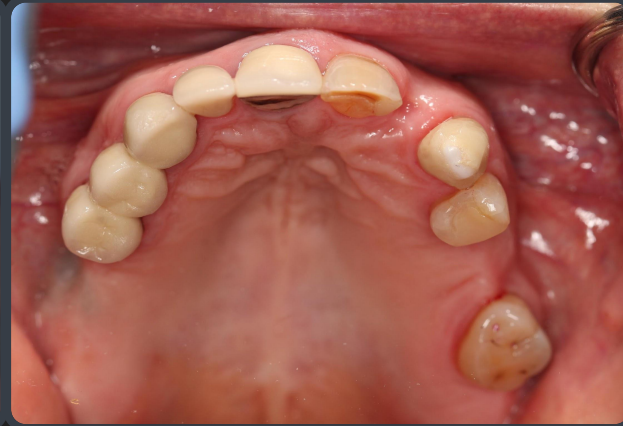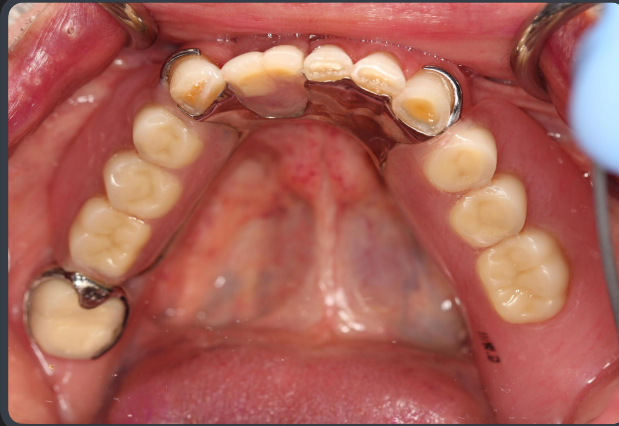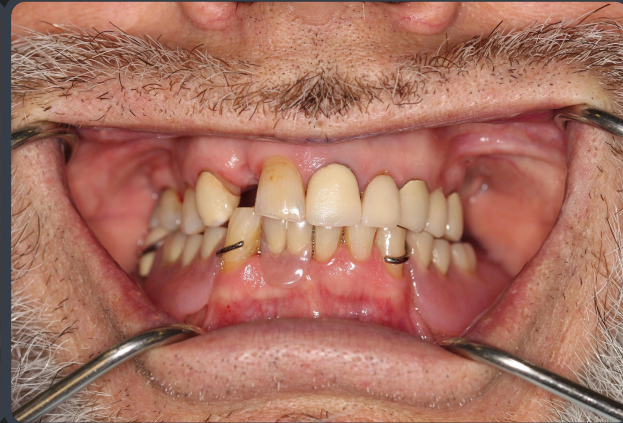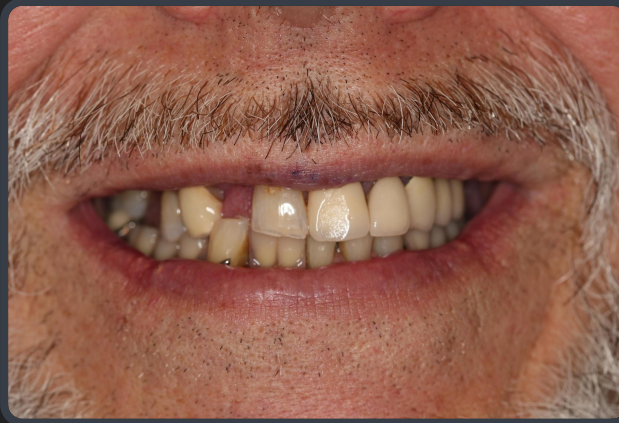# Clinical Findings

Date	Prov./User	Code	Site	Surf.	Stat	Pre-Auth	Special I	Emergen	Discipline	Appr. User	Description
07/12/18	M. Zellmer	C1003	2		A					M. Vitense	Tipped Mesially
07/12/18	M. Zellmer	D2140	2	B	E					M. Vitense	1 surf. - amalgam
08/08/18	M. Zellmer	C3030	2	B	A					M. Vitense	Recurrent Caries
08/08/18	M. Zellmer	C4052	2		A					M. Vitense	Furcation Class II
07/12/18	M. Zellmer	C3040	4	MOBL	A					M. Vitense	Gross Decay
08/08/18	M. Zellmer	C3030	5	DO	A					M. Vitense	Recurrent Caries
08/08/18	M. Zellmer	D2392	5	DO	E					M. Vitense	Resin-based comp-2 surf. post.
07/12/18	M. Zellmer	D2750	6	MIDFL	E					M. Vitense	PFM high noble metal crown
07/12/18	M. Zellmer	C3030	7	M	A					M. Vitense	Recurrent Caries
07/12/18	M. Zellmer	D2331	7	DL	E					M. Vitense	2 surf. - ant./resin
07/12/18	M. Zellmer	D2331	7	ML	E					M. Vitense	2 surf. - ant./resin
08/08/18	M. Zellmer	C3030	7	F	A					M. Vitense	Recurrent Caries
08/08/18	M. Zellmer	D2330	7	F	E					M. Vitense	1 surf. - ant./resin
07/12/18	M. Zellmer	D2331	8	DL	E					M. Vitense	2 surf. - ant./resin
08/08/18	M. Zellmer	C3020	8	M	A					M. Vitense	Primary Caries
Date	Prov./User	Code	Site	Surf.	Stat	Pre-Auth	Special I	Emergen	Discipline	Appr. User	Description
07/12/18	M. Zellmer	D2750	9	MIDFL	E					M. Vitense	PFM high noble metal crown
07/12/18	M. Zellmer	D3310	9		E					M. Vitense	Endo therapy - anterior
07/29/19	M. Zellmer	C3010	9	L	A					T. Smithy	Incipient Caries/Watch/Check
07/12/18	M. Zellmer	C3030	10	M	A					M. Vitense	Recurrent Caries
07/12/18	M. Zellmer	D2750	10	MIDFL	E					M. Vitense	PFM high noble metal crown
08/08/18	M. Zellmer	C3030	10	D	A					M. Vitense	Recurrent Caries
01/25/19	M. Zellmer	C4032	10		A					M. Grady	Radiolucency
07/12/18	M. Zellmer	D6750	11,13		E					M. Vitense	Retainer cm/porcfused/high noble
07/12/18	M. Zellmer	D6240	12		E					M. Vitense	Pontic-porc fuse to high noble
07/12/18	M. Zellmer	C3040	20	MOBL	A					M. Vitense	Gross Decay
07/12/18	M. Zellmer	C3050	20	O	A					M. Vitense	Abfraction/Abrasion/Erosion
07/12/18	M. Zellmer	C3040	21	DOBL	A					M. Vitense	Gross Decay
07/12/18	M. Zellmer	C3050	21	O	A					M. Vitense	Abfraction/Abrasion/Erosion
07/12/18	M. Zellmer	C3050	22	I	A					M. Vitense	Abfraction/Abrasion/Erosion
07/12/18	M. Zellmer	C3050	23	I	A					M. Vitense	Abfraction/Abrasion/Erosion

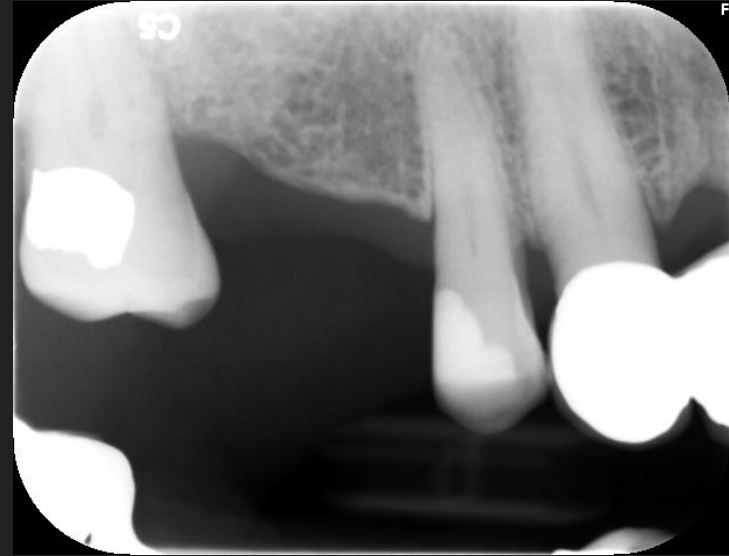
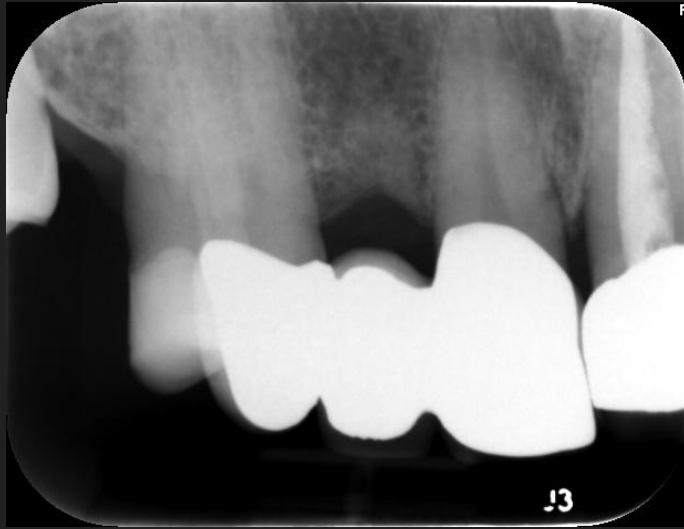# Clinical Findings cont.

Date	Prov./User	Code	Site	Surf.	Stat	Pre-Auth	Special li	Emergen	Discipline	Appr. User	Description
07/12/18	M. Zellmer	C3040	21	DOBL	A					M. Vitense	Gross Decay
07/12/18	M. Zellmer	C3050	21	O	A					M. Vitense	Abfraction/Abrasion/Erosion
07/12/18	M. Zellmer	C3050	22	I	A					M. Vitense	Abfraction/Abrasion/Erosion
07/12/18	M. Zellmer	C3050	23	I	A					M. Vitense	Abfraction/Abrasion/Erosion
07/12/18	M. Zellmer	C3050	24	I	A					M. Vitense	Abfraction/Abrasion/Erosion
07/12/18	M. Zellmer	C3050	25	I	A					M. Vitense	Abfraction/Abrasion/Erosion
07/23/18	M. Zellmer	C3020	25	D	A					M. Vitense	Primary Caries
07/12/18	M. Zellmer	C3050	26	I	A					M. Vitense	Abfraction/Abrasion/Erosion
07/23/18	M. Zellmer	C3020	26	M	A					M. Vitense	Primary Caries
07/12/18	M. Zellmer	C3050	27	I	A					M. Vitense	Abfraction/Abrasion/Erosion
07/12/18	M. Zellmer	C3050	28	O	A					M. Vitense	Abfraction/Abrasion/Erosion
07/12/18	M. Zellmer	D2391	28	B	E					M. Vitense	Resin-based comp-1 surf, post.
08/08/18	M. Zellmer	C3030	28	B	A					M. Vitense	Recurrent Caries
07/12/18	M. Zellmer	C4052	31		A					M. Vitense	Furcation Class II
07/12/18	M. Zellmer	D2750	31	MODBL	E					M. Vitense	PFM high noble metal crown

# Initial presentation



# Specific Findings





# Periodontal Charting

																MOBILITY
	P P P			P P P	P		P P P			P		P P				FURCA
	B B						B									PLAQUE
	4 4 4			8 8 8	7 7 7		7 7 7	7 7 7	7 7 7	6 6 6		6 6 6				BOP
	4 6 6			4 4 3	2 2 2		3 4 3	3 3 3	3 3 2	2 2 3		3 3 2				MGJ
	3 5 5			2 2 3	2 2 2		1 3 3	3 3 3	3 2 2	2 2 3		2 2 2				CAL
	1 1 1			2 2 0	0 0 0		2 1 0	0 0 0	0 1 0	0 0 0		1 1 0				P.D.
																FGM
1	2	3	4	5	6	7	8	9	10	11	12	13	14	15	16	
	0 1 0			1 0 0	0 1 2		1 0 0	0 0 0	1 2 1	0 0 0		0 0 0				FGM
	4 3 7			2 2 3	3 2 2		2 2 3	3 2 2	1 2 3	2 2 3		3 3 4				P.D.
	4 4 7			3 2 3	3 3 4		3 2 3	3 2 2	2 4 4	2 2 3		3 3 4				CAL
																MGJ
	B											B				BOP
	P P P			P P P	P P P		P P P	P	P P P							PLAQUE
																FURCA
																PROGNOSIS
																PROGNOSIS
	P				P P P		P P P	P P P	P P P							FURCA
								B B	B	B						PLAQUE
	7 7 7				4 4 4			3 3 3	3 3 3	3 3 3						BOP
	3 2 2				8 4 3			3 3 2	2 3 2	2 4 4						MGJ
	3 2 2				3 2 2			1 1 2	2 1 2	2 2 1						CAL
	0 0 0				5 2 1			2 2 0	0 2 0	0 2 3						P.D.
																FGM
32	31	30	29	28	27	26	25	24	23	22	21	20	19	18	17	
	0 1 1				3 2 1			0 0 0	0 0 0	0 1 0						FGM
	3 3 3				3 2 2			2 2 3	3 2 3	3 2 2						P.D.
	3 4 4				6 4 3			2 2 3	3 2 3	3 3 2						CAL
	3 3 3				4 4 4			4 4 4	6 6 6	3 3 3						MGJ
	B				B			B								BOP
	P P P				P P P			P P	P P P	P P P						PLAQUE
																FURCA
																MOBILITY

# Diagnosis

Chronic periodontitis ADA II

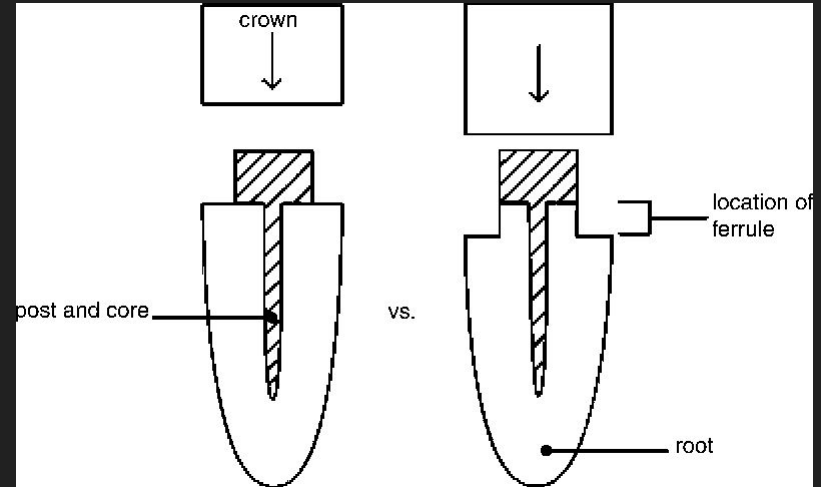
Localized Severe ( $\geq 5\text{mm}$ ) CAL: #2, 27

# Problem List

- Caries
- Home Care

# Ferrule In Dentistry

- Ferrule is defined as a metal ring that strengthens something and prevents it from splitting or wearing
- In dentistry this can be the crown encircling the remaining supragingival tooth structure (Ausiello et al., 2017)
- Provides better resistance to lateral and lever forces, protecting remaining tooth structure against fracture
- 2mm is the accepted ferrule height and width at Marquette

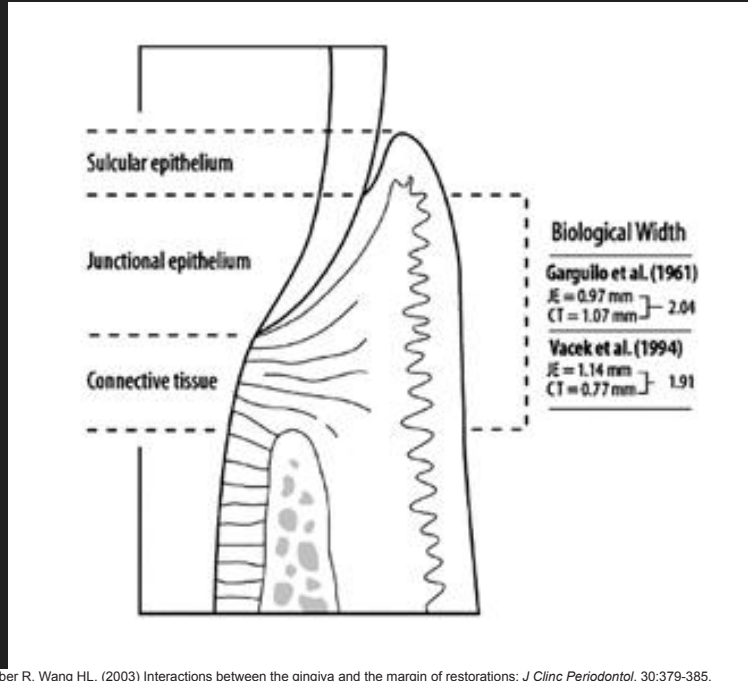


Stankiewicz, N., & Wilson, P. (2002). The ferrule effect: a literature review. *International endodontic journal*, 35 7, 575-81.

Ausiello P, Ciaramella S, Martorelli M, Lanzotti A, Zarone F, Watts DC, Gloria A. Mechanical behavior of endodontically restored canine teeth: Effects of ferrule, post material and shape. *Dent Mater*. 2017 Dec;33(12):1466-1472. doi: 10.1016/j.dental.2017.10.009. Epub 2017 Nov 7. PMID: 29126633.



# Biologic Width

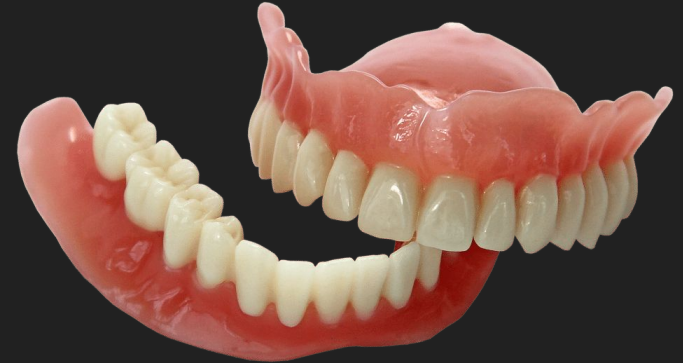
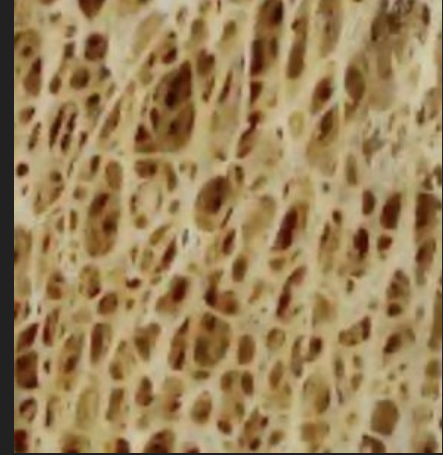
Padbury, A, Eber R, Wang HL. (2003) Interactions between the gingiva and the margin of restorations: *J Clin Periodontol*. 30:379-385.

- Attachment of the periodontium to the tooth above the bone
- Made up of the Junctional Epithelium and Connective Tissue attachment
- Impeding the biologic width results in inflammation, pocket formation, gingival recession, and bone loss as the body tries to recreate the 2.0 mm BW (Oh, 2010)

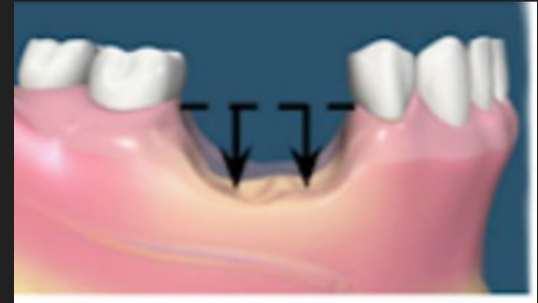
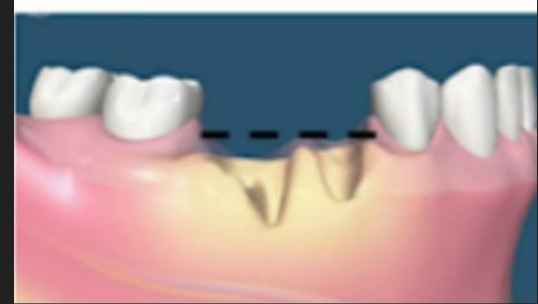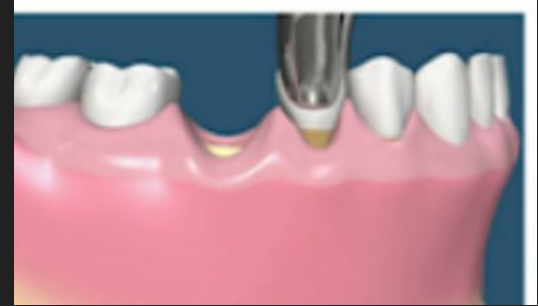# Bone Resorption

- Faster and more dramatic changes in mandible
- Cancellous Bone
- Dentures
  - Maxillary Denture Area: 4.2 sq inches
  - Mandibular Denture Area: 2.3 sq inches



# Bone Resorption

- Reduction:
  - Year 1: Mandible ridge reduction 2:1 compared to Maxilla
  - Year 7: Mandible 4:1 compared to Maxilla
- Rate:
  - Mandible: 2 times rate of Maxilla
- Location:
  - Maxilla: evenly around dental arch
  - Mandible: labiolingual and vertically



# D3 PICO

- Clinical Question:
- What treatment plan options should be considered when replacing maxillary anterior teeth/tooth in patients with a high smile line and (excessive resorption) bony defect of the maxillary ridge?

# D3 PICO

- Clinical Question:
- What treatment plan options should be considered when replacing maxillary anterior teeth/tooth in patients with a high smile line and (excessive resorption) bony defect of the maxillary ridge?

# PICO Format

P: Patients with missing teeth a high smile line and bone resorption

I: Fixed partial denture

C: Implant

O: Papilla thickness and tissue regarding esthetics

# PICO Formatted Question

- In patients with missing teeth/tooth that have a high smile line and resorption will a FPD or implant yield a more esthetic result?

# Clinical Bottom Line

- More research needs to be done to most effectively compare the two modalities of treatment
- Both yield similar results when comparing papilla thickness and tissue regarding esthetics although implants are more technique sensitive



# Search Background

- Date(s) of Search: 10.20.20 & 10.22.20
- Database(s) Used: PubMed
- Search Strategy/Keywords: Maxillary anterior esthetics, Fixed partial denture, Missing teeth, Implants, tissue esthetics

# Search Background

- MESH terms used: *dental implants, single tooth; dental prosthesis, implant-supported; tooth loss/rehabilitation, maxilla, esthetics dental*

# Article Cited

- Meyenberg, K., Imoberdorf, M.(1997). The aesthetic challenges of single tooth replacement: A comparison of treatment alternatives. Retrieved October 27, 2020, from <https://pubmed.ncbi.nlm.nih.gov/9743679/>

- Study Design: Case series

# The aesthetic challenges of single tooth replacement: a comparison of treatment alternatives

- Three clinical case studies used to compare the esthetics between different treatment modalities in the anterior maxilla
- Case 1: Single implant
  - Pt presents non-restorable maxillary right central incisor
  - Thick tissue morphotype, small to medium size defects on alveolar ridge, excellent motivation and compliance noted
  - Txt: Ext of maxillary right incisor, GBR and GTR, single implant to address missing incisor
- Case 2: Adhesive Bridge-Unrelated to PICO
- Case 3: Fixed partial denture(PFM)
  - Pt presents w/ periodontal involvement and protrusion of maxillary anterior teeth
  - Txt: 6-unit bridge w/ ovate pontics to support buccal soft tissue and papillae using slight pressure

# The aesthetic challenges of single tooth replacement: a comparison of treatment alternatives

Fixed partial denture:

- Ovate pontic- hygiene
- Insufficient keratinized tissue- tissue augmentation w/provisional

Single tooth implant:

- Emergence profile-cervical vs emerging
- Adaptability to horizontally flat bone

Soft tissue contouring for implants

- Healing abutment
- Provisional restoration
- Final prosthesis

Neither was found to be superior over the other in relation to papilla thickness and tissue esthetics. They each yielded successful esthetic outcomes in replacing maxillary anterior teeth when either tissue contouring, and or bone grafting were performed.

Conclusion: There are challenges and indications alongside each treatment modality depending on the unique complications each patient presents with. Both can yield similar excellent esthetic outcomes although implants tends to be more technically demanding.

Limitations:

The article uses only three clinical case studies to reinforce their ideas of what makes a conventional bridge or implant esthetically successful. Data is also a bit dated being from 1997. More recently, techniques may be more predictable or improved since then.


# Reason for Article Selection

- Addressed PICO question in terms of the challenges each treatment modality faces in order to achieve esthetic success

# Article Cited

- Studer, S., Pietrobon, N., & Wohlwend, A.(1994, January). Maxillary anterior single-tooth replacement: Comparison of three treatment modalities. Retrieved October 27, 2020, from <https://pubmed.ncbi.nlm.nih.gov/8180370/>
- Study Design: Clinical practice guideline

# Maxillary anterior single-tooth replacement: comparison of three treatment modalities

- Clinical practice guideline from 1994
  - Factors when choosing a treatment modality
    - Predictability of aesthetic outcome
    - Preservation of tooth structure
    - Preservation of periodontal tissue/ alveolar bone
    - Prospective treatment issues
- 
- Pertaining to  
esthetics
- Fixed partial dentures:
    - High predictability of aesthetic success
    - Irreversible loss of dentin and enamel
    - Subgingival crown margins greater than 2mm
    - Difficult to preserve periodontal health during and after treatment
  - Implants
    - With increasing predictability of osseointegration it can be aesthetically successful but often may be unsatisfactory if soft tissue isn't managed appropriately
    - Adjacent teeth structure untouched
    - Periimplant tissue susceptibility to gingivitis and periodontal breakdown-apical extension
    - Surgical intervention and extended recovery time often needed-to address bone and tissue deficiencies and allow for osseointegration



# Maxillary anterior single-tooth replacement: comparison of three treatment modalities

Indication for using a conventional PFM bridge is when adjacent teeth are affected by carious lesions or have existing restorations that are extensive. If preservation of hard tissue is of great concern, then an implant may be an appropriate treatment modality.

## Conclusion:

Single-tooth implants in aesthetically driven regions should be considered with caution due to additional surgical interventions and requirements such as sufficient bone and soft tissue manipulation. Patients need to also consider the additional time needed for recovery and osseointegration. A conventional partial bridge is more aesthetically predictable in most cases.

## Limitations:

This review is dated being from 1994 and relies on expert opinion of a few rather than analyzing a larger population to make a stronger case for these evolving treatment modalities.

# Reason for Article Selection

- Pertained to the PICO
- Compared the available treatment modalities and based on various factors determined how one was more technique sensitive

# Article Cited

- Hebel, K., Gajjar, R., & Hofstede, T. (2000). Single-Tooth Replacement: Bridge vs. Implant-Supported Restoration. Retrieved October 27, 2020, from <http://www.cda-adc.ca/jcda/vol-66/issue-8/435.html>
- Study Design: Clinical practice guideline

# Single-Tooth Replacement: Bridge vs. Implant-Supported Restoration

- A clinical practice guideline from 2000
- Fixed partial denture:
  - Significant reduction of abutment teeth needed
  - Subgingival margins needed for esthetic cases
  - Lack of bone support and demineralization of adjacent teeth are indications
- Implants:
  - Osseointegration of implants has become more predictable
  - Preserve tooth structure of adjacent teeth
  - More demanding to achieve esthetic success if inadequate bone and soft tissue

# Single-Tooth Replacement: Bridge vs. Implant-Supported Restoration

## Conclusions

- Esthetic predictability of a 3 unit-bridge is excellent and doesn't require as much time compared to implants
- If one part of a PFM bridge fails, the entire restoration is more at risk
- Better prognosis of adjacent teeth in implants because they are untouched
- Implants are more technically demanding but advances in technology have allowed implants to have the edge when it comes to restoring a single tooth in terms of developing great esthetics and overall longevity.

## Limitations:

The article is no longer current being from the year 2000 and doesn't specify what advances in technology give implants greater esthetics and longevity.

# Reason for Article Selection

- High level of evidence directly comparing the two treatment modalities and touches on aesthetic success with emerging technology giving one treatment an edge

# Levels of Evidence

- ☒ **1a** – Clinical Practice Guideline, Meta-Analysis, Systematic Review of Randomized Control Trials (RCTs)
- ☐ **1b** – Individual RCT
- ☐ **2a** – Systematic Review of Cohort Studies
- ☐ **2b** – Individual Cohort Study
- ☐ **3** – Cross-sectional Studies, Ecologic Studies, “Outcomes” Research
- ☐ **4a** – Systematic Review of Case Control Studies
- ☐ **4b** – Individual Case Control Study
- ☒ **5** – Case Series, Case Reports
- ☐ **6** – Expert Opinion without explicit critical appraisal, Narrative Review
- ☐ **7** – Animal Research
- ☐ **8** – In Vitro Research

# Strength of Recommendation Taxonomy (SORT)

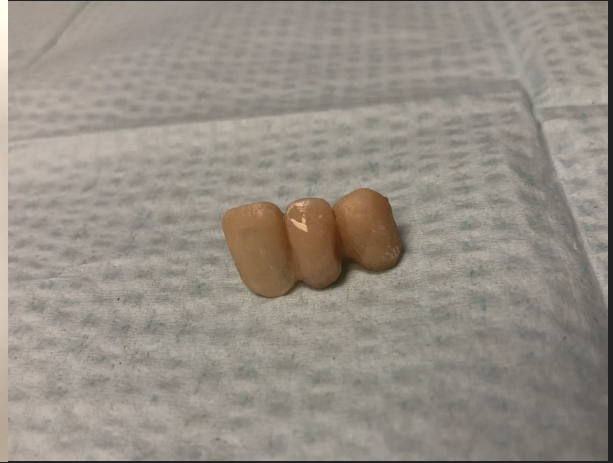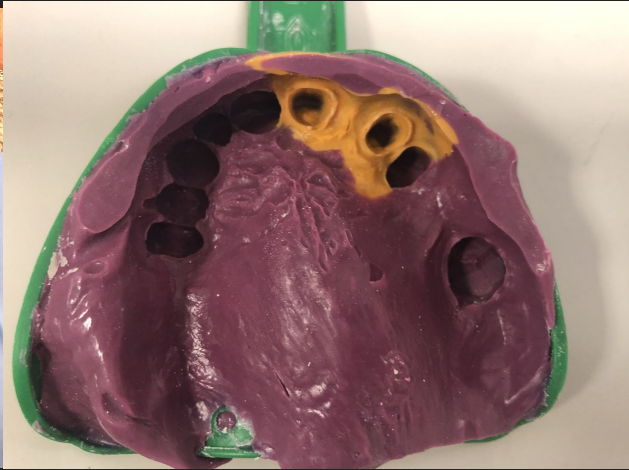
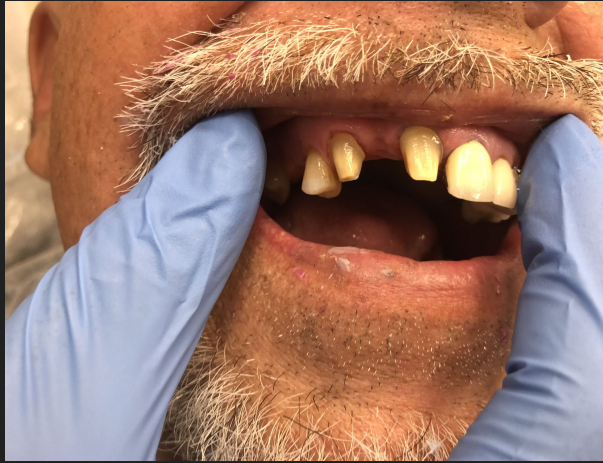<input type="checkbox"/>	<b>A</b> – Consistent, good quality patient oriented evidence
<input checked="" type="checkbox"/>	<b>B</b> – Inconsistent or limited quality patient oriented evidence
<input type="checkbox"/>	<b>C</b> – Consensus, disease oriented evidence, usual practice, expert opinion, or case series for studies of diagnosis, treatment, prevention, or screening



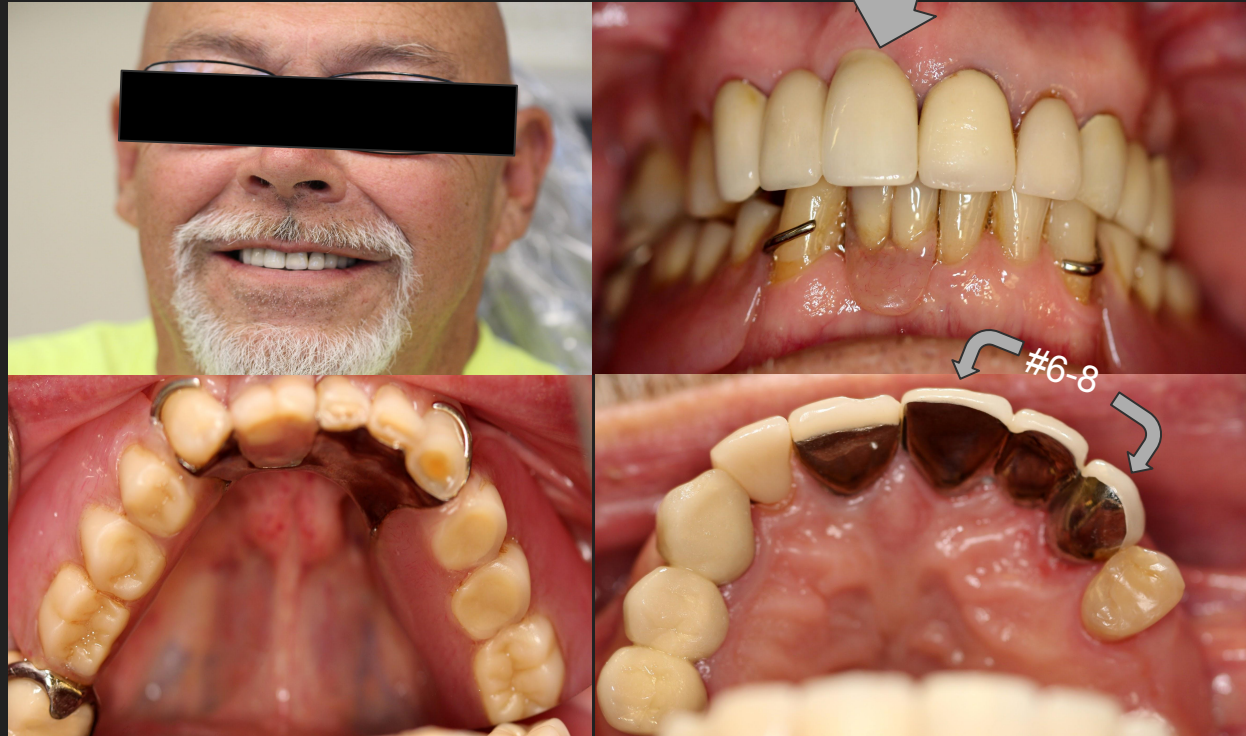# Conclusions

- Conventional bridges and implants were determined to have similar esthetic results
- Implants tend to be more technically demanding but preserves adjacent tooth structure
- The articles presented conflicting results comparing esthetics between the two treatment modalities
- Not many studies directly compare papilla thickness and tissue esthetics for the different treatment modalities when replacing missing teeth
- More long term follow up is needed to determine if one yields a more esthetic result over the other

# Prep and provisionalize



# Insertion outcome



# Conclusions: D4

Given the many different treatment options to provide a more esthetic outcome, more research needs to be provided.

Given this patient's circumstances, we decided a PFM would be ideal given his budget, existing PFM in anteriors and timeline for the patient.

# Discussion Questions

- 1-2 slides
- List posted discussion questions
- Questions may also be from Group Leader or Specialist

# Discussion Questions

# THANK YOU

