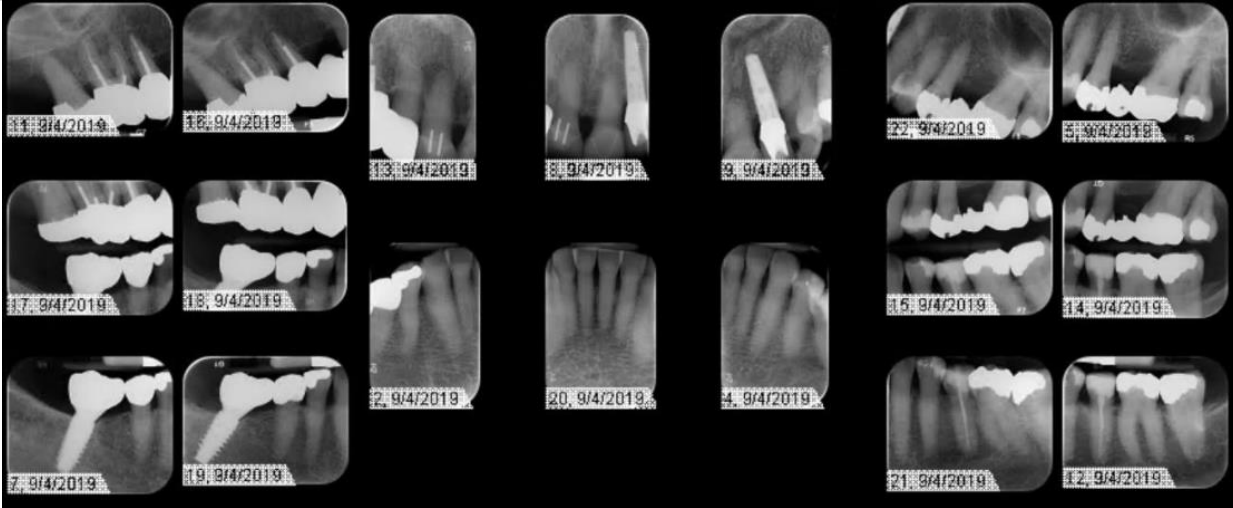


MUSoD Rounds
D4 Case Information

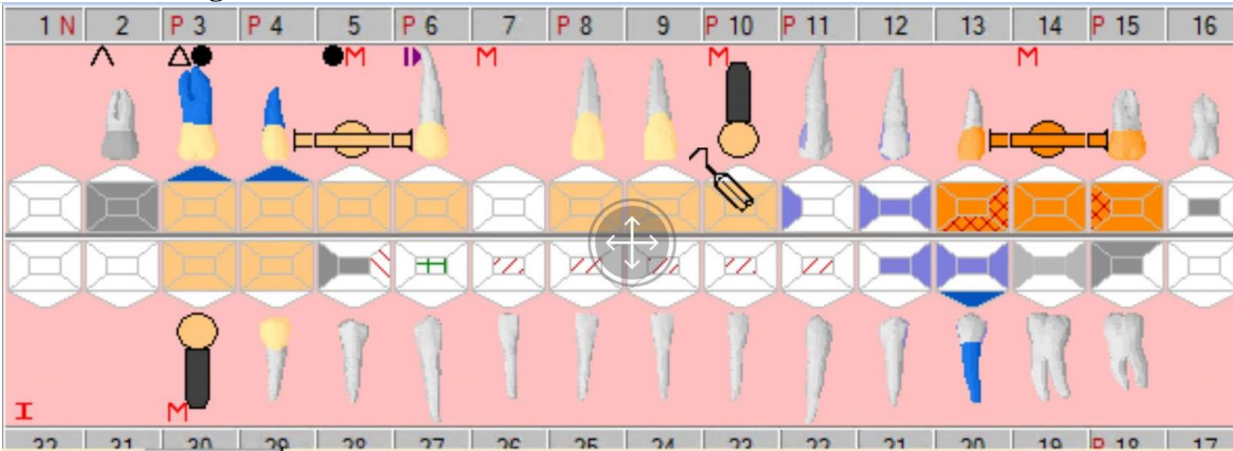
Student Name:
Furqaan Siddiqui
Case abstract (Provide a brief synopsis of this patient):
Patient presented to Marquette University School of Dentistry for Comprehensive Dental Care upon moving back to WI. Patient was previously a patient until 2009 when she moved to Florida. Patient presented with Deep Pockets and Calculus across Upper Maxilla with significant bone loss. Patient also had recurrent caries below an existing amalgam on #19, and below a bridge from #13-15. Patient underwent S/RP and Periosteal Maintenance for Periodontitis treatment. #19 Caries were removed and restoration was replaced. The plan was to section the bridge and determine whether #13 and #15 would be restorable, and what treatment options would then be available to the patient. Due to patients age, she did not want to spend money on implants, and wanted a restoration that “would last”. Upon sectioning the bridge, #13 was deemed non restorable due to extent of the decay and bone loss and will plan to be extracted. #15 was deemed restorable and patient is now deciding what treatment to go with to restore #15 and the edentulous area.
axiUm Chart:
696692
Date of Rounds presentation:
11-18-2020
D3 Student:
Zoe Vainikos
D2 Student:
Payton TeDuits
D1 Student:
Ana Hernandez
Medical History:
Past Smoker Radiation Therapy for Benign Pre-Cancerous Lesion on Nose in 2006 Arthritis Medications: Spectravite Adult 50+ Multivitamin 1 Tablet after breakfast Glucosamine Chondritin Dietary Supplement 1 Caplet after Breakfast Vitamin D3 2000 IU 1 soft get after breakfast Fiber Gummies Daily Supplements 1 per day after breakfast
Dental History:
Deep Pockets Plaque Calculus Brushes Twice Daily and Flosses Once a Day Previous RCT on 3, 4, 20 Maxillary Bridge 4-6 and 13-16 placed 60+ years ago Implant #30

Radiographic Findings:



Missing Teeth: #1, #7, #14, #31, #32
 Bridge from #4-6 with 6 replacing #7 in the arch
 Caries: #18M Recurrent, #11M, #13D Recurrent, #15 Recurrent
 Furcations: #3 Class 2
 PARL: #3 MB Root, Large PARL between #20 and #21

Clinical Findings:



Caries: #18M-RC, #13D-RC, #15 Recurrent
 Incisal Wear: 22-26
 Fracture: #27-I, smooth
 RCT: #3, #4, #20
 Crowns: #3, #8, #9, #30
 Bridges: #4-6, #13-15
 Implant: #30
 Prior Restorations: #2MODBL Amalgam, #11M Resin, #12MOD Resin, #16O Amalgam, #18MOL Amalgam, #19MOD Resin, #20MOD Resin, #21DO Resin, #28DO Amalgam

Periodontal Findings:

Condition Clinical Attachment Loss																Print
1	2	3	4	5	6	7	8	9	10	11	12	13	14	15	16	
	5 5 3	6 3 3	4 3 3		7 3 2		2 2 3	2 1 2	3 2 7	7 3 3	2 2 3	3 4 4		6 3 5	6 3 3	
	3 4 3	5 5 4	4 2 5		5 2 2		2 2 4	3 1 2	3 5 4	3 1 2	2 1 2	2 1 2		3 2 4	3 3 3	
0 0 0	2 1 0	1 2 1	0 1 2	0 0 0	2 1 0	0 0 0	0 0 1	1 0 0	0 3 3	4 2 1	0 1 1	1 3 2	0 0 0	3 1 1	3 0 0	
	4 2 3	3 3 3	3 3 6		5 6 3		2 2 3	2 1 2	3 5 4	7 3 3	3 3 3	3 3 2		7 3 4	7 3 3	
	3 2 3	2 2 2	3 2 4		7 1 2		2 2 3	2 1 3	3 3 4	6 2 2	2 2 3	2 3 3		2 2 3	3 2 2	
0 0 0	1 0 0	1 1 1	0 1 2	0 0 0	2 5 1	0 0 0	0 0 0	0 0 1	0 2 0	1 1 1	1 1 0	1 0 1	0 0 0	5 1 1	4 1 1	
		2 2 1	1 1 1	1 1 2	1 1 1	2 2 1	2 3 2	2 2 1	1 1 1	1 1 1	2 1 1	2 1 2	3 2 2	2 2 2		
		1 1 2	2 1 3	3 2 2	1 1 1	1 2 1	1 3 1	1 2 1	1 1 1	2 1 1	2 1 1	2 1 1	2 2 2	2 2 2		
0 0 0	0 0 0	1 1 1	1 0 2	2 1 0	0 0 0	1 0 0	1 0 1	1 0 0	0 0 0	1 0 0	0 0 0	0 0 1	1 0 0	0 0 0	0 0 0	
		2 2 1	1 3 2	2 2 1	2 2 1	2 2 2	2 1 1	1 2 2	2 2 1	4 4 3	3 1 1	3 1 2	2 1 3	3 3 5		
		2 2 1	2 1 3	2 1 1	1 2 2	2 2 1	1 1 1	1 1 2	3 1 1	2 1 1	1 1 1	2 1 2	2 1 3	3 2 4		
0 0 0	0 0 0	0 0 0	1 2 1	0 1 0	1 0 1	0 0 1	1 0 0	0 1 0	1 1 0	2 3 2	2 0 0	1 0 0	0 0 0	0 1 1	0 0 0	
32	31	30	29	28	27	26	25	24	23	22	21	20	19	18	17	

Enamel Pearl on #2, Grade 1 Furcation on #2, Grade 2 Furcation on #3, Deep Pockets

Periodontal Diagnosis:

IV – Advanced Chronic Periodontitis

Problem List:

Caries
Defective Restorations
Esthetics
Fractured Tooth
Gross Caries
PARL
Perio Disease
Soft Tissue Lesion

Other:

[Click here to enter text.](#)