

**Evidence Based Dentistry Rounds for  
Pediatric Patient with Alagille Syndrome and  
Hypomineralized Teeth  
Specialty: Pediatrics  
Group: 4B-5  
Date: 11/18/20**

---

# Rounds Team

---

- **Group Leader: Dr. Grady**
- **Specialty Leader: Dr. Gonzalez**
- **Project Team Leader: D4 Damon Cole**
- **Project Team Participants:**
  - **D1 Tyler Guist**
  - **D2 Kara Kaltenbrun**
  - **D3 Kimberly Beckford**

# Patient

---

- 9 year old Hispanic male
- Chief Complaint (from mother): "his teeth are always hurting him and look like they have big holes in them"

# Medical History

---

- Medical conditions: Alagille syndrome, short bowel syndrome with G-tube, hereditary hemochromatosis, renovascular hypertension
- Medications: Silapap (acetaminophen), ergocalciferol (Vit. D), lidocaine cream (stop itching/pain), loperamide (reduce stool amount), mephyton (clotting agent), phytonadione (clotting agent), rifampin (antibiotic to prevent infections), tocofersolon (Vit. E), ursodiol (treat biliary cirrhosis)
- Medical Consults: Primary care provider stated pt was healthy enough to receive dental treatments



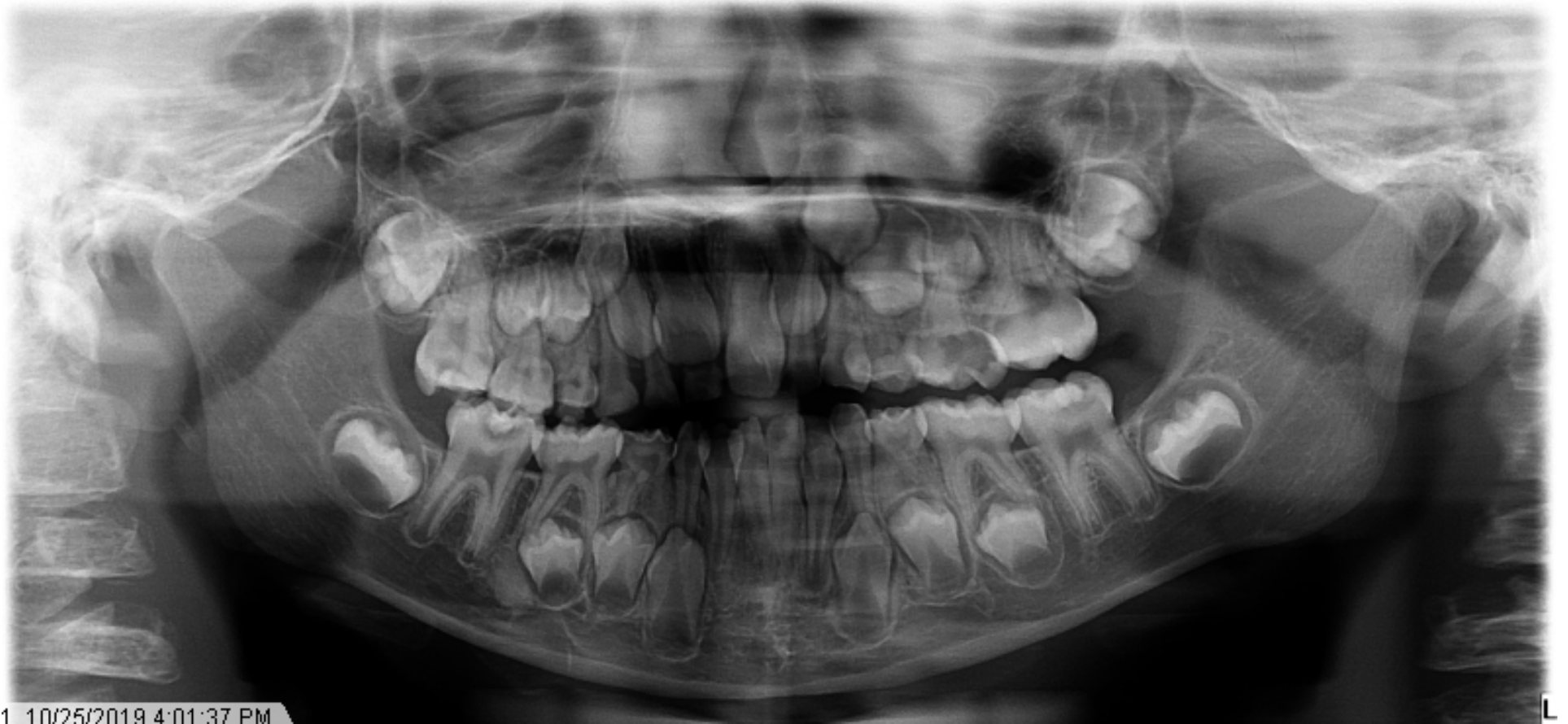
# Dental History

---

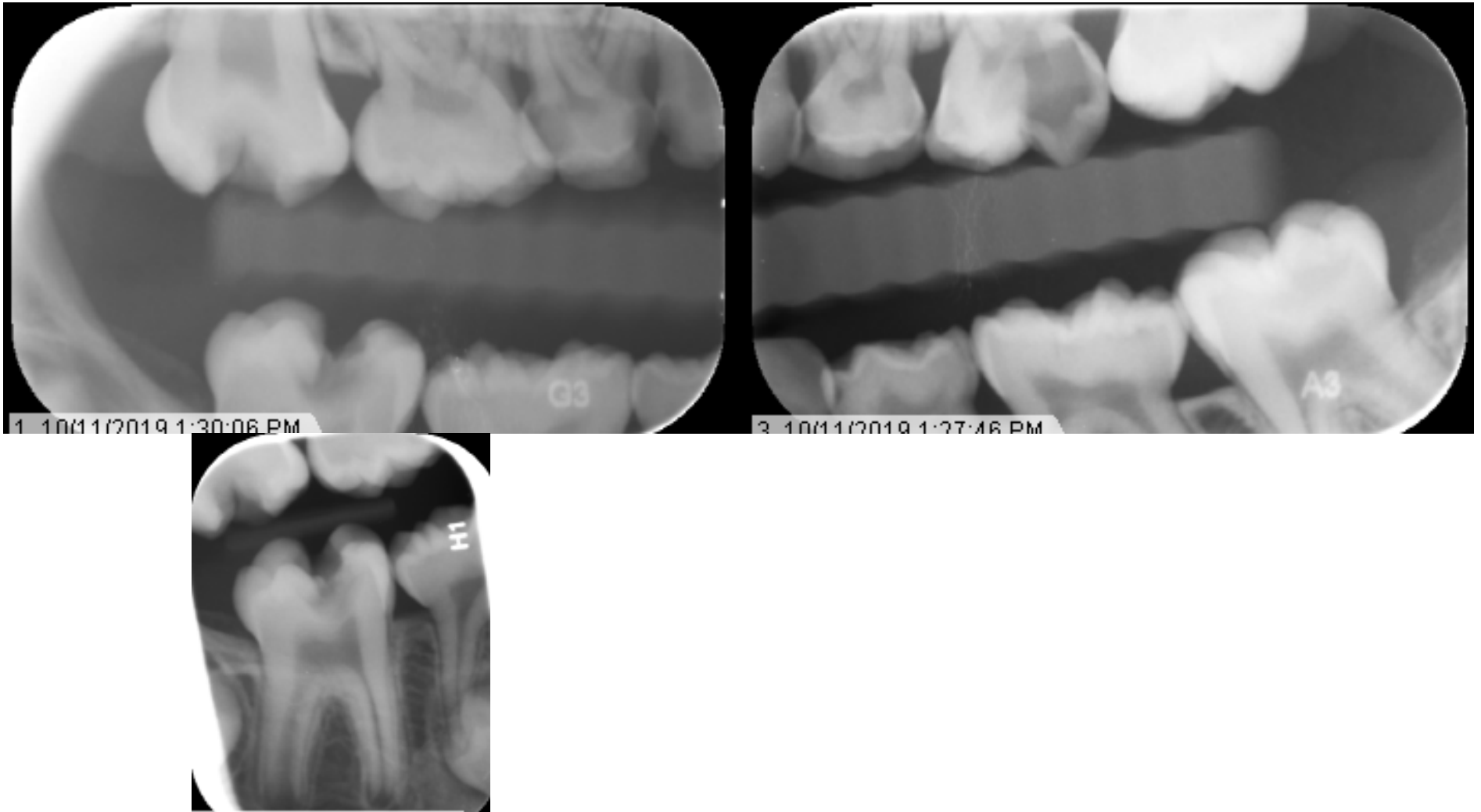
- Regular 1x per year exams and cleanings since 2018
- Pt brushes once per day and never flosses
- Pt unable to sleep due to pain from lower left tooth
- No restorations present before treatment began at MUSoD

# Radiographs

---



# Radiographs



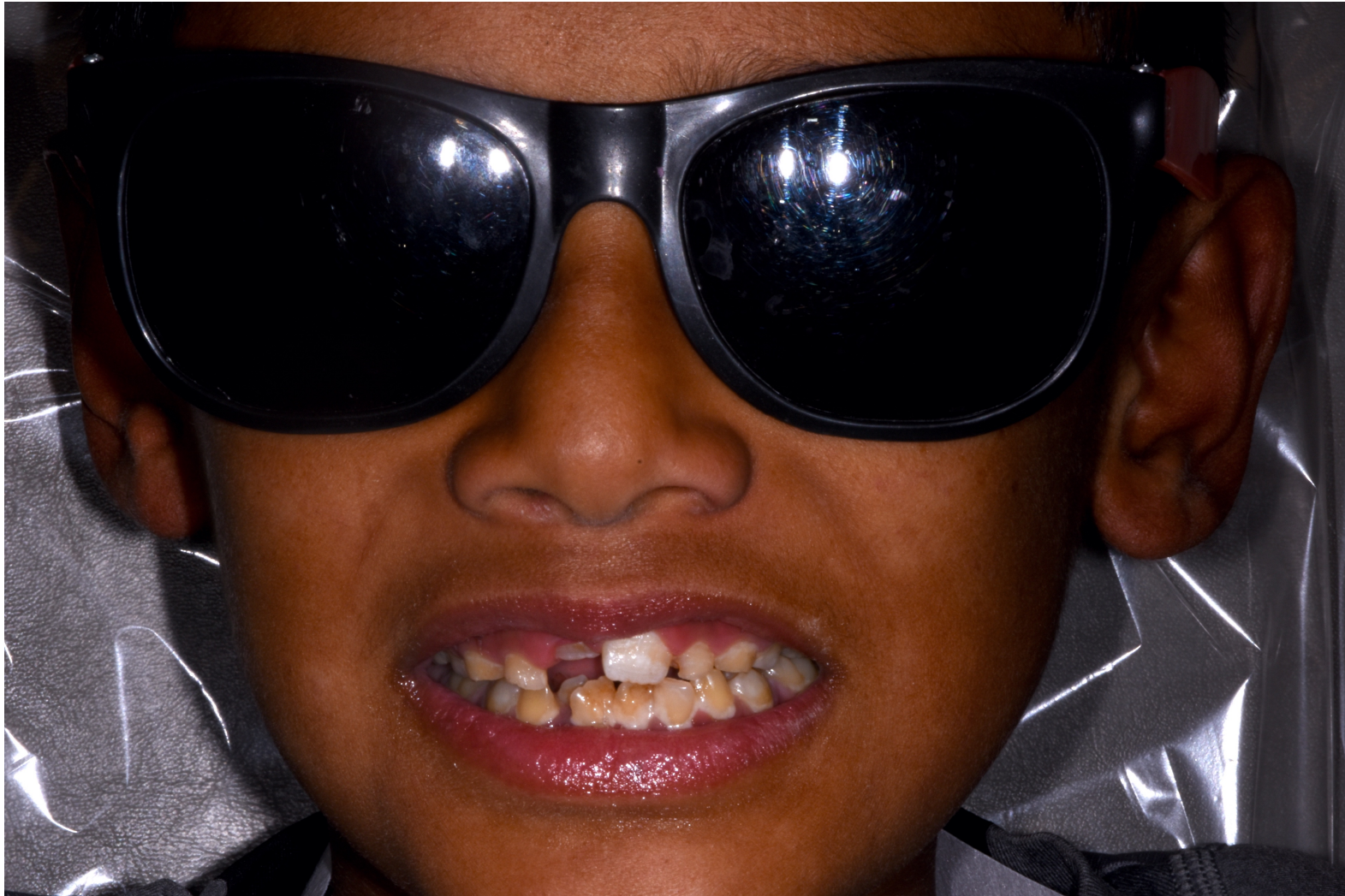# Radiographic Findings

---

- Caries
  - #3 O, #A MO, #B MOD, #C D, #G MLD, #H D, #I MOD, #J gross, #L M, #S MO, #30 OB – open apices

# Clinical Findings

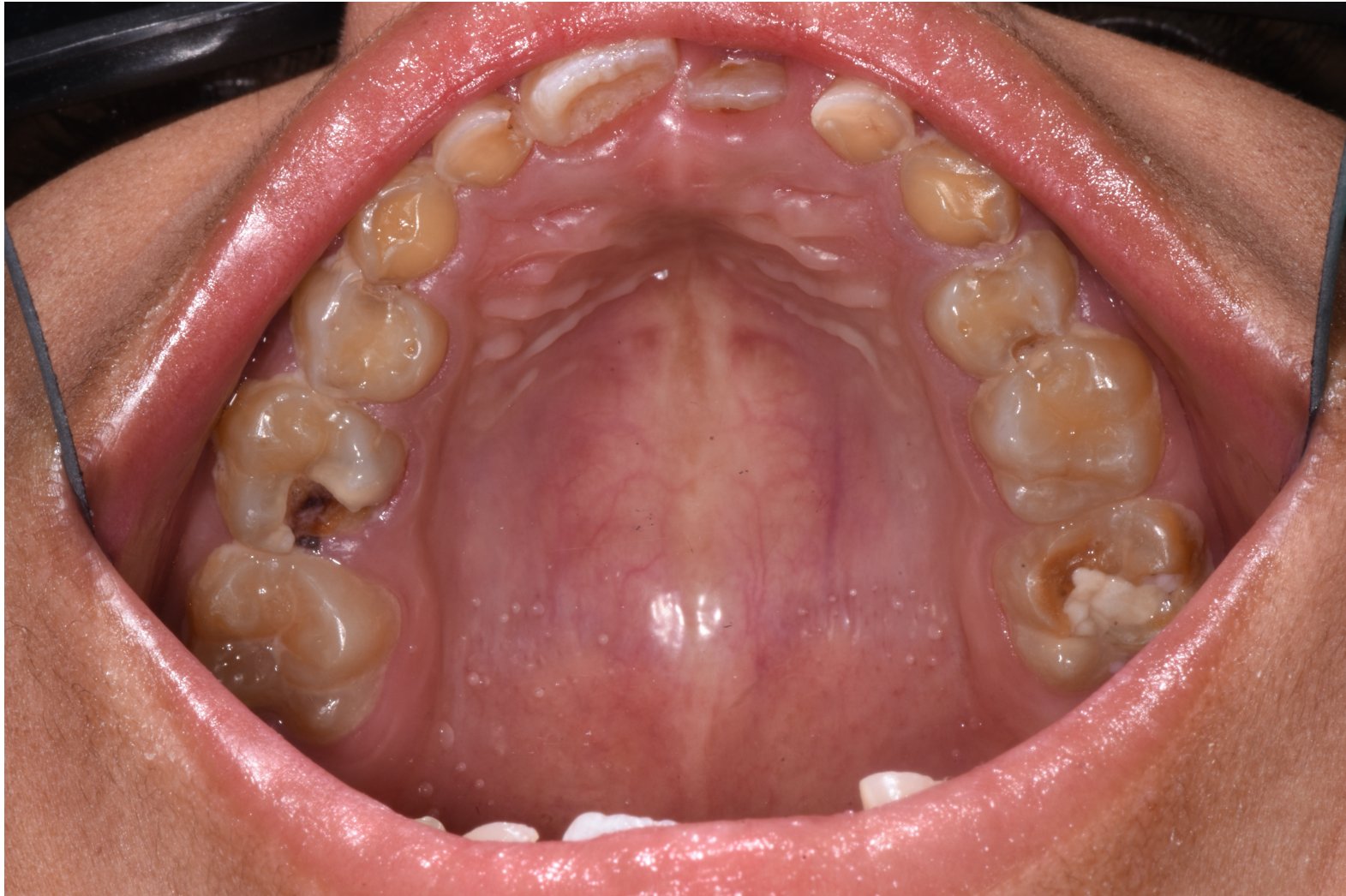---





# Clinical Findings

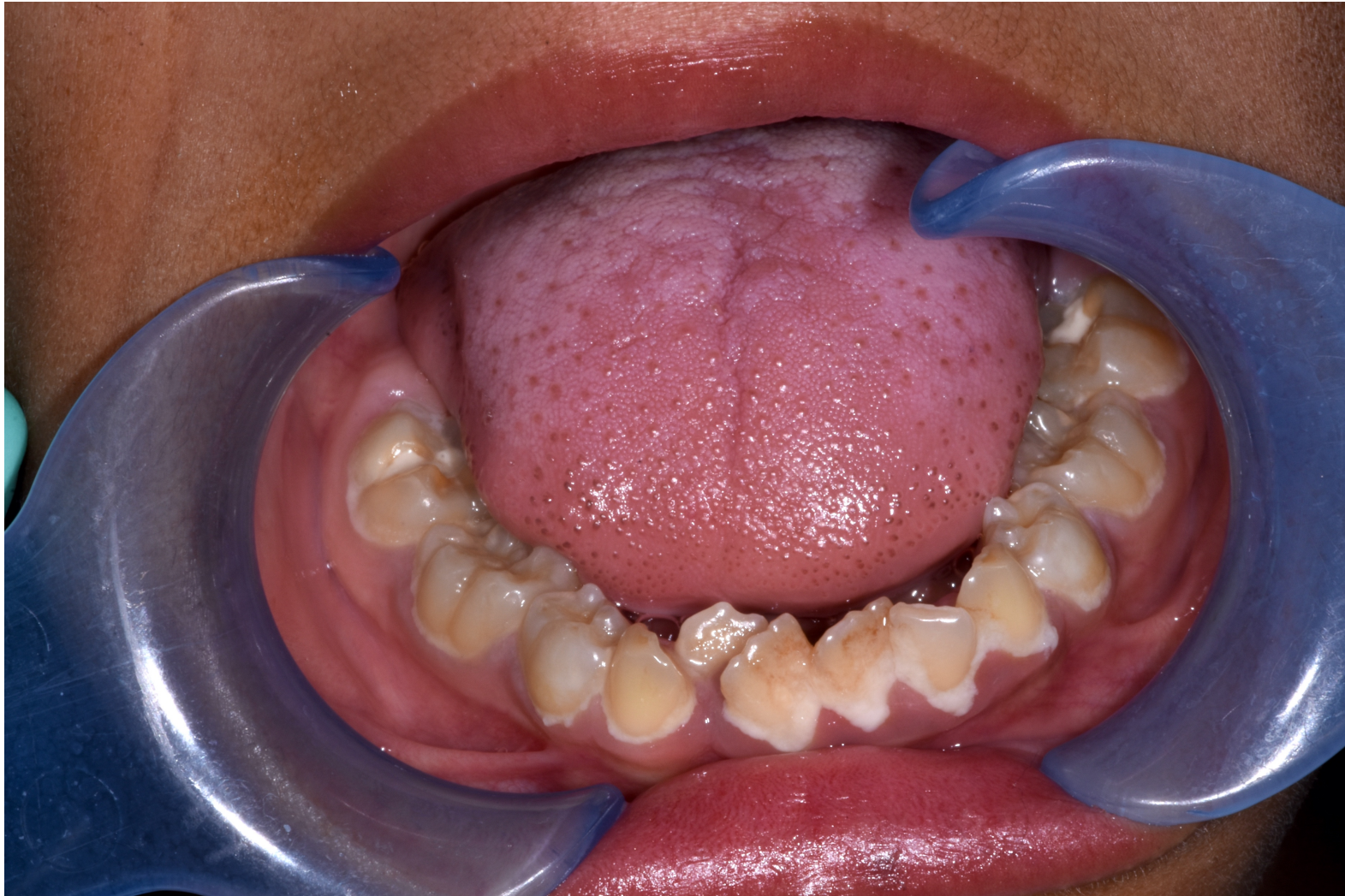---





# Clinical Findings

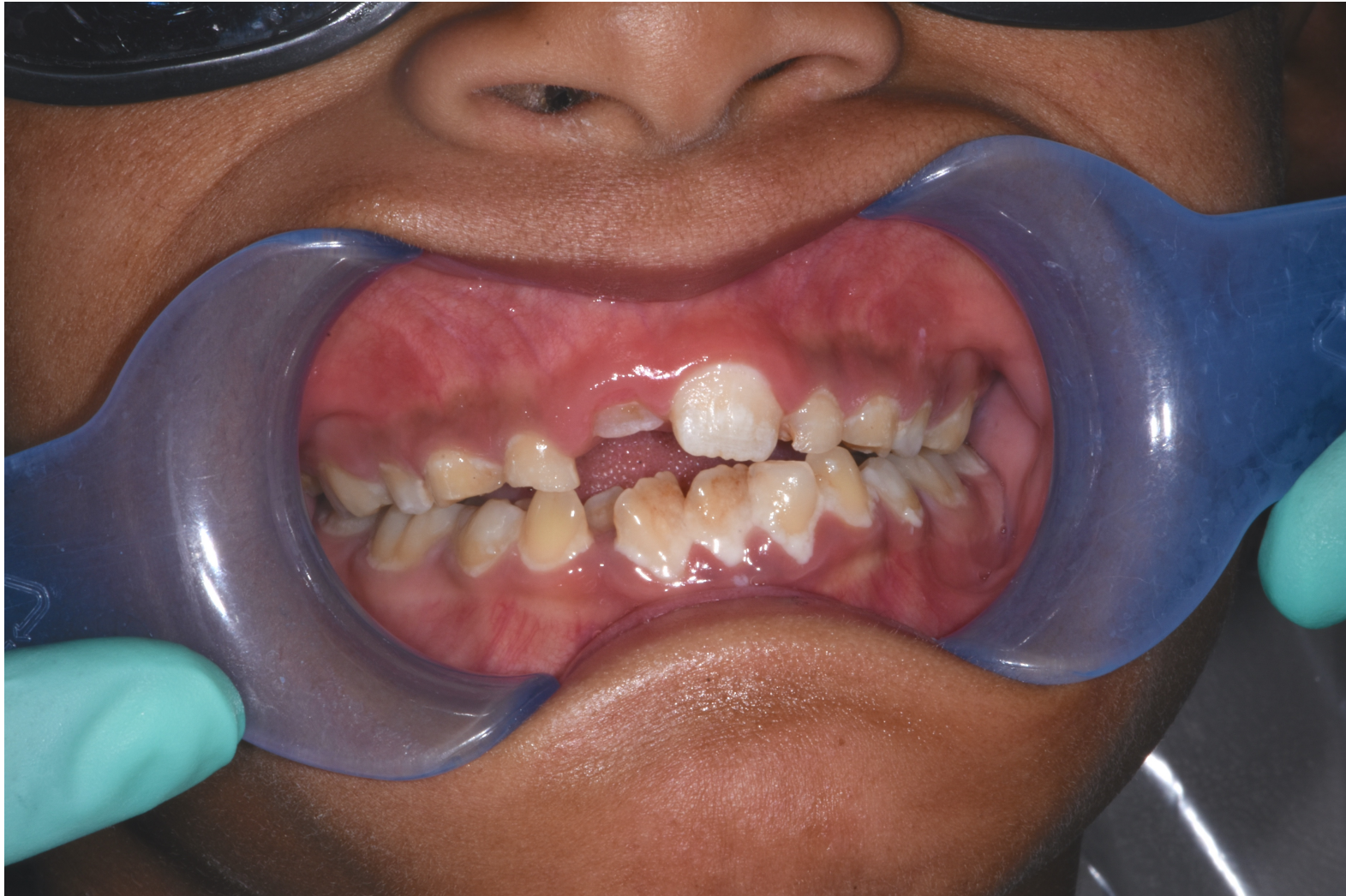---





# Clinical Findings

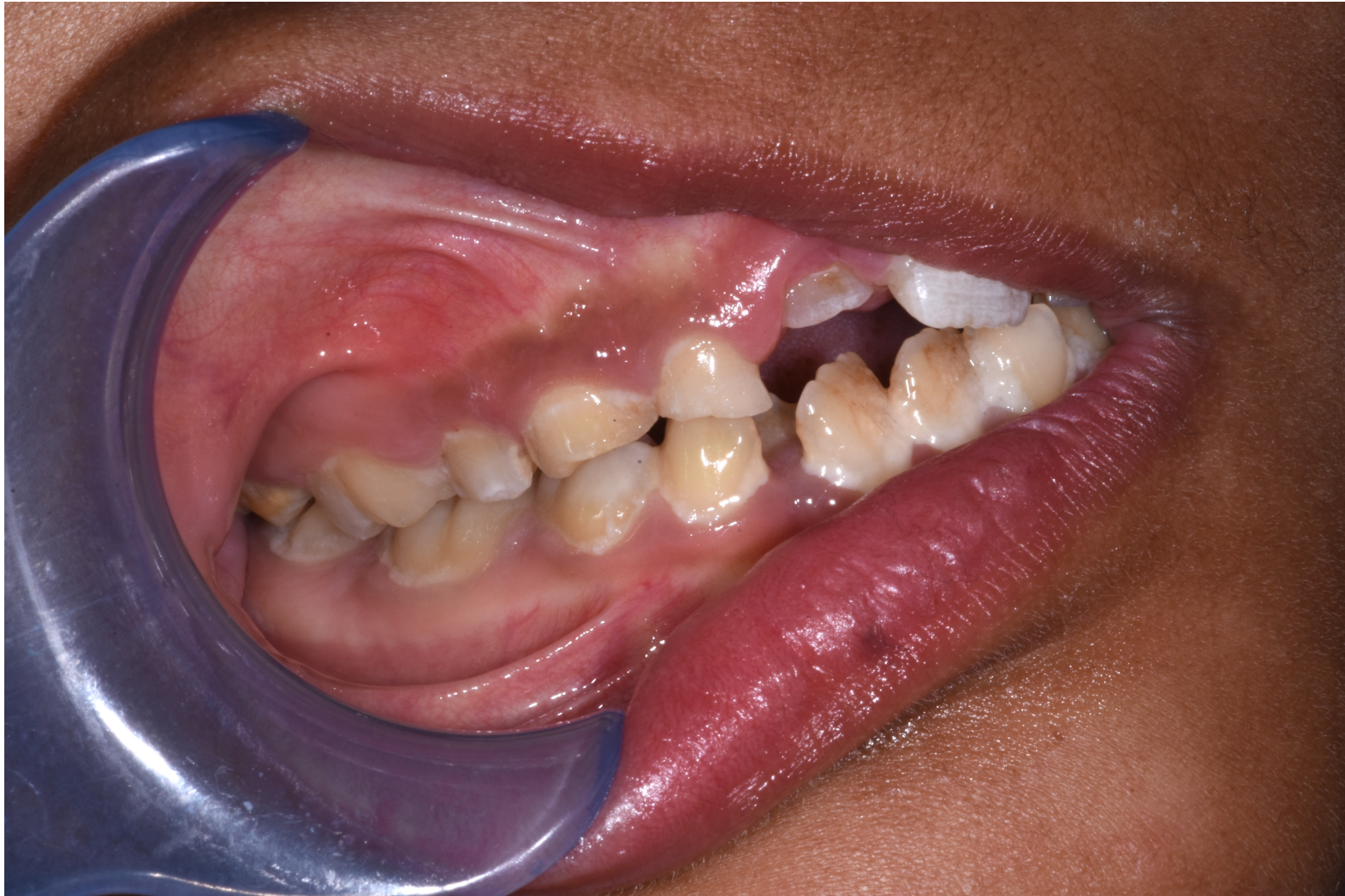---





# Clinical Findings

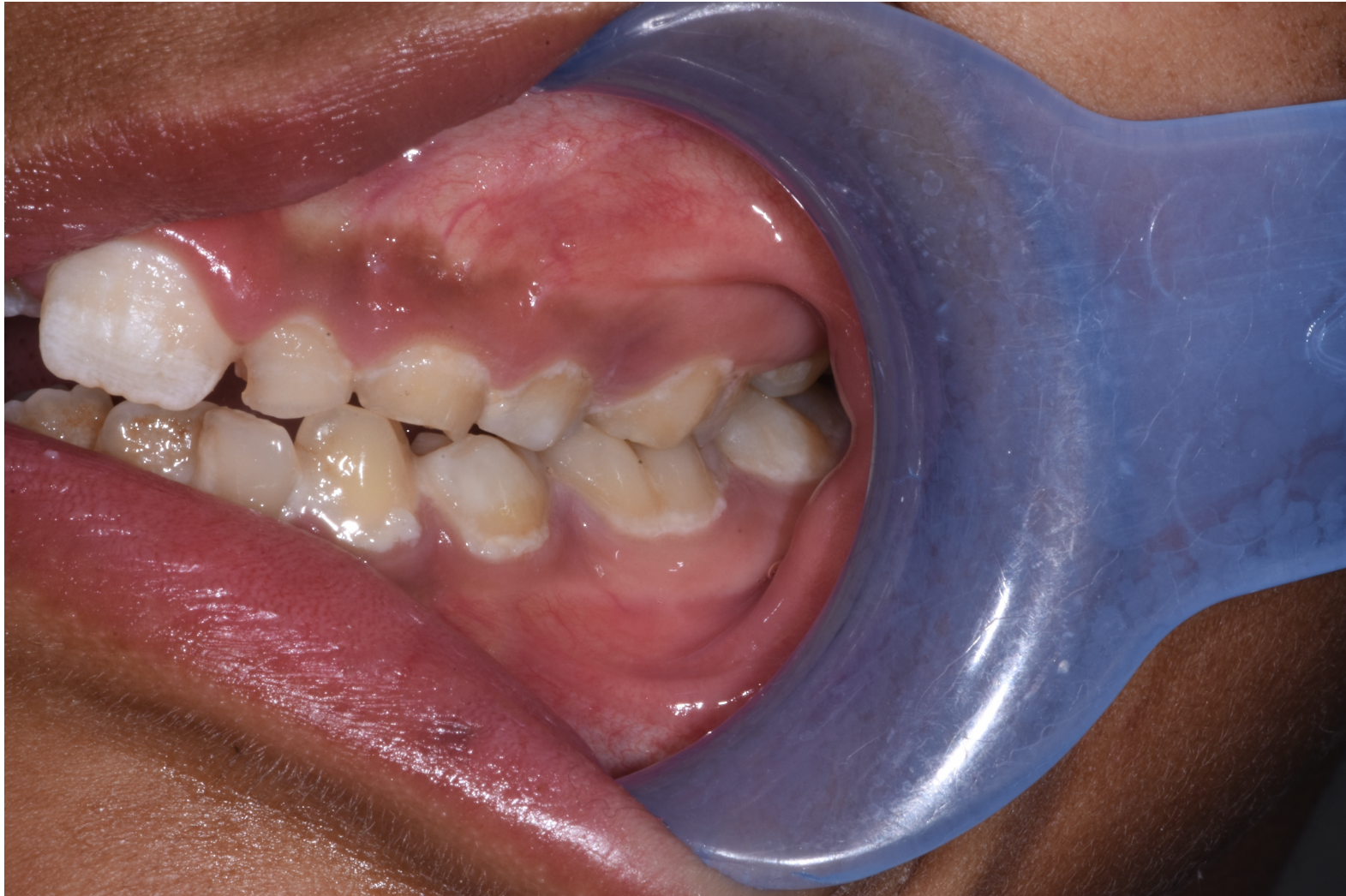---





# Clinical Findings

---



# Clinical Findings

---

- Caries
  - #3 O, #A MO, #B MOD, #C D, #G MLD, #H D, #I MOD, #J gross, #L M, #S MO, #30 OB

# Specific Findings

---

- Generalized, hypomineralized teeth
- Need significant improvement in OH
- Frankl score: 4 (++)

# Diagnosis

---

- Perio diagnosis: Plaque-induced gingivitis
- Caries risk: High

# Problem List

---

- Caries
- Home care
- Sensitivity

# D1 – What is Alagille Syndrome?

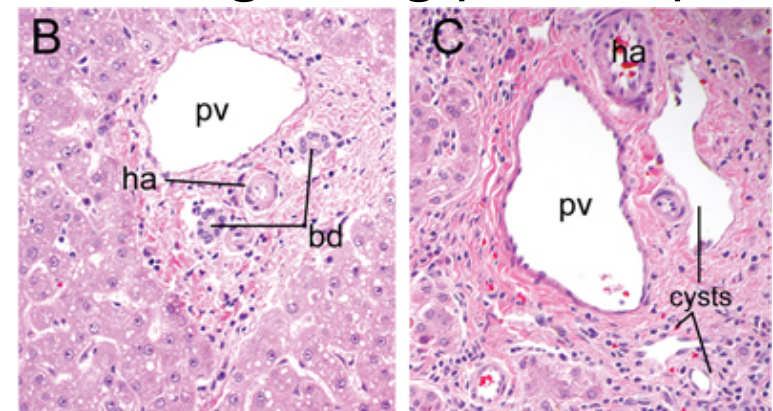
## ■ Overview

- Autosomal dominant (50% chance of inheritance from parents), multisystemic, variable
- JAG1 gene mutation – developmental signaling pathway disruption

- 1 in every 70,000 live births

## ■ Diagnosis

- Histological evaluation of liver
- Genetic testing
- Clinical presentation criteria



adult liver

Alagille syndrome

Zorn, A. M., 2008

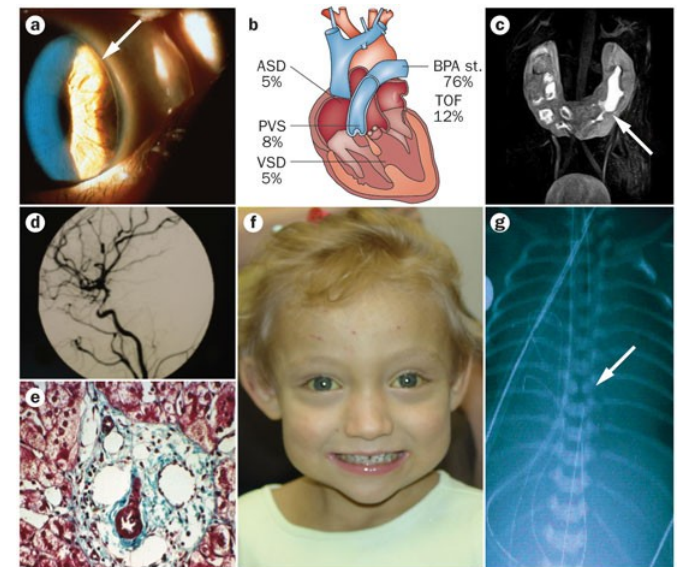
# D1 – What is Alagille Syndrome?

## ■ Clinical Criteria

- Liver (E): decreased small hepatic bile ducts
- Eyes (A/D): posterior embryotoxon (90%)
- Heart (B): murmurs, structural defects (90%)
- Facial abnormalities (F): forehead, deep set eyes, straight nose, pointed chin, large ears
- Skeletal (G): 'butterfly' hemivertebrae (70%)

## ■ Dental Manifestations

- Complication of cholestasis – hyperbilirubinemia
- Enamel opacities, **hypomineralization**, hypoplasia of enamel



Kamath, B., et al., 2013



# D2 Pathology

Kara Kaltenbrun

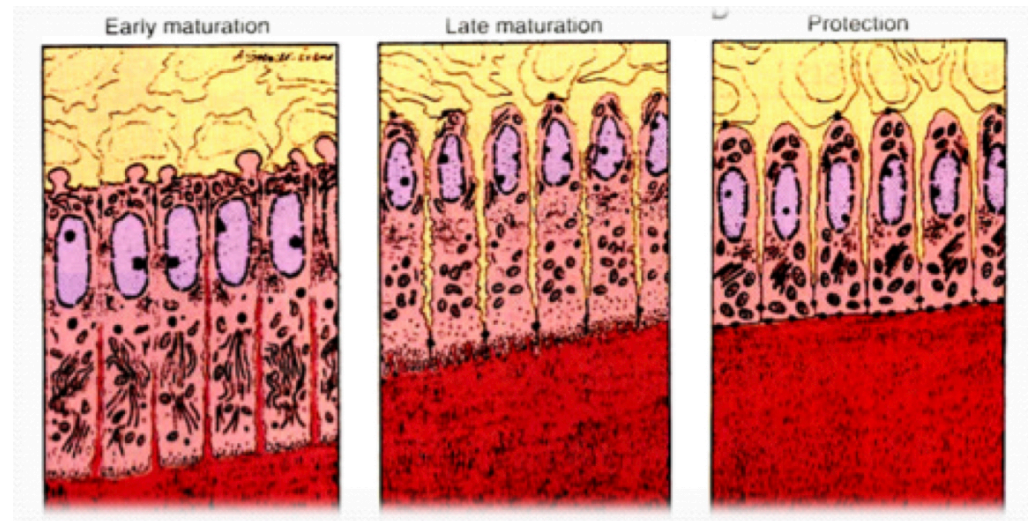
---

- What is tooth hypomineralization and what occurs during tooth development to lead to this?

# D2 Pathology:

## Tooth Hypomineralization & Causes

- Enamel Defects
  - **Hypomineralization**
  - Hypoplasia
- Clinical Observations
  - Normal enamel thickness
  - Smooth white, yellow or brown
  - Distinct border
  - Opaque
  - Incisal/cuspal third
- Pathology of Occurrence
  - Disturbance of enamel-forming ameloblasts
  - Occurs during their maturation stage
  - Leads to qualitative defect of enamel
  - Crowns don't fully form and don't mineralize properly

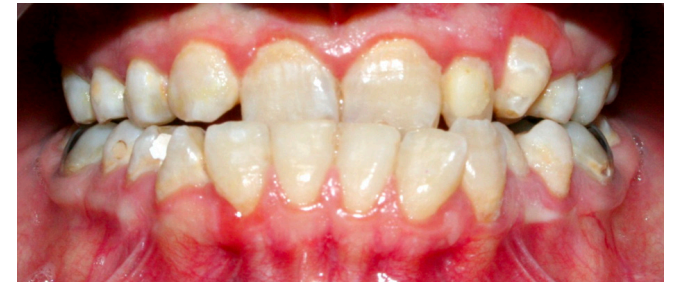

Alsaleh, Majd DDS MS, Slide 24.

# D2 Pathology:

## Tooth Hypomineralization & Causes

- What event disrupts ameloblast activity?
  - Permanent tooth enamel is fully formed in first 8 years of life – cusp tips have “oldest” enamel
  - Initial calcification begins as early as 3 mo. old
  - Systemic disturbance between birth and the first year of life that affects tooth development
    - Many MIH cases are linked to high fever at that time
- Hypomineralization & Alagille Syndrome
  - Common finding in young children with Alagille Syndrome
  - Occurs due to the high levels of hyperbilirubinemia & jaundice during odontogenesis
  - May present in primary and permanent dentition
    - Varying depending on severity of cholestasis



Berniczei-Royko , Figure 3, p. 479

# D3 Clinical Question

---

- What is the best dental treatment for young patients with hypomineralized teeth?

# D<sub>3</sub> PICO Format

---

- P: Children with Alagille Syndrome
- I: Aggressive Preventative and Dental Management
- C: Healthy Children
- O: Improved Quality of Life

# PICO Formatted Question

---

- How does aggressive preventative and dental management improve quality of life of children with Alagille Syndrome compared to healthy children?

# Clinical Bottom Line

---

- Patients with Alagille Syndrome are more likely to need liver transplants. The monitoring of oral and general health conditions and the achievement of specific protocols of prophylaxis are helpful in the prevention of complications and are fundamental to obtain the best results with liver transplantation, thus improving the quality of life of these patients.
- Dentists need to consider the specific condition of each tooth and the needs and expectations of patients when deciding how to manage hypomineralization in young patients.

# Search Background

---

- Date(s) of Search: 10/29/2020, 11/5/2020, 11/8/2020
- Database(s) Used: PubMed
- Search Strategy/Keywords: alagille, dental, children, hypomineralization dental treatments for young patients
- MESH terms used: Alagille Syndrome/therapy, Dentition, Humans, Oral Health, Organ Specificity, Pit and Fissure Sealants, Child, Crowns, Dental Enamel Hypoplasia



# Article #1

---

- Title: Medical and dental management of Alagille syndrome: A review
- Authors: Berniczei-Royko A, Chałas R, Mitura I, Nagy K, Prussak E.
- Study Design: Meta-analysis

# Article Synopsis

---

- Alagille Syndrome (AS) affects several organs and body parts; of particular interest to dentists are affects on the oral cavity:
  - May have damage to the teeth, salivary glands, periodontium, & mucous membranes; may have enamel opacities, **hypomineralization**, and hypoplasia of tooth enamel; and presence of talon cusps in primary and permanent teeth has been reported
  - Many oral/dental changes occur after liver transplantation, which is very often necessary. Graft rejection is a major complication, caused mainly by pre- or postoperative infection from a variety of sources
  - Because the oral cavity harbors numerous pathogenic bacteria, it is recommended that before surgery, all carious cavities should be treated and restored, teeth classified for the extraction should be removed, periodontium has to be healthy, and oral hygiene must be very good

# Article Synopsis

---

- The most important points are careful observation, accurate diagnosis, and planned management of such patients, especially during the patient's formative years, to prevent complications. Aggressive preventive oral care and consultations with medical specialists before any invasive procedure are obligatory. All this can improve quality of life in patients with Alagille syndrome because it allows them to receive invasive procedures, such as liver transplants and bone grafts.
- All dental treatment must be performed in collaboration with the physician, who will prescribe proper drug selection, and use of antibiotics as a prophylaxis or in a case of bleeding after extraction control of hemostasis. After surgery, all patients require regular dental control visits because of permanent and continuous immunosuppressive treatment.
- The monitoring of oral and general health conditions and the achievement of specific protocols of prophylaxis are helpful in the prevention of complications and are fundamental to obtain the best results with liver transplantation improving the quality of life of these patients. By improving the oral health of transplant recipients, the chances that the transplanted liver will become infected are much reduced, increasing the likelihood of a successful surgical outcome.

# Reason for Article Selection

---

- Meta-analysis
- Directly related to PICO question

# Article #2

---

- Title: Managing molar-incisor hypomineralization: A systematic review
- Author: Karim Elhennawy, Falk Schwendicke
- Study Design: Systematic Review of Cohort Studies

# Article Synopsis

---

- Ten trials (381 participants) investigated hypomineralized molars, and four trials (139 participants) investigated hypomineralized incisors. For molars, remineralization, restorative or extraction therapies had been assessed. For restorative approaches, mean annual failure rates were highest for fissure sealants and glass-ionomer restorations, and lowest for indirect restorations, preformed metal crowns and composite restorations. One study assessed extraction of molars in young patients (median age 8.2 years), the majority of them without malocclusions, but third molars in development. Spontaneous alignment of second molars was more frequent in the maxilla than the mandible.

# Article Screening Flow-Chart

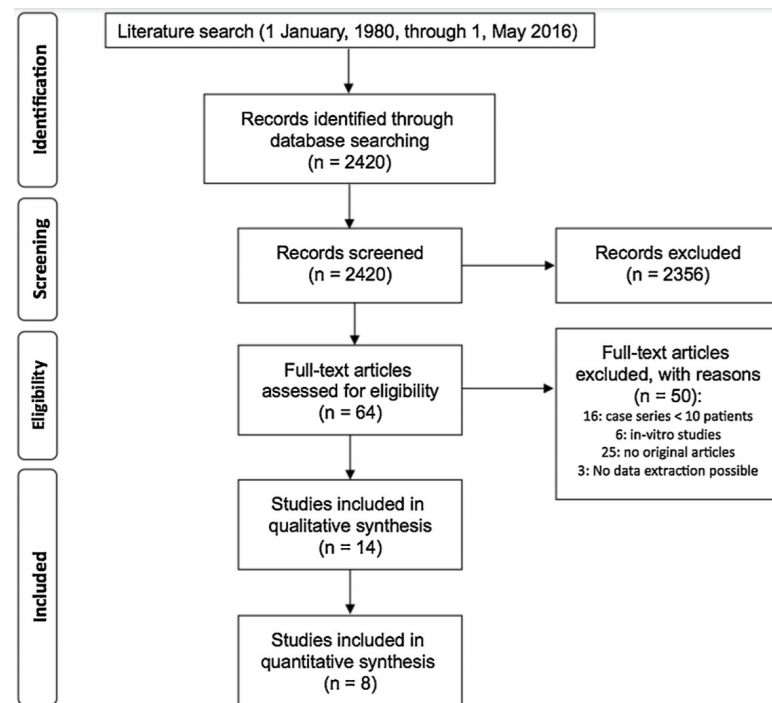


Fig. 1. Flow-chart of the study.

# Article Synopsis

---

- Molar-incisor hypomineralization (MIH) is associated with significantly increased dental treatment needs, especially in severe cases, as porous enamel and possible post-eruptive breakdown promote bacteria dentin penetration, which leads to pulpal inflammation and hypersensitivity or pain
- Remineralization or sealants seem suitable for MIH-molars with limited severity and/or hypersensitivity. For severe cases, restorations with composites or indirect restorations or preformed metal crowns seem suitable. Prior to tooth extraction as last resort factors like the presence of a general malocclusion, patients' age and the status of neighboring teeth should be considered. No recommendations can be given for MIH-incisors, aside from noting that sensitivity treatments were effective.
- Casein phosphopeptide-amorphous calcium phosphate (CPP-ACP) was shown to have a remineralizing and a desensitizing effect on MIH teeth by creating a stable super saturated solution of calcium and phosphate at the enamel surface.



# Article Synopsis

---

- 64 articles were evaluated, and of the 64 a total of 14 clinical trials were included for qualitative data, and 8 of the 14 were also included for quantitative data
- For MIH molars, 381 participants (720 molars) were treated. The mean follow-up was 3.6 years. For MIH incisors, 139 participants had been treated, with overall 274 incisors. The mean follow-up was 0.5 years.
- In mild cases, remineralization therapies are an option, and preferred over extraction. In the most severe cases, extractions are an option.
- First and foremost, hypersensitivity needs to be addressed. Remineralization with CPP-APC can be used to reduce mild or moderate hypersensitivity in MIH teeth. For more severe defects in molars, composite restorations, PMCs (preformed metal crowns) or indirect restorations can be used.
- It can be noted that amalgam restorations showed high failure rates in MIH molars. Adhesive restorations or sealants seem more suitable than amalgam, but the enamel-adhesive interface in MIH is more porous, leading to enamel cracks and decreased bond strength compared with sound enamel. Therefore, using an acetone-containing adhesive system prior to sealing increases the retention rates.
- For incisors, long-term treatment plans starting with remineralization therapy, over infiltration, and micro-abrasion. Then leading to placement of composites, veneers, or crowns.

# Reason for Article Selection

---

- Systematic Review of Cohort Studies
- Directly related to clinical question

# Levels of Evidence

---

**Levels of Evidence:** (For Therapy/Prevention, Etiology/Harm)

See <http://www.cebm.net/index.aspx?o=1025>

- ☒ **1a** – Clinical Practice Guideline, Meta-Analysis, Systematic Review of Randomized Control Trials (RCTs)
- ☐ **1b** – Individual RCT
- ☒ **2a** – Systematic Review of Cohort Studies
- ☐ **2b** – Individual Cohort Study
- ☐ **3** – Cross-sectional Studies, Ecologic Studies, “Outcomes” Research
- ☐ **4a** – Systematic Review of Case Control Studies
- ☐ **4b** – Individual Case Control Study
- ☐ **5** – Case Series, Case Reports
- ☐ **6** – Expert Opinion without explicit critical appraisal, Narrative Review
- ☐ **7** – Animal Research
- ☐ **8** – In Vitro Research

# Strength of Recommendation Taxonomy (SORT)

---

## **Strength of Recommendation Taxonomy (SORT) For Guidelines and Systematic Reviews**

See article **J Evid Base Dent Pract 2007;147-150**

- ☒ **A** – Consistent, good quality patient oriented evidence
- ☐ **B** – Inconsistent or limited quality patient oriented evidence
- ☐ **C** – Consensus, disease oriented evidence, usual practice, expert opinion, or case series for studies of diagnosis, treatment, prevention, or screening

# Conclusions

---

- For patients with AS, the monitoring of oral and general health conditions and the achievement of specific protocols of prophylaxis are important in the prevention of complications, to obtain the best results with liver transplantation, and for improving the quality of life of these patients. By improving the oral health of transplant recipients, the chances that a transplant will be affected by infection are significantly reduced, increasing the likelihood of success.
- Commonly, AS patients have hypomineralization, which needs to be treated. First, hypersensitivity needs to be addressed. Remineralization with CPP-APC can be used to reduce up to moderate hypersensitivity in MIH teeth. For more severe defects in molars and incisors, treatments may include composite restorations, PMCs, or indirect restorations.

# Conclusions: D4

---

Based on your D3's bottom line recommendations, how will you ***advise*** your patient?

- Advise patient/mother of necessary 3-month recall program.
- Prescribe fluoride mouth rinse to maintain oral health
- Advise of possible endodontic treatments once patient gets older (#14 and #30)

How will you ***help*** your patient?

- Addressed current dental needs
- Explain important of oral hygiene and taking care of teeth and completed dental work

# Discussion Questions

---

- What, if any, other dental related clinical manifestations besides hypomineralization do patients with Alagille syndrome present with?
- Are there any clinical indicators early on that can predict the future presence of hypomineralization?
- What, if any, genetic factors play a role in hypomineralization of teeth and why does it often times occur before tooth eruption?
- Are there certain demographics that are at a higher risk of developing hypomineralization of teeth?
- How prevalent is hypomineralization?
- What are the potential adverse outcomes if hypomineralized teeth are left untreated?
- What can be done, if anything, to prevent hypomineralization?
- What sorts of oral dental changes are common after liver transplant?

# Discussion Questions

---

- Are supplements available to prevent hypomineralized teeth from occurring or restore some of the lost mineral content after erupting?
- Is there a difference in treatment options for adult patients with hypomineralized teeth versus children with hypomineralization? Are the result the same?
- How is Alagille Syndrome diagnosed?
- Does hypomineralization have an effect on the dentin and cementum as well, or only the enamel?
- What causes the discoloration of teeth in patients with alagille syndrome?
- What are some of the risk factors for hypomineralization?
- How prevalent is Alagille syndrome?
- What anesthetic considerations need to be taken into account when providing restorative tx to patients with hypomineralized teeth?



# THANK YOU

---