

EVIDENCE BASED DENTISTRY

ROUNDS

PERIODONTICS

8A-1

EVAN, HANNAH, AUSTIN, THI MY LINH

ROUNDS TEAM

Group Leader: Dr. Toburen

Specialty Leader: Dr. Monfared

Project Team Leader: D4 Evan Pagano

Project team Participants: D1: Thi My Linh Nguyen, D2: Austin Davies, D3 Hannah Markquart

PATIENT

Age – 46 years old

Gender – Male

Ethnicity – African

Chief Complaint – “I want to get implants to replace my missing teeth”

Additional information – Patient came in with Nesbit Partial that had become stuck for the last 10 months.

MEDICAL HISTORY

Current and past: Non-contributory

- Diagnoses: Heart burn
- Medications: Multivitamin
- Medical consults: None
- Treatment considerations: None

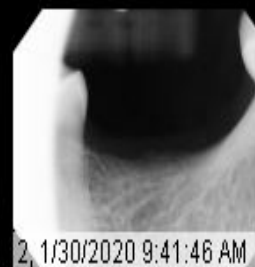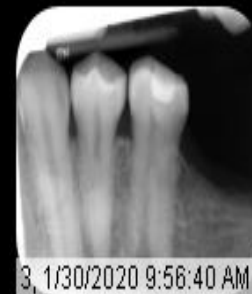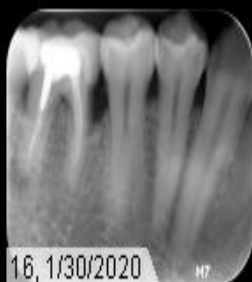
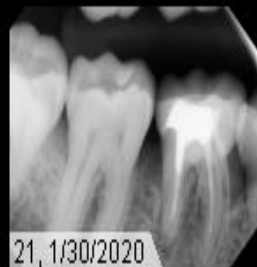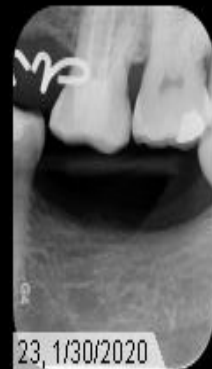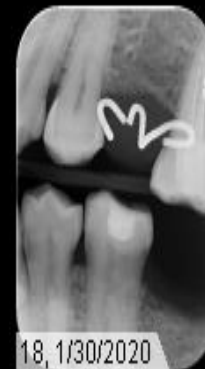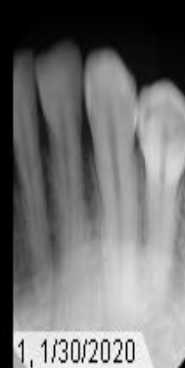
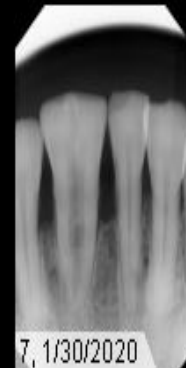
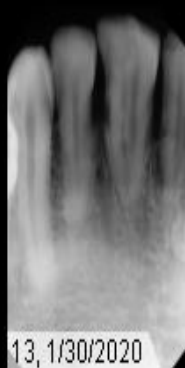
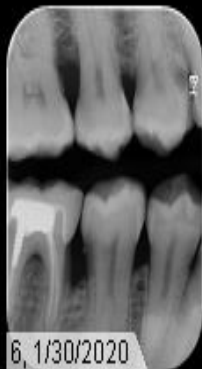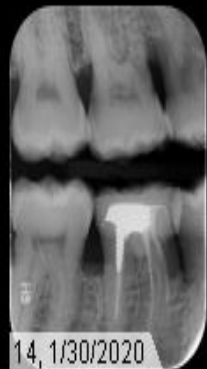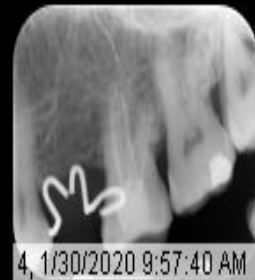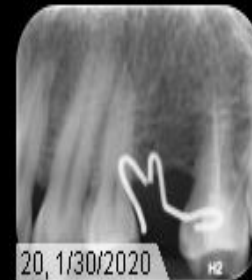
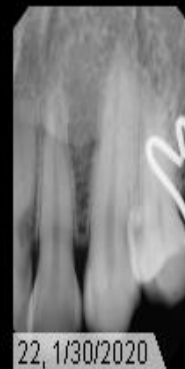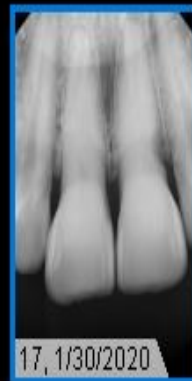
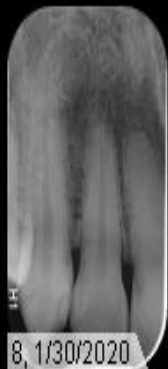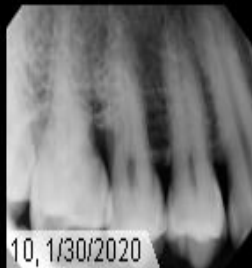
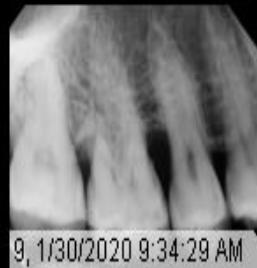DENTAL HISTORY

Patient has had a large amount of previous care done by various dentists in and throughout Africa.

Treatments: extractions, fillings, crowns, endo, nesbit partial denture.

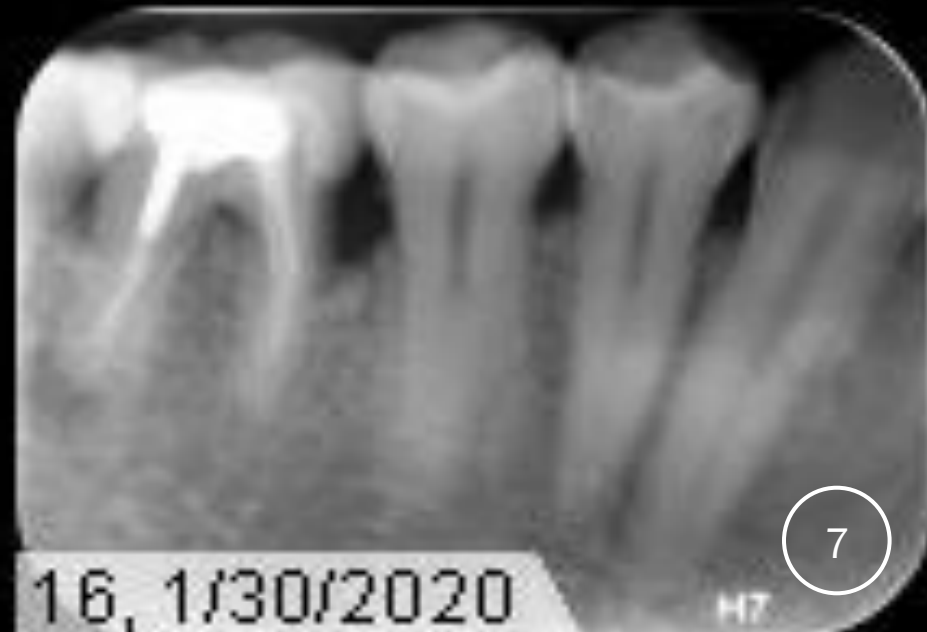
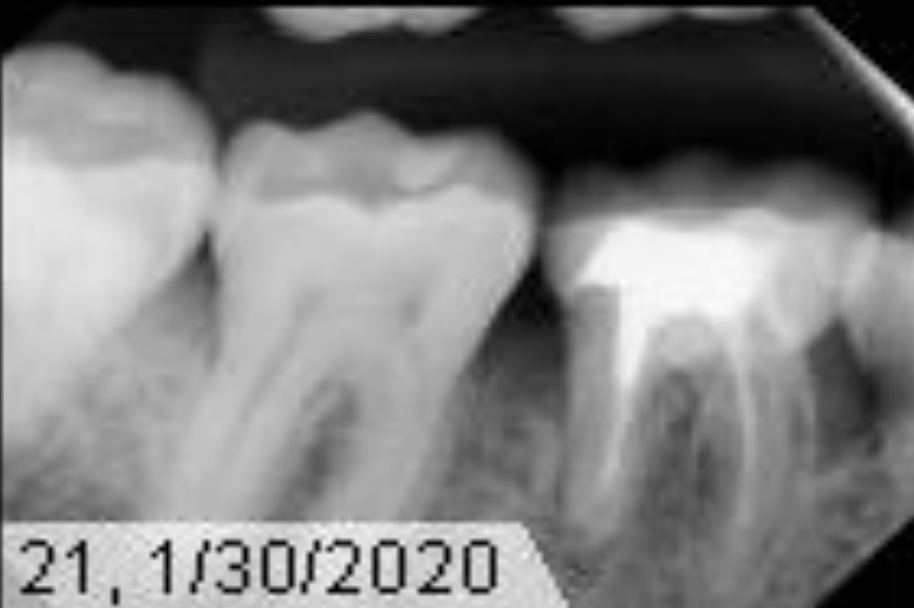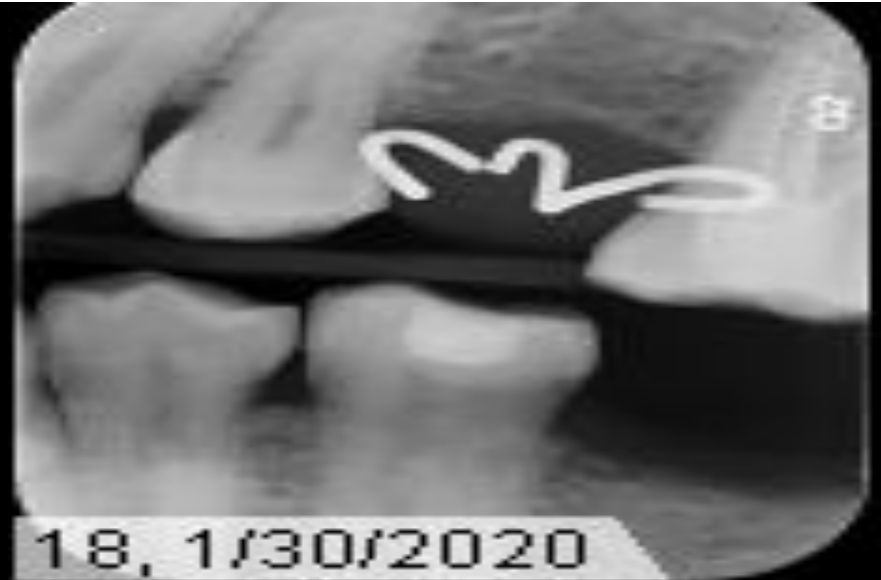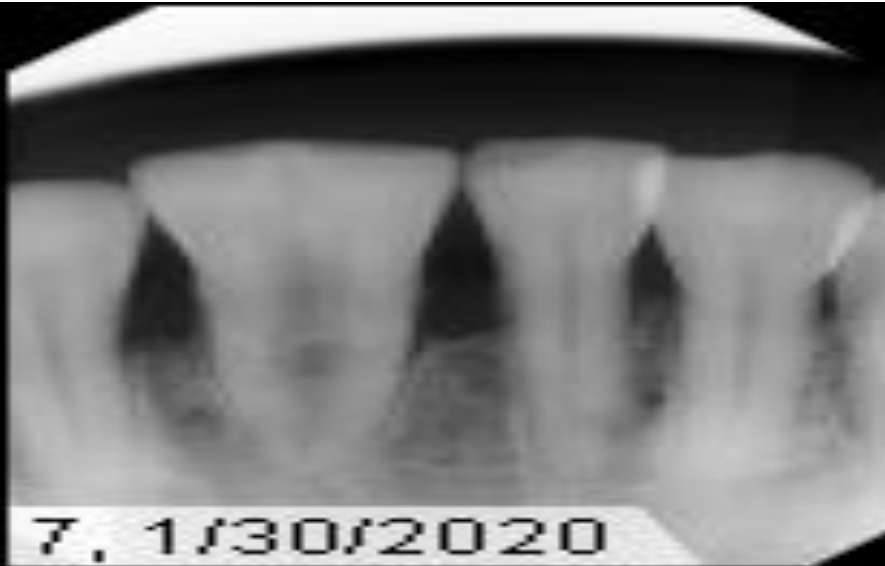RADIOGRAPHS

FMX



RADIOGRAPHS

PAS



RADIOGRAPHIC FINDINGS

- Germination
- Tori
- Periapical radiolucencies
- Endo treated teeth
- Composite restorations
- Nesbit partial denture
- Vertical bone loss
- External resorption
- Caries

CLINICAL FINDINGS

#5 D caries

#9 external resorption

#13 Tissue erythema from nesbit partial

#14 defective endo, O composite

#15 O amalgam

#20 OB composite

#23 wear facet

#24 wear facet

#25 gemination

#30 porcelain crown, Endo, Post and core, D PARL

#31 D watch

Black speckles on lateral of tongue

Bilateral mandibular tori

CLINICAL FINDINGS CONTINUED...

Functional Examination

- Bilateral class I occlusion skeletal and occlusal
- C.R/C.O – 1 mm left lateral excursion
- TMJ issues: None
- Opening: 40mm
- Left lateral: 15mm
- Right lateral: 15mm

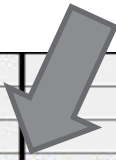
SPECIFIC FINDINGS

#13 Nesbit partial stuck between #12 and #14 for the last ten months.

#25 class II mobility on geminated tooth.

Vertical defects UR & LR

PERIODONTAL CHARTING



																	MOBILITY
																	FURCA
																	PLAQUE
	B	B	B	B					B		B		B B		B		BOP
	4 4 4	4 4 4	4 4 4	5 5 5	5 5 5	6 6 6	5 5 5	5 5 5	6 6 6	5 5 5	4 4 4		2 2 2	4 4 4	4 4 4		MGJ
	4 3 4	5 3 8	6 3 4	3 2 2	2 1 2	2 1 2	2 1 2	2 1 3	2 2 2	2 2 2	3 2 3		5 3 3	3 4 3	4 3 4		CAL
	3 2 3	4 2 6	5 2 3	3 2 2	2 1 2	2 1 2	2 1 2	2 1 3	2 1 2	2 1 2	3 2 2		2 2 2	2 3 2	3 2 3		P.D.
	1 1 1	1 1 2	1 1 1	0 0 0	0 0 0	0 0 0	0 0 0	0 0 0	0 1 0	0 1 0	0 0 1		3 1 1	1 1 1	1 1 1		FGM
1	2	3	4	5	6	7	8	9	10	11	12	13	14	15	16		
	0 0 0	0 0 0	0 0 0	0 0 0	0 0 0	0 0 0	0 0 0	0 0 0	0 0 0	0 0 0	0 0 0		0 1 1	1 1 1	1 1 1		FGM
	3 2 3	3 2 6	5 1 3	3 1 2	2 1 2	2 1 2	2 1 3	2 1 2	2 2 2	2 2 2	2 1 2		3 2 2	2 2 3	5 3 3		P.D.
	3 2 3	3 2 6	5 1 3	3 1 2	2 1 2	2 1 2	2 1 3	2 1 2	2 2 2	2 2 2	2 1 2		3 3 3	3 3 4	6 4 4		CAL
																	MGJ
		B	B		B						B		B B	B B	B		BOP
																	PLAQUE
																	FURCA
																	PROGNOSI

		2															PROGNOSI
																	FURCA
																	PLAQUE
	B	B			B		B B	B B	B			B B					BOP
5 5 5	5 5 5	5 5 5	5 5 5	4 4 4	4 4 4	4 4 4	4 4 4	4 4 4	4 4 4	5 5 5	4 4 4	4 4 4			4 4 4		MGJ
4 3 3	6 4 4	4 3 4	3 1 2	2 1 2	2 1 1	1 1 1	5 5 5	4 3 3	2 2 2	2 2 3	2 3 2	2 2 3			3 3 3		CAL
3 2 2	5 3 3	3 2 3	2 1 2	2 1 2	2 1 1	1 1 1	1 1 1	2 1 2	2 1 2	2 1 3	2 2 2	2 2 2			2 2 2		P.D.
1 1 1	1 1 1	1 1 1	1 0 0	0 0 0	0 0 0	0 0 0	4 4 4	2 2 1	0 1 0	0 1 0	0 1 0	0 0 1			1 1 1		FGM
32	31	30	29	28	27	26	25	24	23	22	21	20	19	18	17		
1 1 1	1 1 1	1 1 1	1 1 1	0 1 0	0 0 0	1 1 1	4 4 4	1 2 1	0 0 0	0 0 0	0 0 0	0 0 0			1 1 1		FGM
2 2 3	3 2 2	5 3 6	5 1 3	2 1 2	2 1 2	2 1 2	1 1 2	2 1 2	2 1 2	2 1 3	2 1 3	2 2 3			3 2 2		P.D.
3 3 4	4 3 3	6 4 7	6 2 4	2 2 2	2 1 2	3 2 3	5 5 6	3 3 3	2 1 2	2 1 3	2 1 3	2 2 3			4 3 3		CAL
4 4 4	4 4 4	4 4 4	5 5 5	5 5 5	5 5 5	3 3 3	1 1 1	4 4 4	4 4 4	5 5 5	4 4 4	4 4 4			4 4 4		MGJ
B	B	B	B		B		B B	B B B	B	B		B					BOP
																	PLAQUE
																	FURCA



DIAGNOSIS

Moderate chronic periodontitis

PROBLEM LIST

- Periodontitis
- Caries
- Missing teeth
- External resorption
- Apical radiolucencies
- Mobility
- Dental hygiene

GEMINATION:

Development anomaly of hard tissue

A large single tooth with a bifid crown

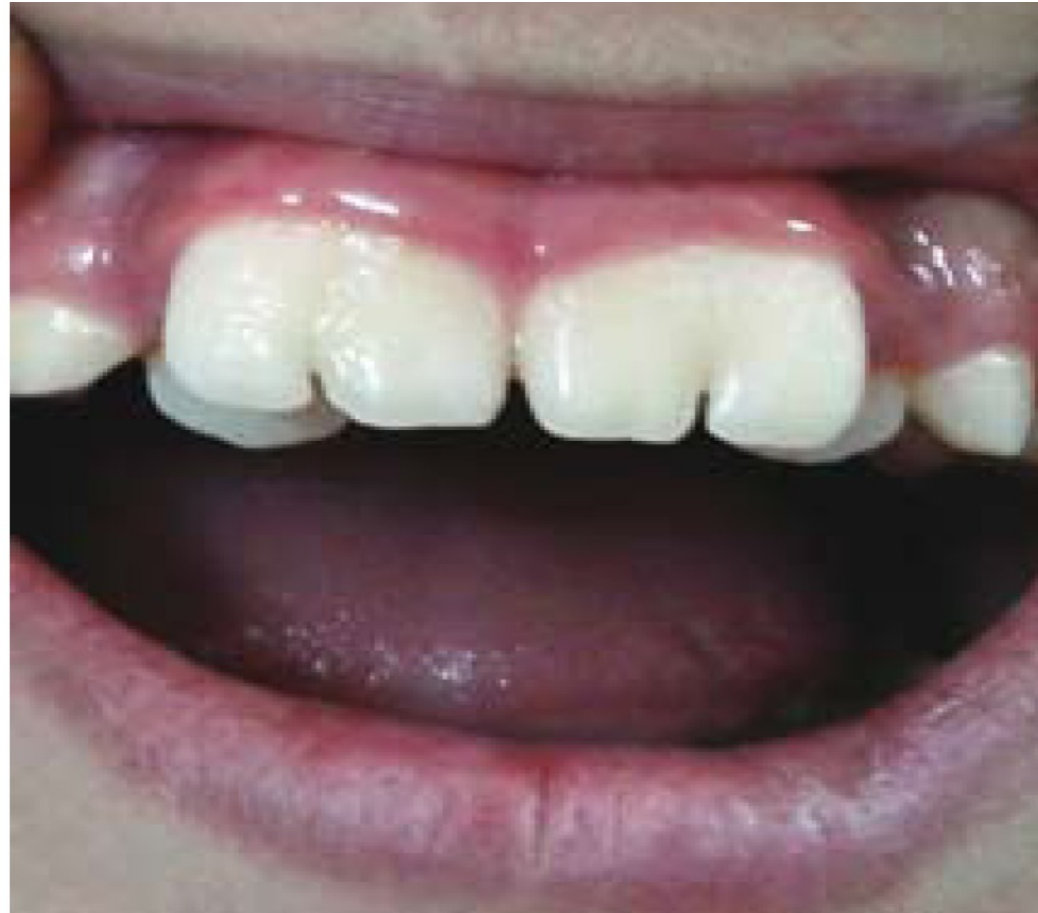- Either complete or incomplete separation of crown

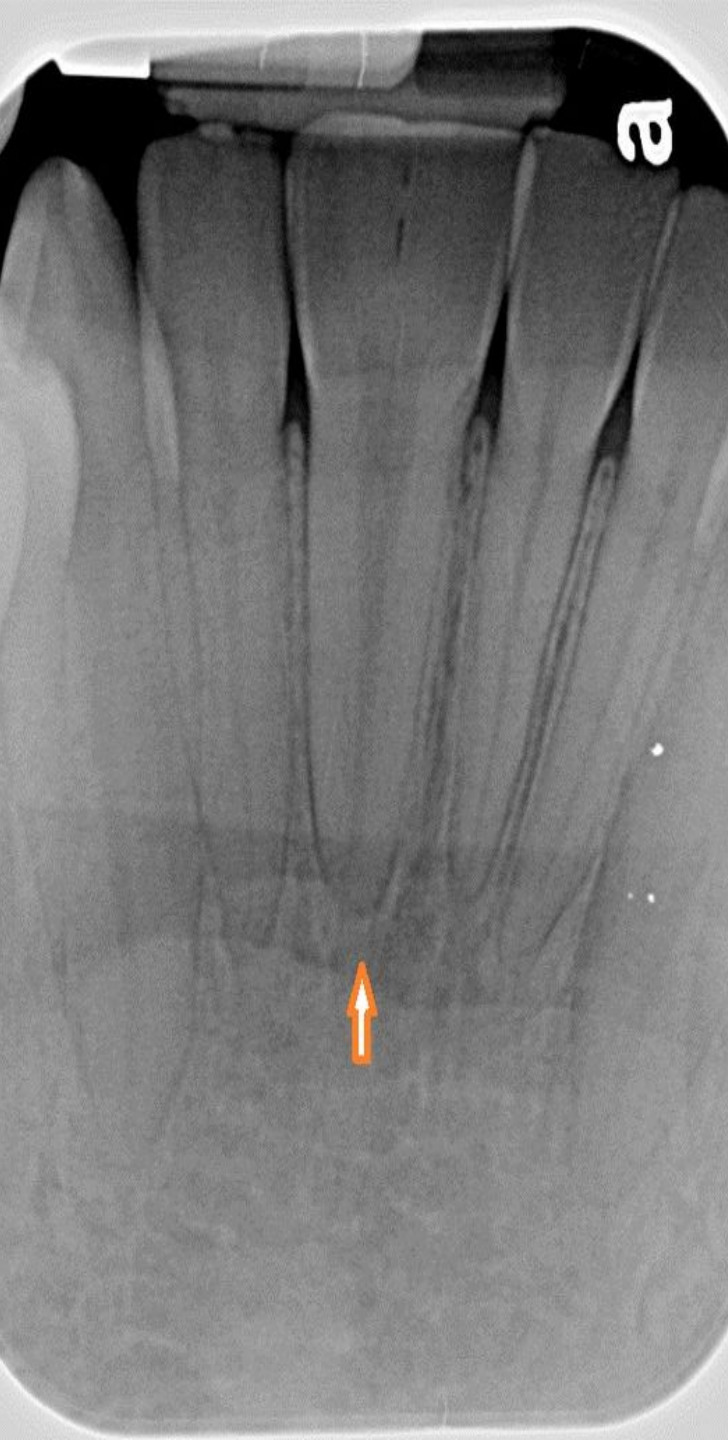One single root and root canal

Normal number of teeth in the dentition

- As oppose to reduced number of teeth in cases with Fusion

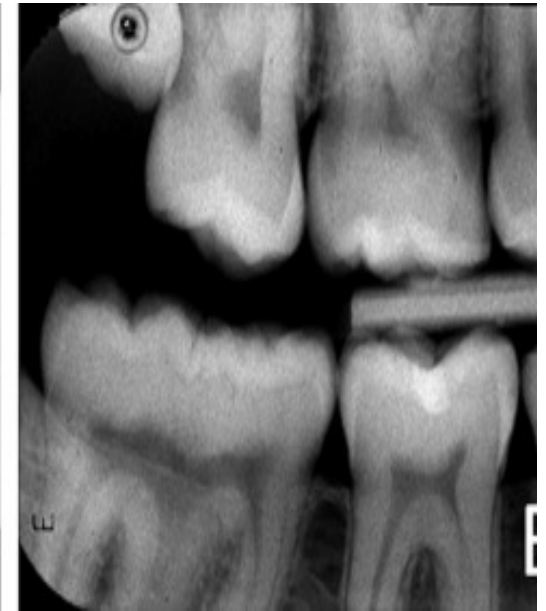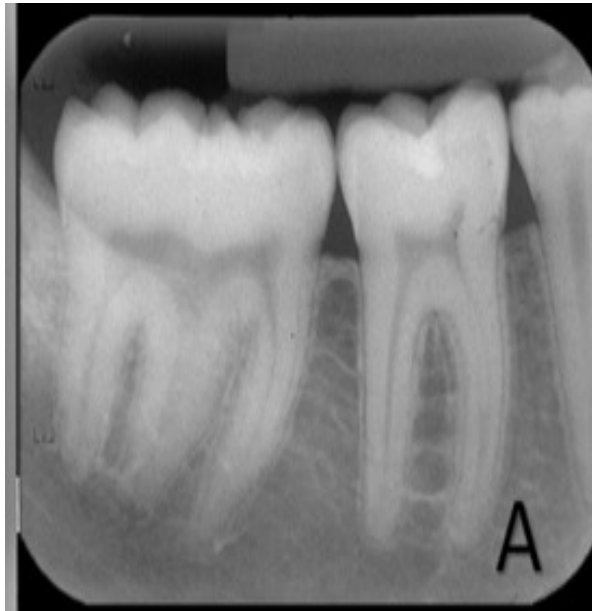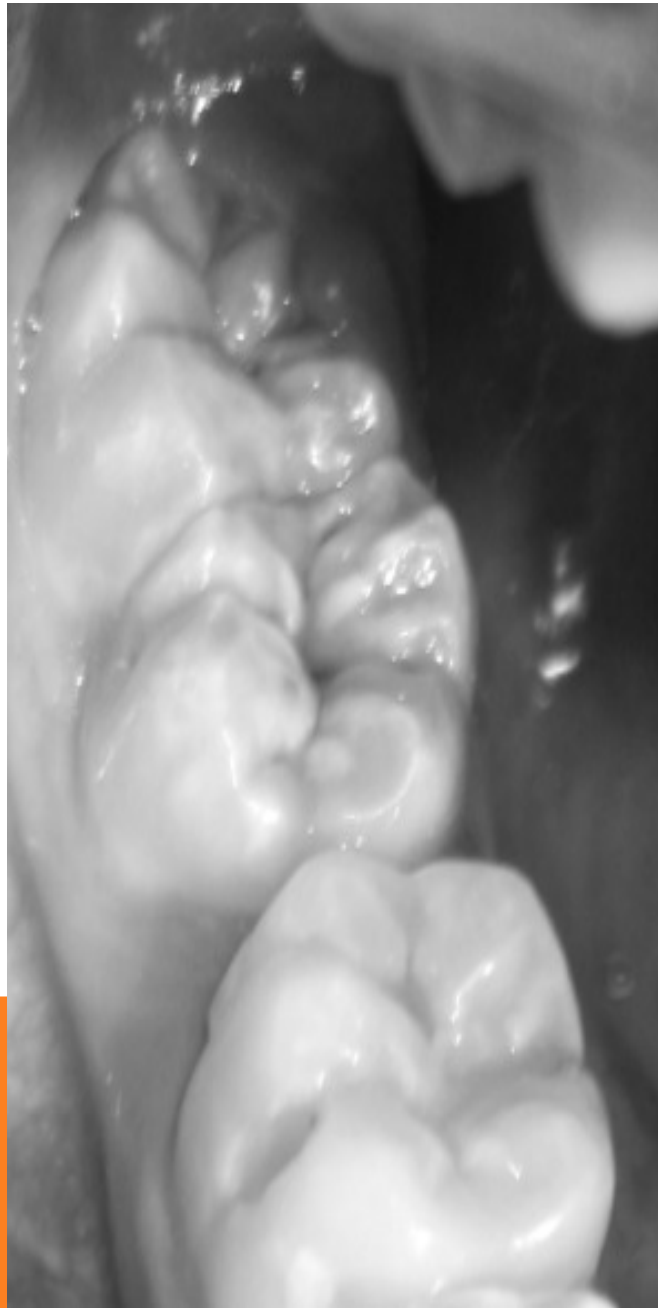
Figure: Clinical view of bilateral permanent maxillary central incisors with deep notches





D2 – WHAT IS THE PATHOLOGY OF GEMINATION AND WHERE IS IT SEEN?

- Double Tooth category of abnormality
- 'Cap' stage of the proliferative phase in tooth development
- Invagination attempting to split
- Anterior teeth
- Deciduous teeth > Permanent teeth
- 2.5% of deciduous teeth, 0.2% of primary dentition
- In one study by Brooke et al. 50% of teeth deciduous affected by double tooth abnormality will have a similar presentation in their permanent dentition



CLINICAL PHOTOS – MANDIBULAR SECOND MOLAR GEMINATION

D3 PICO

Clinical Question:

- How does the endodontic status of a tooth affect periodontal regeneration?

PICO FORMAT

P: Patients with previously treated teeth needing periodontal regenerative surgery

I: Endodontically treated teeth

C: Non-endodontically treated teeth

O: Improved probing depths and clinical attachment loss

PICO FORMATTED QUESTION

In patients with previously treated teeth does endo affect the outcome of periodontal regenerative surgery when compared to non-endodontically treated teeth when looking at probing depths and clinical attachment loss?

CLINICAL BOTTOM LINE

- There does not seem to be any statistically significant evidence that RCT treatment has an impact on the success of periodontal regenerative surgery.
- There does seem to be some statistically significant evidence that periodontal regenerative surgery can improve the success of root canal treated teeth.
- Periodontal regeneration techniques can improve the prognosis of hopeless teeth and provide another treatment option for clinicians, rather than just extracting the tooth.

SEARCH BACKGROUND

Date(s) of Search: 11/08/2020, 11/14/2020

Database(s) Used: PubMed

Search Strategy/Keywords:

- Periodontal disease, vertical defects, periodontal regeneration, root canal therapy, clinical attachment loss, probing depths

SEARCH BACKGROUND

MESH terms used:

Guided periodontal tissue regeneration

Periodontal surgery

Root Canal Therapy

Tooth, Nonvital

Periodontal Attachment Loss

Periodontal Pocket

ARTICLE 1 CITATION, INTRODUCTION

Citation:

- De Sanctis, M. Goracci, C. Zucchelli, G. Long-term effect on tooth vitality on regeneration therapy in deep periodontal bony defects: a retrospective study. Int J Periodontics Restorative Dent 2013;33:151–157. doi: 10.11607/prd.1461

Study Design: Retrospective Study

Study Need / Purpose:

- Evaluated if “aggressive” periodontal therapy can impact the vitality of a tooth.

ARTICLE 1 SYNOPSIS

Method

- 137 patients total. 54 treated 1992-97, 48 treated 1997-2000, and 35 treated 2000-2003.
- All patients were recalled in 2010 to evaluate pocket depths, recession, and CAL. A PA radiograph and vitality testing were also taken.
- One-way analysis of variance (ANOVA) and chi-square analysis evaluated statistical significances among techniques and clinical parameters (PD, recession, CAL).
- A Fisher exact test was also performed for evaluation of significance of loss of tooth vitality in relation to treatment.

Results

- “Aggressive periodontal surgery” does not pose a significant risk to the vitality of a tooth
- Enamel Matrix Derivative (EMD) was the technique with the most CAL gain (5.36 +/- 0.7 mm), while guided tissue regeneration (GTR) had the least (4.90 +/- 1.0 mm)

Conclusions – Performing RCT before “aggressive periodontal surgery” is not advised if there are not any other indications for RCT present

Limitations

- small sample size
- results cannot be generalized and applied to all perio therapies

ARTICLE 1 SELECTION

☐ Reason for selection

- Evaluated a number of periodontal therapies and their affect on tooth vitality 7-18 years post-treatment. There was no statistically significant evidence that “aggressive perio treatment” would cause loss of tooth vitality.

☐ Applicability to your patient

- Patient already has a root canal done on the tooth needing regenerative perio therapy

☐ Implications

- Aggressive perio surgery does not affect the vitality of a tooth

ARTICLE 2 CITATION, INTRODUCTION

Citation:

- Tsesis I, Rosen E, Tamse A, Taschieri S, Del Fabbro M. Effect of guided tissue regeneration on the outcome of surgical endodontic treatment: a systematic review and meta-analysis. J Endod. 2011 Aug;37(8):1039-45. doi: 10.1016/j.joen.2011.05.016. PMID: 21763891.

Study Design: Systematic review and meta-analysis

Study Need / Purpose: Evaluate if there is a statistically significant effect of GTR on endodontically treated teeth

ARTICLE 2 SYNOPSIS

Method

- Found studies that fit the inclusion and exclusion criteria
 - 191 articles initially eligible based on title and abstracts
 - Only 5 met the inclusion and exclusion criteria.
- Radiographic and clinical evidence was evaluated
- Statistical analysis performed using both tooth and patient as analysis unit
- Meta-analysis performed with Mantel-Haenszel method
- Forest plots graphed difference in outcomes for treatment groups
- Fisher exact test evaluated effect of the variables (lesion size, lesion type, etc.) on the outcomes.

Results

- Favorable outcomes for:
 - GTR > no GTR
 - Through and through lesions > 4-wall defects
 - Small periapical lesions > large lesions
 - Resorbable membrane > non-resorbable membrane > no membrane used at all
- However, results were not statistically significant

Conclusions

- GTR *could help* improve the outcome of bone regeneration after endo surgery, but the evidence isn't statistically strong enough to support it. More data is needed.

Limitations

- Not many studies fit the inclusion and exclusion criteria to be evaluated, limited data

ARTICLE 2 SELECTION

Reason for selection

- Compared the use of GTR when endodontically treating a tooth and lesion vs no GTR.

Applicability to your patient

- RCT retreatment is an option for this patient and combining it with GTR could be favorable. Although the evidence was not statistically significant, there were still better outcomes when GTR was done to help heal the lesions and defects in question.

Implications

- This study only looked at teeth that had not been previously endodontically treated.

ARTICLE 3 CITATION, INTRODUCTION

Citation:

- Cortellini P, Stalpers G, Mollo A, Tonetti MS. Periodontal regeneration versus extraction and prosthetic replacement of teeth severely compromised by attachment loss to the apex: 5-year results of an ongoing randomized clinical trial. J Clin Periodontol. 2011 Oct;38(10):915-24. doi: 10.1111/j.1600-051X.2011.01768.x. Epub 2011 Jul 21. PMID: 21777268.

Study Design: Randomized clinical trial

Study Need / Purpose: Evaluated periodontal regeneration in both vital and non-vital teeth. Looked at 1 and 5-year survival. 92% successful when compared to control group (EXT of hopeless teeth and replaced by fixed prosthesis)

ARTICLE 3 SYNOPSIS

Method

- 50 patients with generalized severe periodontitis and at least one hopeless tooth
- Control group – extract hopeless tooth & replace with fixed prosthesis
- Test group – underwent regenerative therapy

Results

- 100% of the control group had successful treatment outcomes at the 1 and 5-year recall appts
- 92% (23/25) of the test group demonstrated critical clinical improvements (CAL, PD, radiographic bone gain, tooth mobility) at the 1 and 5-year recall appts
 - Only 2 teeth failed and were extracted at the 1-year recall appt.

Conclusions

- Extraction does not have to be the only treatment option for a hopeless tooth.
- Regenerative therapy can even be an option for severely compromised teeth with intra-bony defects to or beyond the root apex.

Limitations

- Small sample size

ARTICLE 3 SELECTION

Reason for selection

- Most relevant article to our clinical and PICO questions. It assesses the success of periodontal regeneration in both vital and non-vital teeth.

Applicability to your patient

- The patient's tooth in question is already endo-treated and needs periodontal regenerative surgery. In theory, this patient could have qualified to be part of the study, so it is very applicable to this patient.

Implications

- Small sample size

LEVELS OF EVIDENCE

- ☒ **1a** – Clinical Practice Guideline, Meta-Analysis, Systematic Review of Randomized Control Trials (RCTs)
- ☒ **1b** – Individual RCT
- ☐ **2a** – Systematic Review of Cohort Studies
- ☒ **2b** – Individual Cohort Study
- ☐ **3** – Cross-sectional Studies, Ecologic Studies, “Outcomes” Research
- ☐ **4a** – Systematic Review of Case Control Studies
- ☐ **4b** – Individual Case Control Study
- ☐ **5** – Case Series, Case Reports
- ☐ **6** – Expert Opinion without explicit critical appraisal, Narrative Review
- ☐ **7** – Animal Research
- ☐ **8** – In Vitro Research

STRENGTH OF RECOMMENDATION TAXONOMY (SORT)

<input checked="" type="checkbox"/>	A – Consistent, good quality patient oriented evidence
<input type="checkbox"/>	B – Inconsistent or limited quality patient oriented evidence
<input type="checkbox"/>	C – Consensus, disease oriented evidence, usual practice, expert opinion, or case series for studies of diagnosis, treatment, prevention, or screening

CONCLUSIONS: D3

How does the evidence apply to this patient?

- The patient has a tooth with a questionable prognosis.
- It is already endo treated and still has a PARL with a vertical bony defect on the distal.
- All 3 articles are in favor of at least attempting perio surgery.
 - Regenerative therapy can only help, not hurt the tooth in question
 - If needing endo-retreatment, the perio regeneration could also benefit the healing of the PARL
 - CAL, PD, radiographic defects, and tooth mobility all improved in the 3rd study. All of which would benefit our patient.

Based on the above considerations, how will you advise your D4?

I would advise the D4 to present this material to the patient and let them decide how they would like to move forward. The periodontal regeneration therapies have a great success rate according to the 3rd article and so if the patient is willing and motivated to keep their tooth, then they should attempt this treatment.

CONCLUSIONS: D4

Consulted with both endo and perio specialties, CBCT of tooth was taken and endo wishes to observe radiolucency prior to endo retreatment due to the size of lesion and the amount of previous restorative work done on the tooth. Will recommend a perio consult to the patient to eventually expose and assess the vertical defect for the possibility of periodontal regenerative surgery compared to extraction of the tooth. If the patient wishes to try to save the tooth I would recommend GTR of the area and continue to monitor the periapical radiolucency

DISCUSSION QUESTIONS

THANK YOU